

VIDEOENDOSCOPIC SURGERY FOR THE TREATMENT OF ESOPHAGUS' LEIOMYOMA

Tratamento videoendoscópico do leiomioma de esôfago

Fernando Antonio Siqueira **PINHEIRO**, Antonio Borges **CAMPOS**,
Juliana Regia Furtado **MATOS**, Daniel Pereira de Alencar **ARARIPE**

From the General and Digestive Surgery Services, University Hospital Walter Cantídio – HUWC, School of Medicine, Federal University of Ceará, Fortaleza, CE, Brazil.

ABSTRACT - Introduction: Leiomyomas are the commonest benign esophageal neoplasms. Surgical treatment is the therapy of choice for such tumors. Open enucleation via thoracotomy has long been the standard procedure. With the emergence of thoracoscopic and laparoscopic approaches, minimally invasive surgery represent interesting alternatives to open surgical procedures. **Aim:** To propose endoscopic technique for the treatment of these myomas avoiding thoracotomy. **Technique:** Enucleation of leiomyoma by: A) thoracoscopy, for thoracic esophageal tumors, or B) laparoscopy to the ones located in abdominal esophagus. A) The operations are performed under general anesthesia with selective intubation of the left lung. Patients are placed in the left lateral decubitus position and mild dorsiflexion. Four work trocars are used, two of 11 mm and two of 5 mm. One of the 11 mm is put in the 6th intercostal space in the posterior axillary line to use the 30° endoscope; another, at the same hemi-clavicular line, to take the lung away off surgical site. Other two trocars of 5 mm are installed for working tools of the surgeon, one in the 4th space in the posterior axillary line, and another in the 7th, also in the posterior axillary line. Operations are always initiated by opening the mediastinal pleura, dissection of the tumor with opening the muscle of the esophageal wall, simple enucleation of the tumor and closure of esophageal parietal muscular layer. B) The interventions are done with patients undergoing general anesthesia and placed in the French position. The approach is the same performed to correct the hiatal hernia, and enucleation is done without difficulty. **Conclusion:** Videosurgery for leiomyomas resection is safe and feasible and provides results similar to open procedure, but with a significant reduction in morbidity.

HEADINGS - Surgical procedures. Minimally invasive surgery. Esophageal Neoplasms. Laparoscopy. Thoracoscopy.

Correspondence:

Fernando Antonio Siqueira Pinheiro
E-mail: fsiqueirapinheiro@hotmail.com

Financial source: none
Conflicts of interest: none

Received for publication: 25/02/2013
Accepted for publication: 20/06/2013

DESCRITORES - Procedimentos cirurgicos. Cirurgia minimamente invasiva. Neoplasias Esofágicas. Laparoscopia. Toracoscopia.

RESUMO - Introdução: Leiomiomas são as neoplasias esofagianas mais comuns. Seu tratamento de escolha é cirúrgico. A enucleação por toracotomia aberta é o procedimento padrão. Com o avanço das técnicas de cirurgia minimamente invasiva, novas alternativas se impõem. **Objetivo:** Apresentar técnica videoendoscópica para o tratamento desses miomas evitando-se toracotomia. **Técnica:** Enucleação do leiomioma por: A) toracoscopia para tumores do esôfago torácico ou B) laparoscopia aos do esôfago abdominal. A) As operações são realizadas sob anestesia geral com entubação seletiva do pulmão esquerdo. Os pacientes são colocados em posição de decúbito lateral esquerdo e leve dorsoflexão. São utilizados quatro trocarêres de trabalho, dois de 11 mm e dois de 5 mm. Os de 11 mm, um no 6° espaço intercostal, na linha axilar posterior, para ótica de 30°; outro na mesma altura na linha hemi-clavicular para afastar o pulmão. Os outros dois trocarêres de 5 mm são instalados para dar passagem aos instrumentos de trabalho do cirurgião no 4° espaço, na linha axilar posterior, e no 7°, também na linha axilar posterior. As operações se iniciavam sempre pela abertura da pleura mediastinal, dissecação do tumor com abertura da parte muscular da parede esofágica, enucleação simples do tumor e fechamento da incisão muscular esofágica. B) As intervenções são feitas com os pacientes submetidos à anestesia geral e colocados em posição francesa. A abordagem é a mesma realizada para correção da hérnia hiatal e a enucleação é feita sem dificuldades. **Conclusão:** O acesso videocirúrgico é perfeitamente exequível para as ressecções de leiomiomas esofágicos e proporciona resultados satisfatórios muito semelhantes aos encontrados com aos procedimentos abertos.

INTRODUCTION

Benign tumors of the esophagus are relatively rare lesions compared with carcinomas. They are the commonest benign neoplasms with an overall incidence of 1:1000 habitants. The male-to-female ratio

is approximately 2:1, with peak incidence in the third to fourth decades of life. They are most frequently found in the lower (56%) and middle thirds (33%) of the esophagus. Lesions are uncommon in the upper third (11%). Approximately 97% of esophageal leiomyomas arise as intramural growths and 3% are presented as polyps^{10,15,16}.

At least 50% of patients with esophageal leiomyoma remain asymptomatic. The most common presenting symptom is dysphagia and can be associated with chest pain, retrosternal discomfort, pyrosis and weight loss. Barium esophagogram usually can provide the diagnosis in the majority of patients. Upper gastrointestinal endoscopy, endoscopic ultrasound and computed tomography are diagnostic modalities in determining the location of the tumor and the anatomic relationship of the lesion to other organs. The endoscopic biopsy specimens are non-diagnostic because they may give a high false negative rate. In cases of suspected leiomyoma, endoscopic biopsy is contraindicated, because this procedure increases the incidence of intraoperative mucosal tear^{10, 15}.

Surgical treatment is the therapy of choice. Although surgery can be delayed if asymptomatic patients have benign characteristic in radiographic appearance. Indications for surgical removal include uncertain diagnosis, large size and symptomatic lesions and impossibility of adequate follow-up¹. Open enucleation via right or left thoracotomy has long been the standard procedure, depending on the location of the tumor. With the emergence of thoracoscopic and laparoscopic approaches, minimally invasive surgery represent interesting alternatives to open surgical procedures^{2,11,12,14,17}.

The objective of this paper is to present a technique for endoscopic treatment of esophageal leiomyomas.

TECHNIC

The enucleation of leiomyoma can be done by:
A) thoracoscopy, for thoracic esophageal tumors, or
B) laparoscopy, for tumors of abdominal esophagus.

Thoracoscopy for thoracic esophageal tumors

The operations are performed under general anesthesia with selective intubation of the left lung. The surgical team must be composed of a surgeon, two assistants and instrumentation. Patients are placed in the left lateral decubitus position and mild dorsiflexion (Figure 1). Four trocars are used, two of 11 mm and two of 5 mm. One of 11 mm is placed in the 6th intercostal space in the posterior axillary line for 30° endoscope; another, at the same hemi-clavicular line, to take the lung away off surgical site (2nd assistant). Other two trocars of 5 mm are installed for working tools of the surgeon, one in the 4th space in the posterior axillary line, and another in the 7th, also

in the posterior axillary line (Figure 2). Operations are always initiated by opening the mediastinal pleura, dissection of the tumor with opening the muscle of the esophageal wall, simple enucleation of the tumor and closure of esophageal parietal muscular layer. After tumor resection muscular layer is sutured with separate stitches using 3.0 absorbable suture. The tumors are removed in a glove finger through the second trocar of 11 mm. After the procedure, a chest tube is left routine and removed after 24 hours.

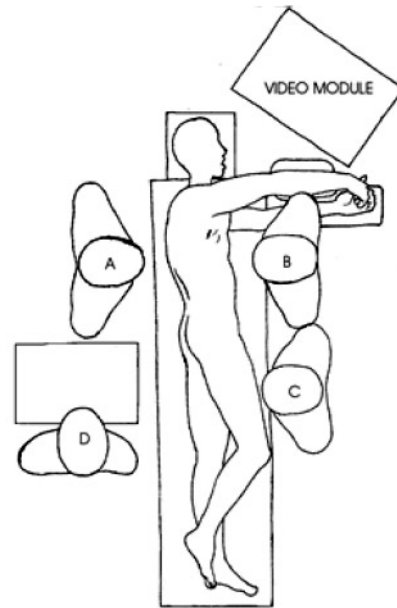


FIGURE 1 – Position of the surgical team and the patient in the thoracoscopic approach: A) surgeon; B) 1st assistant; C) 2nd assistant; D) instrumentator

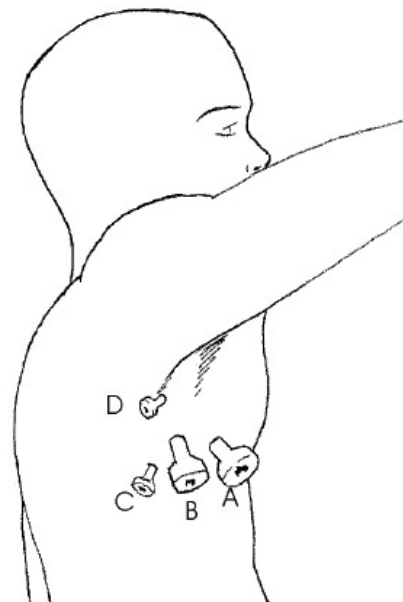


FIGURE 2 – Arrangement of trocars in thoracoscopic approach: A and B trocars 11 mm; C and D 5 mm trocars

Laparoscopy to tumors of the abdominal esophagus

Interventions are made with patients undergoing general anesthesia and placed in French position (legs apart, slightly bent, inclined 15° and discreet left lateral). The surgical team composition and positioning of each member are shown in Figure 3. After pneumoperitoneum, performed by supraumbilical puncturing with Verres needle up to 12 mmHg, the surgical procedure is initiated with the introduction of trocars (Figure 3) and approach the esophageal hiatus. The enucleation is performed without much technical difficulty; after the tumor removal, the muscle layer is sutured similarly to the thoracoscopic approach and the specimen is also removed in a glove finger.

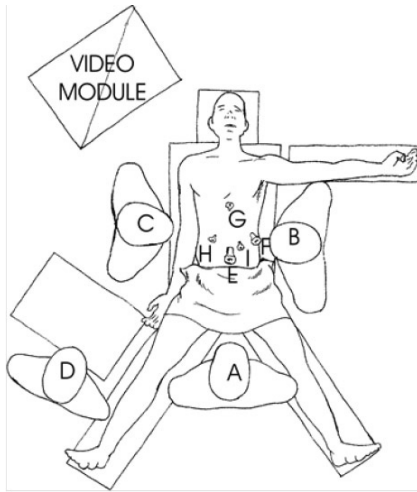


FIGURE 3 - Surgical team and disposal of trocars in transhiatal laparoscopic: A - surgeon, B - 1st assistant, C - 2nd assistant, D - instrumentator, E and F - trocar 11 mm, G, H and I - trocars of 5 mm

In both approaches, no special postoperative care is needed. Patients are fed back into the first day after surgery and are discharged within 48 hours.

RESULTS

Four patients, two men and two women, mean age 41.5 years, underwent resection of esophageal leiomyomas. Two patients were operated through right thoracoscopic approach and other two by laparoscopy.

From the clinical point of view, the main complaint was dysphagia, which was present in all cases. All underwent preoperative evaluation as a barium swallow and esophagogastroduodenoscopy. Radiological findings in contrasted esophageal exam, showed the lunated classic image subtraction aspect, two located in the middle segment (Figure 4) and two in the abdominal esophagus, near the cardia. Endoscopic findings were always tumors that partially obstructed the esophageal lumen, intramural aspect, circumscribed, without compromising the mucosa (Figure 5). In neither case was made attempts to take biopsies.

The mean operative time of the procedure was 90

minutes. In one of the cases by thoracotomy, to improve access to the tumor, it was necessary to make the ligation of the azygos vein, which was made using clips and ligation with cotton thread (Figure 6). Except for a perforation of the mucosa, no other event has been identified. The postoperative course was good and uneventful. Patients were hospitalized for two to five days, with an average hospital stay of three days. All had good follow-up with complete regression of symptoms after the operation. In one patient a small area with diverticulum appearance at the site of tumor resection, without associated symptoms, was found, but with no need of complementary treatment. Histological analysis of the resected tumors confirmed the presence of leiomyoma in all cases.

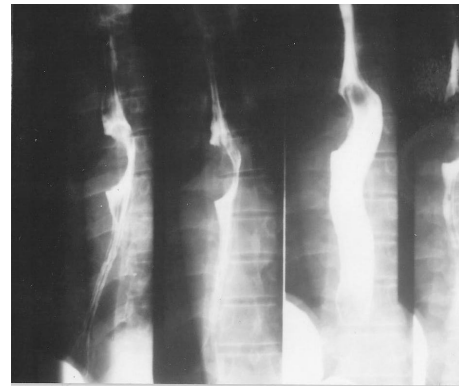


FIGURE 4 - Contrast esophagogram showing the classic semilunar filling defect

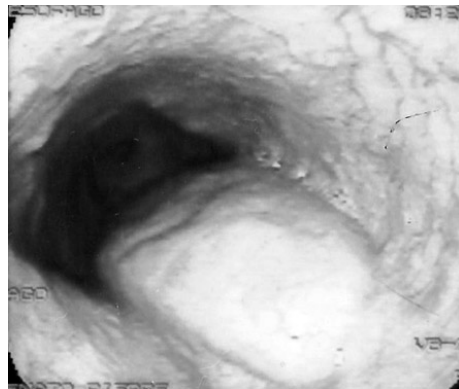


FIGURE 5 - Endoscopic appearance of leiomyoma: extrinsic protrusion without involvement of the mucosa

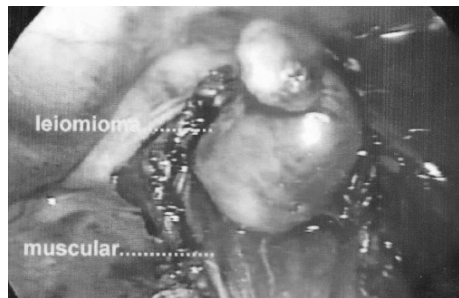


FIGURE 6 - Thoracoscopic vision of leiomyoma of the esophagus

DISCUSSION

The treatment of esophageal leiomyoma was always surgical. Although in some cases, conservative approach may be adopted with endoscopic follow-up during long time, this is not the rule used on patients with this type of tumor^{10,15}. A possible malignant transformation and the inability to follow-up these patients have been the subject of strengthening the surgical indication^{6,13}. Besides, all those benefits already well known to the laparoscopic approach - greater postoperative comfort, less pain, better cosmetic results and rapid return to normal activities - come to consolidate this therapeutic modality^{4,7,8,9,11,12,14}. All these advantages have greater implication as to reduce morbidity and mortality. The formation of an esophageal diverticulum in one case alert for mandatory approach of the muscular layer, as a way to prevent it. The risk of esophageal mucosal injury is approximately 10%¹⁶, which requires attention, since in these cases there is a great chance to convert the procedure to open operation. Were used four trocars in thoracoscopic approach, which differs from some authors that recommend the use of five work channels^{1,5,6}. It is noteworthy that the initial use of four should always be attempted. If any surgical difficulty appears, it can be used one more, the fifth. New therapeutic options are coming with the aid of robotic assisted procedures and endoscopic surgeries. Although promising, they are still on closed surgical trials, so, all of us need to wait a little longer to put them as routine treatment^{3,17,18}.

CONCLUSIONS

Videosurgery is feasible to be used for the resection of the esophageal leiomyomas, and provides satisfactory results very similar to those with conventional open operation.

REFERENCES

- Bardini R, Segalin A, Ruol A, Pavanello M, Peracchia . Videothoracoscopic Enucleation of Esofageal Leiomyoma. *Ann Thorac Surg* 1992; 54: 576-577.
- Bonavine I, Segalin A, Rosati R, Pavanello M, Peracchia A. Surgical therapy of esophageal leiomyoma. *J am Col Surg* 1995; 181: 257-62.
- Boone J, Draaisma WA, Schipper ME, Broeders IA, Rinkes IH, van Hillegersberg R. Robot-assisted thoracoscopic esophagectomy for a giant upper esophageal leiomyoma. *Dis Esophagus* 2008; 21: 90-3.
- Coral RP, Madke G, Westphalen A, Tressino D, Carvalho LA, Mastalir E. Thoracoscopic enucleation of a leiomyoma of upper thoracic esophagus. *Dis Esophagus* 2003;16(4):339-341
- Everitt NJ, Glinatsis M, McMahon MJ. Thoracoscopic enucleation of leyomioma of the oesophagus. *Br J Surg* 1992; 79: 643.
- Gossot D, Fourquier P, El Meteiini M, Celerier M. Technical aspects of endoscopic removal of benign tumors of the esophagus. *Surgical Endoscopy* 1993; 7: 102-3.
- Kent M, d'Amato T, Nordman C, Schuchert M, Landreneau R, Alvelo-Rivera M, Luketich J. J. Minimally invasive resection of benign esophageal tumors. *Thorac Cardiovasc Surg* 2007; 134: 176-81.
- Li ZG, Chen HZ, Jin H, Yang LX, Xu ZY, Liu F, Yao F. Surgical treatment of esophageal leiomyoma located near or at the esophagogastric junction via a thoracoscopic approach. *Dis Esophagus* 2009; 22:185-9.
- Loviscek LF, Hyoun Yun J, Sun Park Y, Chiari A, Grillo C, Cenoz MC. leiomyoma of esophagus. *Cir Esp*. 2009;85: 147-51.
- Maggi G, Dei Poli M, Gaetini A, Schieroni R, De Simone M, Camandona M, Gasparri G. La nostra esperienza su 6 casi di leiomiomi dell'esofago. *Minerva Chirurgica* 1981; 36: 1035-42.
- Ousadden A, Bourdariat R, Poncet G, Boulez J. Le léiomyome de l'oesophage. Six cas d'énucléation vidéo-assistée. *Presse Med*. 2006; 35: 1649-55.
- Pon M, Manger T, Wolf S, Kahl S, Lippert H. Thoracoscopic enucleation of benign tumor of the esophagus under simultaneous flexible esophagoscopy. *Surg Endosc* 2000; 14: 1146-8.
- Punpale A, Rangole A, Bhambhani N, Karimundackal G, Desai N, de Souza A, Pramesh CS, Jambhekar N, Mistry RC. Leiomyoma of esophagus. *Ann Thorac Cardiovasc Surg* 2007; 13: 78-81.
- Samphire J, Naftoux P, Luketich J. Minimally Invasive techniques for resection of benign esophageal tumors. *Semin Thorac Cardiovasc Surg* 2003; 15: 35-43.
- Seremetis MG, Lyons WS, DeGusman VC, Peabody JW. Leiomyomata of the Esophagus: an Analysis of 838 cases. *Cancer* 1976; 38: 2166-77.
- Solomon MP, Rosemblum H, Rosato FE. Leiomyoma of the Esophagus. *Ann Surg* 1984; 199: 246-8.
- Van der peet AL, Berends Fj, Klinkenberg-knol EC, Cuesta Ma. Endoscopic treatment of benign esophageal tumors: case report of three patients. *Surg Endosc* 2001; 15: 1489.
- Wang AY, Ahmad NA, Zaidman JS, Brensinger CM, Lewis JD, Long WB, Kochman ML, Ginsberg GG. Endoluminal resection for sessile neoplasia in the GI tract is associated with a low recurrence rate and a high 5-year survival rate. *Gastrointest Endosc* 2008; 68: 160-9.