

USE OF PROSTHESES IN SURGICAL CORRECTION OF HIATUS HERNIA*Uso de próteses na correção cirúrgica das hérnias hiatais*Bruno **ZILBERSTEIN**, Juliana Abbud **FERREIRA**, Marnay Helbo de **CARVALHO**,
Cely **BUSSONS**, Arthur Sérgio **SILVEIRA-FILHO**, Henrique **JOAQUIM**, Fernando **RAMOS**Work done at Gastromed - Zilberstein
Institute, São Paulo, Brazil.

ABSTRACT – Background - A major complication after laparoscopic fundoplication is migration of the fundic wrap into the chest, with or without rupture of the valve. This can occur as a result of inadequate closure of the diaphragmatic hiatus, by rupture of sutures or carried by laceration of the muscle fibers manipulated. **Aim** - To verify the efficiency of the use of Dacron® or Prolene® mesh in the reinforcement of the diaphragmatic hiatus. **Methods** - Fifteen patients were operated with mean age of 46 years using laparoscopic antireflux surgery, with Prolene® or Dacron® mesh reinforcement of the hiatal crura. The patients were operated under general anesthesia by laparoscopy using five trocars. The average time of surgery was 120 minutes. No deaths occurred. The mean postoperative time was 3.5 days. Patients returned to normal activities around the 10th postoperative day. The mean follow-up was five years. In only two patients, in which were used in a Dacron® mesh, and in another Prolene®, there was migration of the mesh to the esophageal lumen causing dysphagia. **Conclusion** - The mesh use in laparoscopic hiatoplasties is good alternative to close the diaphragmatic defect in large hiatal hernias, correction of reflux esophagitis associated with Barrett's esophagus or hiatal hernia/esophagitis recurrence after surgical correction.

HEADINGS - Gastroesophageal reflux.
Laparoscopy. Hernia, hiatal.**Correspondencia:**Bruno Zilberstein
E-mail: brunozilb@uol.com.brFonte de financiamento: não há
Conflito de interesses: não háRecebido para publicação: 23/07/2010
Aceito para publicação: 27/10/2010

RESUMO – Racional - Uma das principais complicações após a funduplicatura laparoscópica é a migração do fundo gástrico para o tórax, com ou sem ruptura da válvula. Isso pode ocorrer como consequência de fechamento inadequado do hiato diafragmático, por ruptura das suturas realizadas ou por laceração das fibras musculares manipuladas. **Objetivo** - Estudar a utilização da tela de Prolene® ou de Dacron® para reforçar o fechamento do hiato diafragmático. **Métodos** - Foram operados 15 pacientes (6 homens e 9 mulheres) com idade média de 46 anos (22 a 78) tendo-se realizado operação laparoscópica anti-refluxo, utilizando-se tela Prolene® ou Dacron® para reforçar a crura hiatal. Os pacientes foram operados sob anestesia geral, por videolaparoscopia utilizando cinco trocárteres. **Resultados** - O tempo médio de operação foi de 120 minutos. Não ocorreu nenhum óbito. O tempo pós-operatório médio foi de 3,5 dias. Os pacientes retornaram à suas atividades habituais em torno do 10º dia do pós-operatório. O tempo médio de seguimento foi de cinco anos. Em apenas dois pacientes, nos quais foram utilizadas em um a tela de Dacron® e em outro Prolene®, ocorreu migração da tela para o lúmen esofágico ocasionando disfagia. **Conclusão** - Utilizar tela nas hiatoplastias videolaparoscópicas é boa alternativa para o fechamento dos defeitos diafragmáticos nas grandes hérnias hiatais, na correção da esofagite de refluxo associada ao esôfago de Barrett, ou em caso de recorrência da hérnia hiatal ou esofagite após correção cirúrgica prévia.

DESCRITORES - Refluxo gastroesofágico.
Laparoscopia. Cirurgia. Hérnia hiatal.**INTRODUCTION**

The laparoscopic antireflux surgery is described as definitive treatment for gastroesophageal reflux disease (GERD) two decades ago¹⁶. From its first description in 1991 the laparoscopic management of GERD has been developed and described in several studies as effective and safe technique with excellent functional results and improved quality of life. 2.3 The laparoscopic antireflux operation has shown excellent clinical results in 85 to 95% of cases beyond the reduction in mortality when compared to conventional technique^{10,11,12,21}. Despite the excellent results, there are some reports of increased postoperative complications in laparoscopic technique^{1,3,4,6,8,13,17,18,25}.

Failures caused by triggered it can generate the persistence of reflux symptoms or the development of dysphagia, flatulence or diarrhea, which may become necessary the need for surgical rapprochement¹⁵. One of the major complications after laparoscopic fundoplication is migration of the gastric fundus the chest, with or without rupture of the valve. This can occur as a result of inadequate closure of the diaphragmatic hiatus, by rupture of sutures or carried by laceration of the muscle fibers manipulated²⁸.

The relatively high frequency of postoperative herniation of gastric fundus into the chest after its realization has led some surgeons use a small screen to assist in closing the gap^{2,14,15}. Although this procedure has been shown effective in reducing the rate of herniation Postoperative closure of large hiatal anatomic defects is still a challenge for even the most experienced surgeons due to the great technical difficulty.

In order to present a proposal to this problem, especially in young patients with congenital defects, or Barrett's esophagus is postoperative recurrence, the authors of this paper propose the use of screen nonabsorbable material to reinforce the hiatal crura closure by laparoscopy.

METHODS

From January 2000 to October 2006, a total of 15 patients (six men and nine women) with mean age 56 years (22-85), were considered for anti-reflux procedure laparoscopically using fabric Dacron[®] or Prolene[®] to reinforce the crural hiatal closure.

The basic prerequisites for the procedure in all patients, careful evaluation of symptoms of GERD, upper endoscopy (EDA), contrast radiography of the esophagus, stomach and duodenum (DSE) or cinedeglutograma, 24-hour pH monitoring and esophageal manometry.

The indications for operation were large hiatal hernias (sliding, para-esophageal or mixed) primary or secondary to previous antireflux operation.

All patients signed a consent form to perform the laparoscopic procedure. The mean follow-up was 5 years (40-10). Patients were evaluated postoperatively a week or two, one and three months and then every six months. The EDA was held in three months and one year after the operation. The DSE, manometry and esophageal pH monitoring were performed only when necessary, in the presence of symptoms.

The patients were operated under general anesthesia in a semi-gynecological, with the surgeon standing between the patient's legs and classic five trocars placement.

The operation began with the release of the arm

of left diaphragmatic crus, using a harmonic scalpel, followed by opening the lesser omentum above the hepatic branch of the vagus nerve and dissection of the right arm of the diaphragmatic crus. After dissection of the abdominal esophagus laminar drain was passed to assist the mobilization of the esophagus and its drift into the abdominal cavity with visualization and preservation of the integrity of the anterior and posterior vagus nerves. Was then performed with hiatoplastia points "X", guided by Fouchet probe inserted 12 mm into the esophagus. The following was done to strengthen the esophageal hiatus with the fabric of Dacron[®] or Prolene[®], cut in a "U" and placed around the hiatus, secured with clips like "pig-tail" (Figure 1). Then was made the mixed type of fundoplication by the technique of Spider-Brandalise (Figure 2).

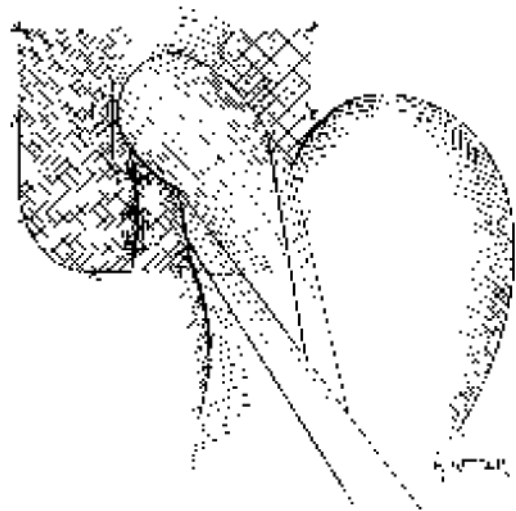


FIGURE 1 – Schematic aspect of the screen fixed on the diaphragmatic hiatus

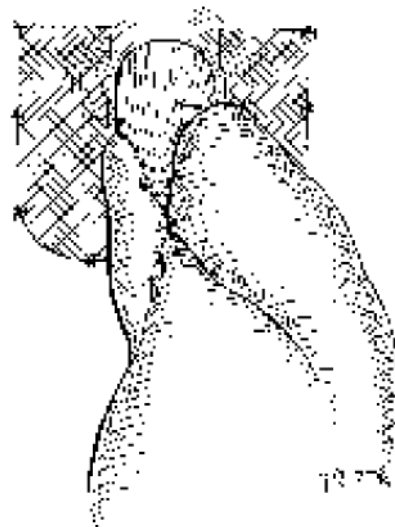


FIGURE 2 – Final aspect of the operation: hiatoplastia mesh fixed fundoplication and mixed

RESULTS

The mean operative time was 120 minutes (40 to 240). In no case has required intensive care postoperatively, nor were no deaths. In one case of reoperation, the adhesions between the fundoplication and the diaphragm led to the intense difficulty of dissection, with consequent pneumothorax on the left, immediately treated with drainage at the end of laparoscopy, and the drain removed on day 2 postoperatively.

Liquid diet was introduced on day 1 postoperatively, with good acceptance in all cases. No cases of postoperative infection. The mean hospital stay was 3.5 days (2-5), with time to return to usual activities an average 10 days (7-15).

Gaseous distension and flatulence occur initially in all patients showed improvement after three to six weeks without specific treatment. Three patients had transient dysphagia improved after three months with conservative treatment.

In 15 patients there were no complications such as dysphagia or persistent fistulas with adjacent viscera and also did not occur late herniation into the chest with a hernia recurrence in a mean period of 5 years (40-10). In only two patients, in which the screen was used in a Dacron® and Prolene® on the other, there was migration of the screen to the esophageal lumen in a patient after 36 months and another after 48 months.

DISCUSSION

Many studies have shown the efficacy of laparoscopic surgery for the treatment of gastroesophageal reflux disease. The long-term results indicate 90% satisfaction among these patients⁷, with short hospitalization and rapid return to activities²⁶.

Although minimally invasive surgery antireflux be widely used as a treatment of GERD, especially in patients requiring long-term treatment, there are some complications from this procedure, being the most common herniation of the fundoplication into the chest, with or without In the same rupture¹³. Also called a slip of the fundoplication may be due to inadequate closure of the diaphragmatic hiatus, or rupture of the sutures hiatoplastia. Another cause is the existence of short esophagus due to inadequate mobilization of this to the abdomen and can lead to increased tension in the fundoplication over the gap²⁷. The use of fabric placed in the hiatal crura showed up, as evidenced in this study, an efficient method to avoid this complication.

Horgan, et al.¹⁷ reported 48 cases of patients who had previously been operated by conventional technique or laparoscopic anti-reflux. The paraesophageal hernia was the most frequently described complication. In addition to preoperative evaluation complete with correct diagnosis and an experienced surgeon, to

improve the performance of the surgical procedure some technical aspects of HPLC should be followed to reduce postoperative complications. There is a general consensus among surgeons that the hiatal closure should be done routinely, regardless of whether or not a hiatal hernia^{5,18,23,24,27}.

Granderath, et al.¹⁴ reported after more than 500 antireflux procedures laparoscopically with routine closure of the hiatus, the hernia of the fundoplication into the thorax was the major cause of treatment failure. In the first series with 361 patients, herniation of the fundoplication into the thorax was observed in 22 patients (6.1%). Some researchers have suggested that the use of prostheses in strengthening the hiatal crura has proven to be a protective factor for the presence of recurrent hiatal hernia or slip of the fundoplication into the chest^{9,22}.

The reinforcement of the prosthesis for hiatal hernia repair has been successfully used by Carlson, et al.⁵. In a randomized study with 31 patients, laparoscopic primary repair of large hiatal hernias was compared with laparoscopic primary repair reinforced with fabric of polytetrafluoroethylene (PTFE). After at 12 to 36 months, they observed significantly lower rate of recurrence of the hernia in relation to the unreinforced PTFE. Frantzides, et al.⁹ concluded the same with a randomized clinical trial of 72 patients. In this study, there was clinical improvement without recurrence of reflux or slippage. Despite the small number studied two cases of migration of the screen to the esophageal lumen. This finding is alert to the application of this technique to avoid this complication.

CONCLUSION

The use of nonabsorbable fabric as reinforcement of the hiatal crura can be considered good procedure to prevent slippage of the fundoplication into the chest, the opening of the esophageal hiatus and the need for reoperation. However, the migration of the screen to the esophageal lumen is a potential complication of this procedure and should be thoroughly analyzed the indication for its use.

REFERENCES

1. Andreollo NA, Lopes LR, Coelho-Neto JS. Doença do refluxo gastroesofágico: qual a eficácia dos exames no diagnóstico? *ABCD Arq Bras Cir Dig* 2010; 23(1):6-10.
2. Basso N, De Leo A, Genco A et al. 360 degrees laparoscopic fundoplication with tension-free hiatoplasty in the treatment of symptomatic gastroesophageal reflux disease. *Surg Endosc* 14: 164-9.
3. Behrns K E, Schlinkert R T. Laparoscopic management of paraesophageal hernia: early results. *J Laparoendosc Surg* 1996; 6: 311-7.
4. Brandalise A, Nasi A, Falcão A, Cenatti A, Gama-Rodrigues J. Influence of the technical variants for measuring the lower esophageal sphincter pressure in the evaluation of gastroesophageal reflux disease. *ABCD Arq Bras Cir Dig* 2002; 15(2):67-70.
5. Carlson M A, Richards C G, Frantzides C T. Laparoscopic prosthetic reinforcement of hiatal herniorrhaphy. *Dig Surg* 1999; 16: 407-10.

6. Cuschieri A, Shimi S, Nathanson L K. Laparoscopic reduction, crural repair, and fundoplication of large hiatal hernia. *Am J Surg* 1992; 163: 425–30.
7. Dallemagne B, Weerts J M, Jhaes C, Markiewicz S. Causes of failures of laparoscopic antireflux operations. *Surg Endosc* 1996; 10: 305–10.
8. Edelman D S. Laparoscopic paraesophageal hernia repair with mesh. *Surg Laparosc Endosc* 1995; 5: 32–7.
9. Frantzides C T, Madan A K, Carlson M A, Stavropoulos G P. A prospective, randomized trial of laparoscopic polytetrafluoroethylene (PTFE) patch repair vs simple cruroplasty for large hiatal hernia. *Arch Surg* 1999; 133: 906–8.
10. Frantzides C T, Richards C, Carlson M A. Laparoscopic repair of large hiatal hernia with polytetrafluoroethylene. *Surg Endosc* 1999; 13: 906–8.
11. Fuchs K H, Feussner H, Bonavina L, Collard J M, Coosemans W. Current status and trends in laparoscopic antireflux surgery: results of a consensus meeting. The European Study Group for Antireflux Surgery (ESGARS). *Endoscopy* 1997; 29: 298–308.
12. Granderath F A, Kamolz T, Schweiger U M, Bammer T, Pointner R. Outcome after laparoscopic antireflux surgery: fundoplication and re-fundoplication in the elderly. *Chirurg* 2001; 72: 1026–31.
13. Granderath F A, Kamolz T, Schweiger U M, Pointner R. Laparoscopic refundoplication with prosthetic hiatal closure for recurrent hiatal hernia after primary failed antireflux surgery. *Arch Surg* 2003; 138: 902–7.
14. Granderath F A, Schweiger U M, Kamolz T, Pasiut M, Haas C F, Pointner R. Laparoscopic antireflux surgery with routine mesh-hiataloplasty in the treatment of gastroesophageal reflux disease. *J Gastrointest Surg* 2002; 6: 347–53.
15. Granderath F A, Kamolz T, Schweiger U M, et al. Failed antireflux surgery: quality of life and surgical outcome after laparoscopic refundoplication. *Int J Colorectal Dis*. 2003;18:248-253.
16. Hinder R A, Filipi C J, Wetscher G, Neary P, DeMeester T R, Perdiks G. Laparoscopic Nissen fundoplication is an effective treatment for gastroesophageal reflux disease. *Ann Surg* 1994; 220: 472–81; discussion 481–3.
17. Horgan S, Pohl D, Bogetti D, Eubanks T R, Pellegrini C A. Failed Antireflux surgery. What we have learned from reoperations? *Arch Surg* 1999; 134: 809–17.
18. Hunter J G, Smith C D, Branum G D et al. Laparoscopic fundoplication failures: patterns of failure and response to fundoplication revision. *Ann Surg*, 1999; 230: 595–604; discussion 604–6.
19. Huntington T R. Laparoscopic mesh repair of the esophageal hiatus. *J Am Coll Surg* 1997; 184: 399–400.
20. Kamolz T, Granderath F A, Bammer T, et al. Mid- and long-term quality of life assessments after laparoscopic fundoplication and refundoplication: a prospective single unit review of 500 antireflux procedures. *Dig Liver Dis*. 2002;34:470-476.
21. Kamolz T, Wykypiel H Jr, Bammer T, Pointner R. Quality of life after laparoscopic antireflux surgery – Nissen fundoplication. *Chirurg* 1998; 69: 947–50.
22. Keidar A, Szold A. Laparoscopic repair of paraesophageal hernia with selective use of mesh. *Surg Laparosc Endosc Percutan Tech* 2003; 13: 149–54.
23. Lopes LR, Andreollo NA. “Técnica de Brandalise” – Técnica mista de fundoplicatura por videolaparoscopia – reconhecimento de autoria de modificação e introdução de técnica anti-refluxo no Brasil. *ABCD Arq Bras Cir Dig*. 2008;21(2):49-50.
24. Nigro R, Ceconello I, Gama-Rodrigues J, Pinotti HW. Diagnostic features of Barrett’s esophagus with and without stricture. *ABCD Arq Bras Cir Dig* 2001; 14(1):280.
25. Paul M G, DeRosa R P, Petrucci P E, Palmer M L, Danovitch S H. Laparoscopic tension-free repair of large paraesophageal hernias. *Surg Endosc* 1997; 11: 303–7.
26. Peters J H, DeMeester T R. Indications, benefits and outcome of laparoscopic Nissen fundoplication. *Dig Dis* 1996; 14: 169–79.
27. Soper N J. Laparoscopic management of hiatal hernia and gastroesophageal reflux. *Curr Probl Surg* 1999; 36: 765–838.
28. Soper N J, Dunnegan D. Anatomic fundoplication failure after laparoscopic antireflux surgery. *Ann Surg*. 1999;229:669-676