

VERTICAL GASTROPLASTY WITH JEJUNOILEAL BYPASS - NEW TECHNICAL PROCEDURE

Gastroplastia vertical com desvio jejunoileal - novo procedimento técnico

Bruno **ZILBERSTEIN**, Arthur Sergio da **SILVEIRA-FILHO**, Juliana Abbud **FERREIRA**,
Marnay Helbo de **CARVALHO**, Cely **BUSSONS**, Henrique **JOAQUIM**, Fernando **RAMOS**

From Gastromed-Instituto Zilberstein, São Paulo, SP, Brasil.

ABSTRACT - Introduction - Vertical gastroplasty is increasingly used in the surgical treatment of morbid obesity, being used alone or as part of the duodenal switch surgery or even in intestinal bipartition (Santoro technique). When used alone has only a restrictive character. **Method** - Is proposed association of jejunoileal bypass to vertical gastroplasty, in order to give a metabolic component to the procedure and eventually empower it to medium and long term. Eight morbidly obese patients were operated after removal of adjustable gastric band or as a primary procedure associated to vertical banded gastroplasty with jejunoileal bypass laterolateral and anastomosis between the jejunum 80 cm from duodenojejunal angle and the ileum at 120 cm from ileocecal valve, by laparoscopy. **Results** - The patients presented themselves without complications both in trans or in the immediate postoperative period, and also in the months that followed. The evolution BMI showed a significant reduction ranging from 39.57 kg/m² to 28 kg/m². No patient reported diarrhea or malabsorptive disorder in the period. **Conclusion** - It can be offered a new therapeutic option, with restraining and metabolic aspects, in which there are no consequences as the ones founded in procedures with duodenal diversion or intestinal transit alterations.

HEADINGS - Sleeve gastrectomy. Jejunoileal diversion. Obesity. Surgery.

Correspondence:

Bruno Zilberstein,
e-mail brunozilb@uol.com.br

Financial source: none
Conflicts of interest: none

Recived for publication: 28/09/2011
Accepted for publication: 18/02/2011

DESCRITORES - Gastroplastia vertical. Desvio jejunoileal. Obesidade. Cirurgia.

RESUMO - Introdução - A gastroplastia vertical é procedimento técnico cada vez mais utilizado no tratamento cirúrgico da obesidade mórbida, sendo empregado isoladamente ou como tempo cirúrgico do duodenal switch ou da bipartição intestinal (técnica de Santoro). Quando empregada isoladamente tem apenas caráter restritivo. **Método** - É proposta a associação do desvio jejunoileal à gastroplastia vertical, no sentido de conferir um componente metabólico ao procedimento e eventualmente potencializá-lo a médio e longo prazos. Foram operados oito pacientes com obesidade mórbida após a retirada da banda gástrica ajustável ou como procedimento primário associado à gastroplastia vertical e desvio jejunoileal através de anastomose laterolateral entre o jejuno a 80 cm do ângulo duodeno jejunal e o íleo a 120 cm da válvula ileocecal, por videolaparoscopia. **Resultados** - Os pacientes evoluíram sem qualquer intercorrência tanto no trans como no pós-operatório imediato, e nos meses que se seguiram. A evolução do IMC médio, mostrou redução expressiva indo de 39,57 kg/m² para 28 kg/m². Nenhum paciente referiu diarreia ou qualquer quadro disabsortivo no período estudado. **Conclusão** - Pode-se oferecer nova opção terapêutica, com ação restritiva e metabólica, na qual não existem os inconvenientes do desvio do trânsito duodenal com todas suas consequências.

INTRODUCTION

The vertical banded gastroplasty (GV) technic procedure is increasingly employed in the surgical treatment of morbid obesity. This surgical option emerged as the initial operating time of the operation known as "duodenal switch", proposed by Michel Gagner⁵ for patients with super obesity or high surgical risk. It was intended the patient to get slim surgical conditions to complete the final time the "duodenal switch". It was observed that in many cases, the weight loss was sufficient and effective in reducing excess weight and comorbidities in the short and long term, eliminating the additional time the "duodenal switch".

In such way, GV has gained notoriety and got a place as surgical technique for morbid obesity treatment due to its characteristics: purely restrictive gastric banding similar to, but without using any prosthesis, and devoid of any metabolic or malabsorptive component, to release of incretins^{2,3}.

Its action was therefore linked to the elimination of ghrelin-producing area, according to the resection of gastric fundus and removal of approximately $\frac{3}{4}$ of the stomach^{6,8}.

Several authors^{4,10} besides Marceau⁹ and Baltazar¹, came to associate different twists and partitions, especially looking at metabolic point of view. The objective was to maximize the effects of the GV, not only in inducing weight loss after surgery, but the maintenance of lean weight in the long term.

In order to give these features with GV procedure, less aggressiveness and thus lower morbidity and mortality, these authors proposed associate GV with a simple side-to-side jejunoileal bypass.

The aim of this study is to report the technique and results in the short term (one year) with this technique.

METHOD

Technique

All patients were operated by laparoscopy under general anesthesia in a semi-gynecological, with the surgeon from the patient's legs. Were placed five trocars, the first 10 mm, for placement of 30° optics, 10 cm above and 7 cm to the left of the umbilicus; the second 12 mm was for right hand job of the surgeon and introduction of staplers, 3 cm below the costal left, in left nipple line; the third of 12 mm for the left hand of the surgeon and introduction of staplers, 6 cm below the right costal margin, in right nipple line; the fourth of 5 mm at the level of the xiphoid process for placement the liver retractor; the fifth of 5 mm, for the introduction of auxiliary clamps, parallel to the optical trocar on the left flank, anterior axillary line. The operation was initiated indifferently by jejunoileal bypass or the vertical banded gastroplasty.

Is recommended to perform vertical gastrectomy (Figure 1) significantly thinning the stomach. It begins with gastric devascularization at the greater curvature of the antrum, about 3 cm to 4 cm from the pylorus, releasing it from the gastric fundus with careful dissection of the oesophagogastric angle, short gastric vessels and posterior surface of the gastric fundus. After this release is introduced Fouchet probe, 12 mm, transduodenal to shape the gastric curvature and also define the caliber of the remaining stomach.

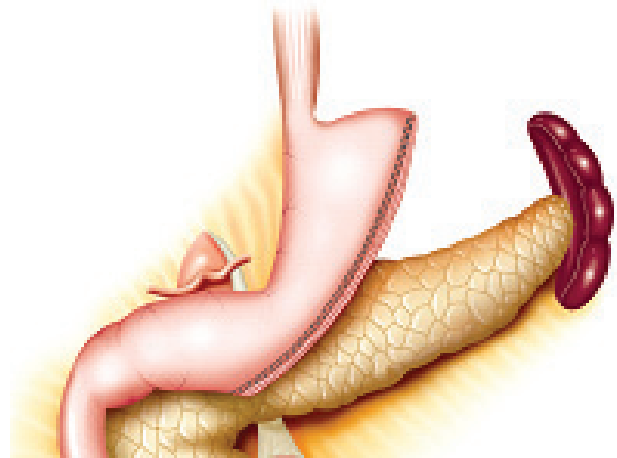


FIGURE 1 - Vertical gastroplasty

Resection of the stomach antrum begins by employing load green or blue, the surgeon's discretion. It is important that the staple line is shaped by intragastric probe, trying to do a gastric tube of about 20 mm to 25 mm in diameter. The section goes under direct vision to the oesophagogastric angle.

It is recommended and emphasized the need for continuous seromuscular suture performed over it. The intention of this maneuver is to protect the suture line, seeking to decrease the risk of fistulas and / or bleeding.

To perform the jejunoileal bypass (Figure 2) was identified first duodenal jejunal angle. It is measured by the jejunum contramesenteric edge in 80 cm. At this level, was applied a suture to fix and anchor the jejunal loop or the stomach, either in the round ligament, to identify it later. Six inches below was applied another point of suture to define the level of the distal jejunal and facilitate placing of the ileal loop. Then, it was identified the ileocecal valve and measured 120 cm of distal ileum, also contramesenterically in cranial direction. The point of the distal ileal loop was sutured to the proximal jejunal loop. The distal point as repaired, the jejunal loop was sutured to the proximal point of the ileal loop. This way, was created the presentation for laterolateral jejunoileal anastomosis. Then, with the aid of staples with 45 mm white load, was prepared the jejunoileal anastomosis. The point of repair was sectioned and removed. Was created splitting of the gut, leaving the bowel intact as far left in the abdominal cavity.

The mesenteric aperture was closed with nonabsorbable suture to prevent internal hernia

Initial series

Were operated on eight patients, four women and four men, ranging in age from 19 to 49 years (mean 31.4 years). Four underwent the procedure with the removal of the gastric band in terms of not being able to lose weight properly with

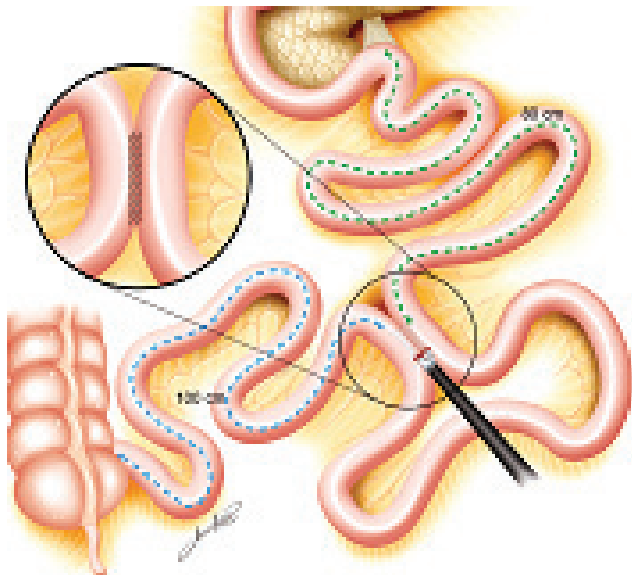


FIGURE 2 – Laterolateral jejunioileal deviation

this method. The other patients underwent the procedure as the first option. The BMI ranged from 35 to 45 (average BMI of 39.57). No patients had comorbidities such as hypertension, diabetes or sleep apnea.

All interventions took place without complications; operative time was between 150 and 180 minutes. It was not recorded any early or late postoperative complication. All patients were discharged on the 2nd day after surgery, having been restarted feeding with liquid diet in the first. There was a loss of 50% to 60% of excess weight in the first six months. No patient reported diarrhea in their evolution. The average BMI at the end of the first year was 28 kg/m².

DISCUSSION

GV procedure is widely used in recent years around the world. A recent metanalysis involving 15 publications and 940 patients¹³ showed complications, such as fistula, in 1.17% (+ / - 1.86) and bleeding in 3.57% (+ / - 5.15%). Marked mortality was 0.3%, with complications of the general order of 12.1%. The loss of excess weight was 59.8% in the first year, 64.7% in the second and the third 66%, with resolution of comorbidities ranging from 45% to 95%.

These results do not differ statistically from those obtained in the adjustable gastric band and not in septation gastric bypass with Roux-en-Y^{2,3}. As with adjustable gastric banding, is difficult to predict the sustainability of weight loss in long term. It is known that with these operations there is return to morbid obesity levels in 15% to 30% of patients¹⁶.

Thus, in the case of restrictive procedure alone, it can be assumed that there would be long-

term weight regained only with vertical banded gastroplasty. This fact has already been described in reports of patients whose stomach is enlarged and the patients regained their lost weight⁷. In this case, further intervention is required, remaking the vertical banded gastroplasty, or turning it into septation gastric bypass with Roux-en-Y or performing the duodenal diversion. To avoid these disadvantages and still provide a characteristic of metabolic operation totally restrictive, the indicated procedure was proposed.

Because of being a new intervention, the sample is small with short follow-up time; so, long-term conclusions about the regained weight and resolution of comorbidities must wait for new papers. Although these circumstances, the proposed procedure is simpler than the duodenal bypass, Fobi-Capella procedure or regastroplasty.

CONCLUSIONS

Due to the initial results, without complications or mortality, this technique - jejunioileal bypass with vertical banded gastroplasty - should be considered in the list of nominees for the treatment of morbid obesity.

REFERENCES

- Baltasar A, Serra C, Perez N. Laparoscopic sleeve gastrectomy: a multi-purpose bariatric operation. *Obes Surg.* 2005;15(8):1124-8
- Buchwald H. Consensus conference statement bariatric surgery for morbid obesity: health implications for patients, health professionals, and third party payers. *Surg Obes Relat Dis.* 2005;1(3):371-81.
- Buchwald H, Avidor Y, Braunwald E, Jensen ME, Pories W, Fahrback K and Schoelles K. Bariatric Surgery; A systematic Review and Meta-analysis. *JAMA* 2004; 292:1724-1737.
- de Paula AL; Silva A; de Paula CL; Vencio S; Halpern A. Aspectos técnicos da interposição ileal com gastrectomia vertical como possível opção ao tratamento do diabetes mellitus tipo 2. *ABCD, Arq Bras Cir Dig.* 2010; 23:128-130
- Gagner M;Gumbs AA;Milone L; Yung E;Goldenberg L;Pomp A. Laparoscopic sleeve gastrectomy for the super-super-obese (body mass index >60 kg/m²). *Surg Today* 2008;38:399-403
- Hari Kumar KVS, Ugale S, Gupta N, Naik V, Kumar P, Bhaskar P, Modi KD. Ileal Interposition with Sleeve Gastrectomy for Control of Type 2 Diabetes. *Diabetes technol Ther.* 2009; 11:785-789.
- Himpens J, Dapri G, Cadiere GB. A prospective randomized study between laparoscopic gastric banding and laparoscopic isolated sleeve gastrectomy: results after 1 and 3 years. *Obes Surg.* 2006; 16(11):1450-6
- Muscelli E, Mingrone G, Camastra S, Manco M, Pereira JA, Pareja JC, Ferrannini E. Differential effect of weight loss on insulin resistance in surgically treated obese patients. *Am J Med.* 2005 Jan; 118(1):51-7
- Marceau P;Biron S; St Georges R et al. Biliopancreatic diversion with gastrectomy as surgical treatment of morbid obesity. *Obes Surg.* 1991;1:381-7
- Pories WJ. Bariatric Surgery: Risks and Rewards. *J Clin Endocrinol Metab* 2008; 93: S89-S96

11. Regan JP, Inabnet WB, Gagner M. Early experience with two-stage laparoscopic Roux-en-Y gastric bypass as an alternative in the super-super obese patient. *Obes Surg.* 2003;13(6):861-4.
12. Santoro S, Velhote MCP, Malzoni CE, Mechenas ASG, Damiani D, Maksoud JG. Digestive Adaptation with Intestinal Reserve: A New Surgical Proposal for Morbid Obesity. *Rev Bras Videocir* 2004; 2: 130-8.
13. Shi X; Kamali S; Scharma AM; Birch DW. A review of laparoscopic sleeve gastrectomy for morbid obesity. *Obes Surg.* 2010;20(8):1171-7
14. Zilberstein B, Alex Cleiton Garcia de Brito, Henrique Dameto Giroud Joaquim, Michele Gatti Carballo. Banda gástrica com desvio jejunoileal: Nova opção técnica em cirurgia bariátrica. *ABCD, Arq Bras Cir Dig.* 2010; 23(2):100-4
15. Zilberstein B, Pajecki D, Brito ACG, Gallafrio ST, Eshkenazy R, Andrade CG. Simultaneous Gastric Banding and Cholecystectomy in the Treatment of Morbid Obesity. Is it feasible? *Obesity Surgery* 2004;14: 1-4.
16. Zilberstein B, Pajecki D, Brito ACG, Gallafrio ST, Eshkenazy R, Andrade CG. Topiramate after Adjustable Gastric Banding in Patients with Binge Eating and Difficulty Losing Weight. *Obesity Surgery,* 2004;14: 802-805.