

COMPARATIVE STUDY OF COTTON, POLYGLACTIN AND POLYGLYCAPRONE SUTURES IN INTESTINAL ANASTOMOSES IN DOGS

Estudo comparativo entre os fios de algodão, poliglactina e poliglicaprone nas anastomoses intestinais de cães

Walter Octaviano **BERNIS-FILHO**¹, Flademir **WOUTERS**¹, Angélica Aparecida Barth **WOUTERS**¹,
Valéria Magro Octaviano **BERNIS**¹, Luiz Roberto **LOPES**², Nelson Adami **ANDREOLLO**²

From ¹Department of Clinics and Surgery, School of Veterinary Medicine, Alfenas University (José do Rosário Vellano University-UNIFENAS), Alfenas, MG and ²Department of Surgery, Digestive Diseases Division, School of Medical Sciences, State University of Campinas – UNICAMP, São Paulo, SP, Brazil.

ABSTRACT - Background - Over the years, many sutures were developed and then abandoned. Until now was not found an ideal suture to the intestinal tract or other tissues in general, making the choice a difficult task. **Aim** - To evaluate, macroscopically and microscopically, the healing process of intestinal anastomoses in dogs using polyglycaprone 25, polyglactin 910 and cotton sutures. **Methods** - Twenty adult male dogs were operated on and underwent to three small bowel anastomosis using the technique with submucosal sutures. Were used three threads and the anastomoses were evaluated at different postoperative periods - group I - three days; group II - seven days; group III - 14 days and group IV - 21days. Macroscopic analysis was to assess the presence or absence of peritonitis, aspect of the anastomosis and adhesions. Histological studies of the anastomoses, using hematoxylin and eosin and Masson's trichrome analyzed the exudative inflammation, granulomatous inflammation, the mucosal epithelial coating and collagen fibers. **Results** - The macroscopic analysis showed good coaptation of the edges with a moderate degree of adhesion between the intestines and omentum three to 21 days after surgery. The microscopic evaluation revealed exudative inflammation with neutrophils and fibrin, which ranged from mild to moderate until the 14th day; granulomatous inflammation with macrophages, multinucleated giant cells and epithelioid cells were more evident at 14th day for the cotton, presence of granulation tissue (fibroblasts) and collagen fibers, a moderate way, from the 7th for the three threads. **Conclusion** - All three threads showed similar behavior and thus they can be indicated for anastomoses of the small intestine.

HEADINGS - Comparative Study. Suture Techniques. Sutures. Dogs.

Correspondence:

Walter Octaviano Bernis Filho,
e-mail: valbernis@oi.com.br

Financial source: none
Conflicts of interest: none

Received for publication: 09/09/2012
Accepted for publication: 27/11/2012

RESUMO - Racional - Nos últimos anos muitos fios de sutura foram desenvolvidos e depois abandonados. Até hoje não foi encontrado um fio cirúrgico ideal aos intestinos ou a outros tecidos de um modo geral, tornando sua escolha tarefa difícil. **Objetivo** - Avaliar macro e microscopicamente a cicatrização de anastomoses do intestino delgado de cães, utilizando suturas com fios de poliglicaprone 25; poliglactina 910 e algodão. **Métodos** - Vinte cães machos adultos foram operados e submetidos a três anastomoses no intestino delgado empregando a técnica extramucosa com pontos separados. Foram utilizados os três tipos fios e as anastomoses foram analisadas em diferentes períodos no pós-operatório: grupo I - três dias; grupo II - sete dias; grupo III - 14 dias; grupo IV - 21dias. A análise macroscópica consistiu em avaliar a presença ou não de peritonite, aspecto das anastomoses e aderências. Os estudos histológicos das anastomoses, empregando a hematoxilina e eosina e o tricrômico de Masson analisaram a inflamação exsudativa, inflamação granulomatosa, o revestimento epitelial da mucosa e as fibras colágenas. **Resultados** - Na avaliação macroscópica os fios apresentaram boa coaptação das bordas com moderado grau de aderência entre alças e omento do 3º ao 21º dia do pós-operatório. A avaliação microscópica mostrou inflamação exsudativa com neutrófilos e fibrina que variou de discreta a moderada até o 14º dia; inflamação granulomatosa com presença de macrófagos, células gigantes multinucleadas e células epitelioides mais evidentes ao 14º dia para o fio algodão; presença de tecido de granulação (fibroblastos) e fibras colágenas, de forma moderada, a partir do 7º dia para os três fios. **Conclusão** - Os três tipos de fios de sutura apresentaram comportamento semelhante, com boa cicatrização e podem ser recomendados em anastomoses do intestino delgado.

DESCRITORES - Estudo Comparativo. Técnicas de Sutura. Sutures. Cães.

INTRODUCTION

Over the years, many sutures were created and then abandoned because of the good results obtained with new products. Still, so far no one has found an ideal suture to the intestinal tract or other tissues in general, making your choice difficult. This justifies the need for research of new materials in order to find the perfect option.

Currently, for carrying out the several operations, both in humans and animals, there is a wide variety of suture materials, absorbable and nonabsorbable, with physical properties, mechanical and chemical different among them.

Traditionally, in most general and digestive surgeries, the surgeons use cotton^{7,9,15,22} and polyglactin^{6,16,17,26} in intestinal anastomosis. The poliglecaprone²⁵, as a monofilament, absorbable and low reagent^{2,4,13,24} thread has been used in urological surgeries²⁷ and also in some gastrointestinal surgeries^{3,4,12,20,26,28}.

The absorbable monofilament sutures, such as, polydioxanone, the polyglyconate and poliglecaprone 25 are considered materials of choice for use in contaminated wounds. Nylon and polypropylene monofilament and nonabsorbable sutures are also indicated for the same wound. The tissue reactivity is minimized through the use of monofilament material. Among the sutures which stimulate the minimum reaction are polypropylene, nylon, steel, polydioxanone, polyglyconate, polyglactin 910, polyglycolic acid, or poliglecaprone 25 and are preferred over the catgut, silk or polyester. The catgut, due to their excessive reactivity has been replaced by absorbable and synthetic sutures^{3,18}. The synthetic and absorbable monofilament suture offers excellent sliding characteristics and cause minimal trauma, due to its smooth structure and gradual biogradation^{1,18}.

The poliglecaprone 25 is a synthetic absorbable suture monofilament prepared from a copolymer of epsilon-caprolactone and glycolide causing only mild tissue reaction for the absorption by hydrolysis. Initially, the tensile strength of poliglecaprone 25 is higher than the catgut and remains during the first three weeks after implantation. The tensile strength is maintained at 60-70% at seven days, 30% after 14 days and complete loss of tensile strength at 28 days post implantation. The absorption is completed between 91 and 119 days¹⁸. It has the most ideal properties of a suture, as not antigenic, non-pyrogenic, easy handling, high tensile strength and minimum initial tissue reaction during absorption, as is recommended in abdominal surgery, as the twisted, routinely used¹⁸. Moreover, it has better tensile strength and straight property management

when compared to other absorbable monofilament suture such as polydioxanone and polyglyconate¹⁸. Bezwada et al.² demonstrated in vivo that the tensile strength of the threads remains in 20-30% after two weeks, during the considered critical healing. Samel et al.²⁵ in 181 surgeries for resection of small intestine with submucosal sutures, not observed dehiscence and stenosis. In two separate studies, the authors used polyglecaprone 25 and recommend its use in suturing the skin, superficial and deep vascular ligatures with low tension, gastrointestinal anastomosis, urinary tract and gynecological disorders. But do not recommend its use in abdominal closure, vascular surgery, neurosurgery and ophthalmology or surgery underwent to great tension^{4,24,25}.

Molea et al.¹⁸ in a study comparing polyglecaprone 25 with glicomer 631 concluded that was less reactive compared to polydioxanone, when used in the fascia of the rectus abdominis muscle of 72 rats due to low response, and therefore the three sutures were well tolerated. Nary Filho et al.¹⁹ compared the tissue response employing the polyglecaprone 25, polyglactin 910 and polytetrafluoroethylene in rat dorsal subcutaneous tissue. The results showed that the poliglecaprone 25 induced mild inflammatory response, followed by polyglactin 910 and polytetrafluoroethylene, respectively. Whitfield et al.²⁹ evaluated the influence of the polyglactin 910, polydioxanone, polyglecaprone 25, chromic catgut and nylon in the closure of the peritoneum and the formation of intra-abdominal adhesions. They observed that no suture was superior, where the polyglactin 910 had the lowest degree of inflammation and cronical fibrosis.

Therefore, the poliglecaprone 25 has several advantages, including the excellent handling property, the minimum resistance of the suture passing through the tissue, and higher tensile properties comparable to absorption polyglactin 910^{2,13,25}.

A variety of suture materials available for the various tissues and particularly for the gastrointestinal tract, where the risk of infection is higher, always requires a new comparative study on the suture materials.

The objective of this study was to evaluate, macroscopically and microscopically, the wound healing of intestinal anastomosis performed in the jejunum of dogs, comparing the cotton, polyglactin 910 and polyglecaprone 25.

METHODS

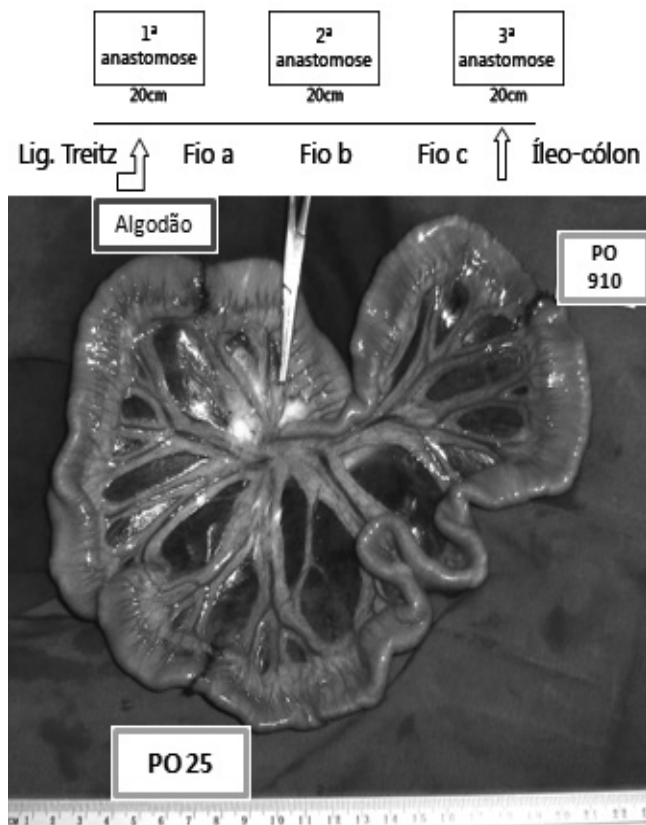
This study was performed after approval from the José do Rosário Vellano University (UNIFENAS)

Committee on Ethics Research, under number 20A/2007. Twenty healthy male mongrel dogs, weighing from 9 to 16 kg, from the university kennel were divided in four groups of five animals and operated on according to the protocol: first the animals of the group 1 (GI, three days), then the group 2 (GII, seven days), group 3 (GIII, 14 days) and the group 4 (GIV, 21 days).

Intestinal anastomoses were carried out with cotton (Polycot®), polyglecaprone 25 (Monocryl®) and polyglactin 910 (Vicryl®), size 3-0 and with 2,5 cm, taper-point needle. Preoperatively, they were submitted to water and food fasting for 12 hours. Thirty minutes before surgery they received, intravenously, 5 mg/kg of enrofloxacin (Baytril®), 1,1 mg/kg of flunixin meglumine (Banamine®) and 2 mg/kg of tramadol hydrochloride (Tramal®). Preanesthetic medication included, intramuscularly, 2 mg/kg of xylazine hydrochloride (Rompum®) plus 0,044 mg/kg of atropine sulfate (Atropinon®). Fifteen minutes after, the cephalic vein was cannulated, and a ringer lactate solution was perfused at 15 mg/kg/hour, during the entire surgical procedure. Anesthetic induction was accomplished by sodium penthotal at 2,5% (Tiopentax®), in an average dose of 12,5 mg/kg. The patient was then intubated (orotracheal tube Embramac®) and inhaling general anesthesia with enflurane (Enflurano®) was maintained in semiclosed circuit with spontaneous ventilation. After antisepsis of the abdominal wall, a trans-umbilical laparotomy was performed, permitting access to the internal organs. A 20 cm proximal segment of the jejunum, from the duodenojejunal ligament, was isolated, where the first total transversal section was made, followed by its anastomoses. Other two transversal sections were performed, 20 cm apart from each other, followed by its respective anastomosis.

Alternately, the three types of suture materials were used. Before suturing the intestinal wounds, three fragments of each anastomosis site were collected and they served for histopathological control (they were referred to as preoperative samples). Anastomoses were done on a single plane, with isolated stitches, about 3 mm one from the other, on a seromuscular pattern, the knots situated outside the bowel lumen and care being taken not to invert or evert the edges of the intestinal wound, keeping them as just as possible^{15,22}.

The 20 animals were divided into four groups named GI (three days), GII (seven days), GIII (14 days) and GIV (21 days), composed of five dogs in each group. Each animal received three anastomoses at the delimited jejunal area and the threads were used in distinct positions (a,b,c; c,a,b; b,c,a). In the two remaining animals the positions were chosen by chance (Figure 1).



(PO 910= polyglactin 910 ; PO25 = polyglecaprone 25)

FIGURE 1 - Intestinal anastomosis sequence performed with cotton (a), polyglactin 910 (b) and polyglecaprone 25 (c)

The abdominal cavity was closed after the three anastomoses were completed, with three suture planes. In the immediate postoperative period the animals received intravenously ringer's saline solution (55 ml/kg/day), twice daily and food intake being held for another 24 hours⁸.

Operated animals were kept in individuals kennels, during all the observation period and at the end they were euthanized at three, seven, 14, 21 days, postoperatively, following the orientation and respecting the recommendations of the Brazilian College for Animal Experimentation (COBEA).

They were necropsied in order to evaluate the abdominal cavity and the anastomotic sites conditions. The following details were observed: general cavity aspect, internal aspect of the suture lines, presence or absence of adhesions at the wall, at the omentum and at the bowels.

The anastomotic sites were individually examined to evaluate the presence of adhesions: absence(-); discrete/minimal (+); moderate between two segments (++); intense, involving three or more bowels (+++). These segments were longitudinally opened at the mesenteric site and quantitatively evaluated as to the suture line aspect: bad (-), fistula and threads apparent; normal (+), no fistula but two

threads evident; good (++) , no fistula and only one thread apparent; very good (+++), no fistula and no visible threads. Tissue samples were then collected for macroscopic and microscopic analyses.

Histopathological studies were conducted on three fragments of each anastomotic segment (including 5 cm before and beyond the anastomotic border) of all animals. These fragments were fixed in Bouin solution for 48 hours and thereafter in 70% ethyl alcohol. They were then sliced at 4 μ and two slides were put by hematoxilin-eosine and by Masson's trichromic staining.

The preoperative samples obtained, at this time, served to compare the healing process, after the surgeries, in each group, as well as the behavior of the suture materials used to close the intestinal opening.

The microscopic studies considered the lesion, the inflammation and the process of repairing^{7,15}. The evaluation of intestinal necrosis, the exudative and/or chronic (granulomatous) inflammatory reaction at the sutures considered the following criteria: absent (-); presence of minimal intensity (+); presence of moderate intensity (++); presence of great intensity (+++).

The occurrence (or not) of continuity of the mucosa was also searched. The observation of proliferating fibroblasts and of collagen fibers followed the same above criteria. Graphics were made according to the thread used and microscopic aspects involved.

Statistical analysis

The objective was to describe and compare distinct groups of five dogs each time postoperatively, in relation to the data from the macro and microscopic findings, for each one of the threads used in the same animal.

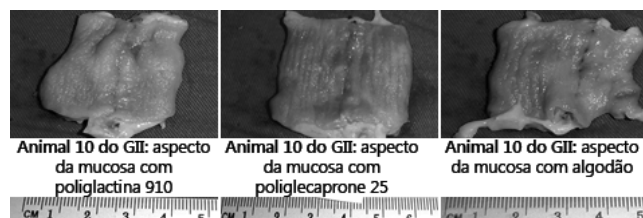The variables among postoperative groups and the threads used were also compared using the Qui-Square or Fisher Exact tests. To compare the numeric variables, among the four groups, the Kruskal-Wallis test was used, followed by Dunn's multiple comparative tests. To compare scores of the macro and microscopic alterations among the four postoperative groups and among the three threads, the variance analysis (ANOVA) for repeated measurements was used. Tukey test for multiple comparisons of groups, in each thread, was also used to compare them in each group. The variables were transformed into ranks due to the absence of normal distribution. The significance level for the statistical tests was 5% ($p < 0,05$).

RESULTS

Macroscopic analysis

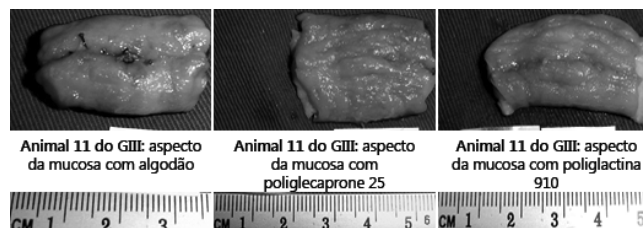No alterations (inflammatory fluids and signs of peritonitis) were found at the abdominal cavity of all operated animals and the internal organs being found with normal aspects. In general all anastomoses showed good coaptation of the sutures. The suture with the polyglycaprone 25 presented better, between three and seven days postoperatively compared to other two threads, observing the similar results with polyglactin 910 compared to cotton. At the seventh day after surgery, there was no evidence of stenosis, the mucous membrane showed adequate coaptation. (Figures 2 and 3).

Adhesions at the abdominal wall have not been recorded except for one case, in each group, after the seventh day of surgery, from slight to moderate. Adhesions of the epiploon to intestinal anastomosis were more evident on day 7, for cotton, for the wires polyglactin 910 and polyglycaprone 25, between 3 to 14 days to polyglactin 910 and for cotton compared to polyglycaprone 25 on the 21st day of postoperatively. This adhesion could involve part or the whole area of the loop anastomosed and was present in most animals operated with maximum degree on the 7th day, for cotton and polyglycaprone 25 and to 21 for the polyglactin 910. The adhesion between the bowel was more evident with cotton on the 7th day after surgery compared to polyglactin 910 and polyglycaprone 25, the same happened to the polyglactin 910 polyglycaprone 25 compared to day 14. The increase in adhesion area of the anastomosis with cotton and polyglycaprone 25 on day 21 after surgery compared to 14 days and the reduction of adhesions polyglactin 910 in the same period, was not significant. The results were similar to epiploon adhesions.



(GII) on 7th post-operative day

FIGURE 2 - Internal aspect of the suture line: polyglactin 910, polyglycaprone 25 and cotton



(GIII) on 14th post-operative day

FIGURE 3 - Internal aspect of the suture line: cotton, polyglycaprone 25 and polyglactin 910

Microscopic Analysis

Exsudative inflammation

This phase was characterized by vasodilation, inflammatory edema with eosinophilic amorphous material composed of filaments of fibrin and inflammatory infiltrate consisting predominantly by neutrophils. There was a significant difference by Tukey's test for cotton compared to polyglcaprone 25, between seven and 21 days and between 14 and 21 days, with shorter reaction on day 21.

The reaction to polyglactin 910 was more uniform from three to 21 days after surgery; however, there was no difference between the three threads and no interaction between groups and threads (Figure 4).

Granulomatous inflammation

Were observed in this phase inflammatory infiltrates composed of macrophages, epithelioid cells and multinucleated giant cells, related to the suture. Some of these cells contain in their cytoplasm fragments of phagocytosed material. In the anastomoses using cotton, granulomatous inflammation was greater between the 3rd and subsequent days postoperatively, the same occurring between seven and 14 days. A similar situation happened with polyglcaprone 25; however, the inflammatory response with multinucleated giant cells decreased from day seven after surgery. As for the polyglactin 910 group no longer visible reaction from the 3rd day and remained similar between seven and 21 days, postoperatively. The inflammation had its peak of reaction, on the 7th day after surgery to the polyglcaprone 25 and day 14 for the polyglactin 910 and cotton, and decreased in all cases from day 14 (Figure 4).

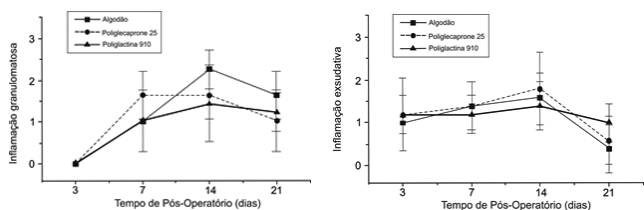


FIGURE 4 - Exsudative and granulomatous inflammation considering (- = 0) absent; (+ =1) minimal intensity; (++)=2) moderate intensity; (+++ =3) great intensity

Granulation tissue

Were found newly formed blood vessels interspersed with proliferation and migration of fibroblasts. There were significant differences by Tukey test, between the 3rd and subsequent days postoperatively for all three threads types

analyzed, which showed increased formation of granulation tissue and concentration of fibroblasts of up to 14 days. Between 14 and 21 post-operative days there was a slight decrease in the presence of the elements analyzed (Figure 5).

Mucosal epithelial coating

There were analyzed the absence of epithelial surface coating, with or without the presence of necrotic material. Significant increase was recorded between three and seven, maximum on day 14 and decreased between 14 and 21 days postoperatively for cotton. There were similar between three and seven days and significant increases between three and 14, seven and 14 days, decreasing until day 21 after surgery for polyglactin 910. The polyglcaprone 25 showed similarity to polyglactin 910 (Figure 5).

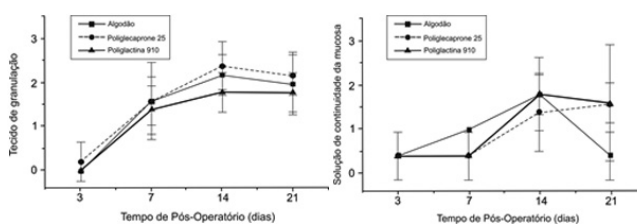


FIGURE 5 - Granulation tissue and mucosal epithelial coating considering (- = 0) absent; (+ =1) minimal intensity; (++)=2) moderate intensity; (+++ =3) great intensity

Collagen fibers

The collagen fibers were identified as dense eosinophilic, stained green, through the technique of Masson's trichrome. There were differences between groups of three to 21 days postoperatively for cotton and poliglecaprone 25. The polyglactin 910 showed the presence of fibers, similar to other threads; however, with the greatest difference between seven and 21 days after surgery (Figure 6).

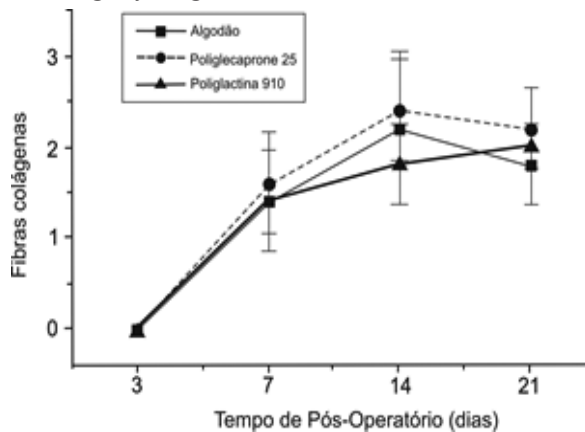


FIGURE 6 - Collagen fibers considering (- = 0) absent; (+ =1) minimal intensity; (++)=2) moderate intensity; (+++ =3) great intensity

DISCUSSION

Especially in the gastrointestinal tract, during the exudative inflammatory phase of the tissue healing in general, an appropriate suture should cause less inflammation and be of local and limited duration, keeping unchanged its tensile strength. In these aspects, the nonabsorbable suture has the following advantages over absorbable: easiness of sterilization and no allergic reactions²². However, the nonabsorbable suture, remains a long time at the surgical site, may cause a more prolonged chronic inflammation and increased chances of infection. Thus, the optimal surgical thread is one that remains in the tissue, in sufficient time so that it regains its required tension, causing an inflammatory response short in duration and reaction²³.

In this study were performed three intestinal anastomoses in the jejunum, with an interval of about eight inches between them, in healthy dogs, comparing three surgical sutures. There was no statistical difference when comparing the site of anastomosis, with the groups studied (three, seven, 14 and 21 days after surgery). Similar results were obtained by several authors in multiple ileal anastomoses in cattle, dogs and rabbits, without any interference between them^{10,11,16,30}.

The animals progressed well during the postoperative period without complications, eating a normal diet (divided three times daily), initiated 24 hours after the operation. The appearance of the abdominal cavity was normal in all animals and there were no leaks or infection.

Braghetto et al.⁴ used polyglycaprone 25 (2-0 or 3-0) in suture continues or suture with separate stitches in 81 patients undergoing various surgical procedures, including gastro-intestinal surgery, and post-operative follow-up, from 4th to the 28th day. Concluded that the intestinal anastomosis should be free of tension, and the surgical thread must be soft, programmed absorbing time and maintain suitable tension. These authors reported no postoperative complications, whereas more than 50% of patients had risk factors such as malignancy or repetitive surgeries.

Bezwada et al.², conducting a similar study concluded that polyglycaprone 25 has a higher tensile strength and is ease of handling compared to other absorbable monofilament thread (such as polydioxanone and maxon), emphasizing that it kept breaking tensile strength up to two weeks, which is the critical period of healing.

Solomon²⁴ obtained similar results with polyglycaprone 25 in gynecology and obstetrics, demonstrating easiness of passage and sliding through the tissues, absence of relaxation and safe knots. Thus research found similar results confirming

reports in the literature.

On the other hand, Ribeiro et al.²¹ employing rats concluded that the polyglycaprone 25 offers a little tough knot and remained in the muscle and skin until the 28th day after surgery. Conn Jr. et al.⁵ emphasize the safety in use and the implementation and maintenance of the surgical knots of the polyglactin 910, and its tensile strength is similar to that of polyester threads.

Adhesions found in the abdominal wall were similar in the post-operative days, with a more favorable response to polyglactin 910 and polyglycaprone 25. Trautwein²⁸ and Whitfield et al.²⁹ did not found differences between the polyglycaprone 25, polyglactin 910, the chromic catgut, polydioxanone and mononylon. In this research, omentum and adhesions of the bowel loops occurred more frequently with cotton and a lower frequency with polyglycaprone 25. It is known that the intestinal serosa, when handled, show great tendency to adhesions in places where there was a micro or macro trauma. And other factors to be considered are those concerning the constitution of physical chemistry suture materials, their rejection or acceptance for the recipient organism.

Therefore, it is important to highlight a safety, easy handling and reduced or absent capacity of the polyglycaprone 25 in to cause adverse and exacerbated reactions in the organic tissues. The healing aspect of the suture line showed very good coaptation of the anastomosis, with greater emphasis on polyglycaprone 25.

In relation to exudative inflammation, this research found that a discrete reaction occurs between 3rd and 7th days, moderate until the 14th day and decreasing to mild to 21st days after surgery, without differences between the threads. The inflammatory infiltrate consisting of neutrophils was more evident on 14th day. The granulomatous reaction related to the suture was absent at 3rd day, increased to moderate 7th to 21st days, with polyglycaprone 25 and polyglactin 910 returning to mild. Cotton provoked more intense and more obvious presence of macrophages, epithelioid cells and multinucleated giant cells, on the 14th day after surgery, becoming moderate at 21st days.

Faria et al.⁷ comparing different suture threads in serosubmucosal in the stomach concluded that the inflammatory reaction to the cotton was of medium intensity of 7th to 21st days after surgery. All the unabsorbed threads tested (mononylon, cotton and silk) caused granulomatous type reaction and the authors concluded by preferring cotton thread, because of its easy handling, being shipper and presenting discrete inflammatory reaction, a little more intense, compared to mononylon. And comparing cotton with polyglycolic acid in the anastomosis of the small intestine in dogs, other

authors² observed in most animals (21/24), in the post-operative period (48 hours, 96 horas, 7th and 15th days), mild exudative inflammatory reaction only after 48 hours and the same for both. The granulomatous reaction caused by them, was earlier and more intense with polyglycolic acid.

Conn Jr. et al.⁵ compared the polyglactin 910 with silk, plain catgut and chromic catgut in the rectus fascia of the abdomen of rabbits, concluding that the polyglactin 910 has advantages over others. The histopathological reaction proved to be minimal, with little exudate necrotic and scarce presence of giant cells around the polyglactin 910, from 5th to 60th day; the results were similar to those found in this study, because was not found granulation tissue from 15th day, while in this study, its presence was maximum 14th to 21st days after surgery.

Mantovani et al.¹⁵ using cotton in anastomosis of small intestine with serosubmucosal sutures, reported better results compared with other techniques, because it was found minimal degree of necrosis, inflammatory phenomena of low intensity and epithelialization of the mucosa from the 4th day after surgery. Deveney et al.⁶ performing gastrointestinal anastomoses in dogs and using the absorbable sutures, chromic catgut, Dexon® and polyglactin 910, found no significant difference between them. However, they found invasion of sutures marked by macrophages and giant cells with catgut.

Bezwała et al.² employed the polyglecaprone 25 in the gluteal muscles of mice and the histological examination found minimal or mild reactions from 3rd to 91st days, with macrophages and fibroblasts, few lymphocytes and plasma cells, small numbers of polymorphonuclear cells and occasional giant cells. Results with similar inflammatory reaction (infiltration of neutrophils and mononuclear cells) was obtained in other studies^{18,19} between 48 hours and seven days, using the polyglecaprone 25, compared to the polyglactin 910 (moderate reaction) and polytetrafluoroethylene (intense reaction) in subcutaneous tissue of rats. No inflammatory reaction was observed with polyglecaprone 25 and only slight with polyglactin 910 in the 14th and 21st post-operative day and these authors recommend the use of polyglecaprone 25^{18,21}. However, Ribeiro et al.²¹ reported intense inflammatory reaction on 7th day after suturing of the subcutaneous tissue and muscle of rats, and decreasing the response by 28th day, as the polyglecaprone 25 was absorbed.

Kirpensteijn et al.¹² employed three types of sutures in eight dogs by performing enterotomies using polyglactin 910 and polyglecaprone 25. They found no macroscopic and microscopic differences after 14th and 28th days. These results were similar to another study that evaluated the same threads in intradermal suture of dogs; however, the differences

were only visible during the first seven days after surgery¹³.

Trautwein²⁸ compared prolene, polyglecaprone 25 and monosyn suturing the jejunum of dogs at 3rd, 7th and 14th post-operatively, concluding that all sutures had exudative reactions in serous and below it, with mild to moderate presence of fibrin, neovascularization and granulocytes in the anastomosis.

Santos Filho²⁶ compared polyglactin 910 and polyglecaprone 25 applied to the anterior gastric wall of 14 dogs with serosubmucosal suture and concluded that the inflammatory reaction was minimal for both, but with advantages of manipulation for the latter. And the granulation tissue showed newly formed blood vessels interspersed with proliferation and migration of fibroblasts.

This research found increased granulation tissue from 3rd day, reaching a maximum of 14th days to 21st days postoperatively. On the other hand, the collagen fibers had similar behavior granulation tissue.

The mucosal epithelial coating ranged from absent (three cases) to mild (two cases) at 3rd days, progressing to discrete with cotton (five cases) on the 7th day, moderate (four cases) on 14th day and, practically absent (three cases), on 21st day. The polyglactin 910 and polyglecaprone 25 showed similar behavior. Therefore, the three threads showed similar results in 7th to 14th days, with a more pronounced decrease for cotton at 21st days, compared to polyglactin 910 and polyglecaprone 25. These observations can be interpreted as an active process of absorption by the body of foreign material (threads) inserted. Macroscopically, the mucosa near the anastomosis was in perfect coaptation, since the 3rd post-operative day, in the three threads used in this experiment.

Faria et al.⁷ recorded on 14th day, a plot of cotton fibers bounded by granulation tissue, rich in giant foreign body, associated with a proliferative response of fibroblasts, which remained until 21st day after surgery. On the other hand, Mantovani et al.¹⁵ using serosubmucosal suture with cotton, found marked proliferation of collagen, minimal hyperemia, absence of exudative mucosal reaction on the 15th day and no interruption of the mucosa of post-operative. These results are in agreement with the results found in this study with cotton, although with a slight exudative reaction in 14th and absent at 21st days. The young connective tissue, which develops when acute processes are eliminated, appears early and becomes fibrous tissue, completing the healing process²².

Mantovani et al.¹⁵ emphasized that during the healing process, the proliferation of fibroblasts and collagen fibers, both the intensity and in time, is inversely proportional to the phenomena of injury and

inflammation, verified at the initial stage. Deveney et al.⁶ found at the 7th day chronic inflammation around the sutures, as well as prominent granulation tissue and invasion by macrophages. In 14th days, they observed chronic inflammation with occasional microabscesses, foreign body giant cells near the sutures, and even invaded by macrophages, collagen formation and regeneration of mucosa, with no difference between the threads in the quality of healing.

However, Runk et al.²³ evaluated the polyglycaprone 25 in the midline of cats and found on 7th day fibromononuclear or pyogranulomatous reaction, on the 14th day fibromononuclear or granulomatous reaction and on 21st day pyogranulomatous, granulomatous and fibrous fibromononuclear reaction. Of the eight studied animals, three showed reaction in eosinophilic inflammatory infiltrate on 7th day, but not at 14th and 21st days postoperatively.

Bahten et al.¹ compared the healing and the adhesion formation in rats' spleen submitted to spleen surgical trauma and sutured with octil-2-cyanoacrylate and polyglycaprone 25 thread concluding that the first provoked less macroscopic adhesions.

Nary Filho et al.¹⁹ found on 7th day, employing the polyglycaprone 25 in subcutaneous sutures a moderate mononuclear infiltrate and discrete fibroblastic and angioblastic proliferation. On the 14th day they observed organized tissue with collagen fibers, abundant fibroblasts and capillaries and at 21st days post-operatively had connective tissue around the suture. And for the polyglactin 910, on the 7th day, observed discrete conjunctive tissue, with angioblastic proliferation, fibroblasts and a moderate number of mononuclear leukocytes. However, in 14th and 21th days were found foreign body giant cells associated with sutures. They concluded that the inflammatory response to the polyglycaprone 25 was less intense and produced better biological responses. Other researchers have obtained lower inflammatory reaction with the polyglycaprone 25 on 14th day, but higher in 21st and 28th days compared to mononylon²¹. The formation of granulation tissue was higher in the mononylon sutures in four time periods (7th, 14th, 21st, 28th days) no regression from 14th day, compared to polyglycaprone 25. The fibroblast proliferation (fibrosis) decreased with the evolution of the healing process in the polyglycaprone 25 sutures; however, increased with mononylon at 28th day after surgery²¹.

Therefore, the results obtained in this study were very similar to literature. On this occasion, it must be emphasized that the polyglactin 910 showed a minimal inflammatory reaction, acute or chronic. Moreover, there was formation of granulation tissue

with proliferation of fibroblasts from the 3th day, increasingly, with a peak up to 14th day, when it was registered a slight decline until 21st day to three threads studied (cotton, polyglycaprone 25 and polyglactin 910). The same results in the production of collagen fibers (fibrosis) were found, although these reactions to polyglactin 910 were slightly more evident. The mucosal epithelial coating on 14th day showed a moderate degree, for the three threads, probably due to their expulsion into the intestinal lumen, because macroscopically all the anastomoses were perfectly lined-up. Some differences were found among researchers such as the occurrence of giant cells (macrophages), fibroblast proliferation and collagen fibers, the intensity of inflammation in the post-operative period. Of course, these differences are details that must be taken into account including: the technique used, type of thread used, location of sutures, animal species used in research, and intrinsic conditions for these experiments.

The performance of three anastomoses in the same animal testing three types of sutures, allows the use of fewer animals, without interfering in the final results. Because they are absorbable and show foreign body reaction less marked, the polyglactin 910 and polyglycaprone 25 can be employed for such operations. The observation times in the post-operative period (3rd, 7th, 14th and 21st days) were adequate to assess the healing gut.

The polyglycaprone 25 is less employed in gastrointestinal surgery according to the literature; however, has the qualities of a good synthetic absorbable suture and nonabsorbable, commonly indicated in such surgeries.

It is important to remember that beyond the sutures, other factors influence the adequate healing of intestinal anastomoses, contributing to the occurrence of fistulas and dehiscences such as: open and laparoscopic surgeries, local infections, blood loss during surgery, blood transfusions, associated diseases, chemotherapy and radiotherapy, use of anticoagulants, mechanical or manual sutures and one layer or two layers anastomoses¹⁴.

CONCLUSIONS

The three types of threads used in this study – cotton, polyglactin 910 and polyglycaprone 25 – were similar and can be indicated in small bowel anastomosis.

REFERENCES

1. Bahten LC von, Noronha L, Silveira F, Nicolletti G, Longhi P, Pantanali CAR. Healing study in spleen traumatic injury made in rats using octil-2-cianoacrylate and 25 poliglecaprone thread. Rev Col Bras Cir. 2006; 33(3):174-180.

2. Bezwada RS, Jamiolkowski DD, Lee IY, Agarwal V, Persivale J, Trenka-benthin S, Erneta M, Suryadevara J, Yang A, Liu S. Monocryl suture, a new ultra pliable absorbable monofilament suture. *Biomaterials*. 1995;16:1141-8.
3. Boothe jr H W. Selecting suture materials for small animal surgery. *Comp Cont Educ Prat. Vet*. 1998;20(2):155-62.
4. Braghetto M, Rappoport JS. Evaluación prospectiva de sutura poliglecaprone 25 (monocryl) en cirugía general. *Revta Chilena Cirugia*. 1994;46(3):299-305.
5. Conn Jr J, Oyasu R, Welsh M, Beal JM. Vicryl (poliglactin 910) synthetic absorbable sutures. *Am J Surg*. 1974; 128: 19-23.
6. Deveney K E, Way LW. Effect of different absorbable sutures on healing of gastrointestinal anastomosis. *Am J Surg*. 1977;133:86-94.
7. Faria PAJ, Pasqualucci MEA, Medeiros RR, Mantovani M, Vieira RW. Comparative study of suture materials on dogs stomachs using extramucous synthesis technic. *Rev Assoc Med Bras*. 1968;15(1):3-10.
8. Garvey MS. Fluid and electrolyte balance in critical patients. *Vet Clin North Am Small Anim Pract*. 1989;19(6):1021-57.
9. Guimarães AS, Ferreira AL, Aprilli AS, Carril CF. Comparison between intestinal anastomosis in 1 and 2 suture layers by study of blood vascular branching and cicatrization. Experimental work on the small intestine of the dog. *Rev Ass Med Bras*. 1974;20(3):97-101.
10. Hesp LEM, Hendriks T, Schillines P H M, Lubbers EJC, De Boer HHM. Histological features of wound repair: a comparison between experimental ileal and colonic anastomoses. *Br Exp Path*. 1985;66:511-8.
11. Jansen A, Becker AE, Brummelkamp WH, Keeman JN, Klopper PJ. The importance of the apposition of the submucosal intestinal layers for primary wound healing of intestinal anastomosis. *Surg Gyn Obstet*. 1981;152:51-8.
12. Kirpensteijn J, Maarschalkerweerd RJ, Gaag, I Van der, Kooistra HS, Van sluijs FJ van. Comparison of three closure methods and two absorbable suture materials for closure of jejunal enterotomy incisions in healthy dogs. *Vet Quart*. 2001;23:67-70.
13. Kirpensteijn J, Maarschalkerweerd RJ, Koeman JP, Kooistra HS, Van Sluijs FJ. Comparison of two suture materials for intradermal skin closure in dogs. *Vet Quart*. 1997;19(1):20-2.
14. Luján JJ, Németh ZH, Barratt-Stopper PA, Bustami R, Koshenkov VP, Rolandelli RH. Factors influencing the outcome of intestinal anastomosis. *Am Surg*. 2011;77(9):1169-75.
15. Mantovani M, Leonardi LS, Alcântara FC, Medeiros RR, Fagundes, JJ, Hadler WA. Comparative study of different sutures in 1 or 2 layers on the large intestine. Experiments on dogs. *Rev Ass Med Bras*. 1976;22(3):79-86.
16. Mbiuki SM. Small intestinal reaction to suture materials in cattle. *Vet Record*. 1983;113:64-5.
17. McDonald CC, Baird, RL. Vicryl intestinal anastomosis. *Dis Colon Rectum*. 1985;28:775-6.
18. Molea G, Schonauer F, Bifulco G, D'angelo D. Comparative study on biocompatibility and absorption times of three absorbable monofilament suture materials (polydioxanone, poliglecaprone 25, glycomer 631). *Br J Plast Surg*. 2000;53(2):137-41.
19. Nary Filho H, Matsumoto MA, Batista AC, Lopes LC, Góes FCGS, Consolaro A. Comparative study of tissue response to polyglactin 910, polyglactin 910 and poly tetrafluorethylene suture materials in rats. *Braz Dent J*. 2002;13(2):86-91.
20. Olah A, Belágyi T, Neuberger G, Gamal EM. Use of different absorbable sutures for continuous single-layer anastomosis in the gastrointestinal tract. A prospective, randomized study. *Diag Surg*. 2000;17(5):483-5.
21. Ribeiro CMB, Silva Jr VA, Silva Neto JC, Vasconcelos BCE. Clinical and histopathological study of tissue reactivity to monofilament suture materials: nylon and polyglactin 910 in rats. *Acta Cir Bras*. 2005;20(4):284-91.
22. Rosemberg D, Nasser A, Regen JB, Behmer OA. Comparative study between cotton thread and a new absorbable synthetic thread, polyglycolic acid, in intestinal sutures in 1 extramucous plane. *Rev Paul Med*. 1973;81:201-14.
23. Runk A, Allen SW, Mahaffey E. A tissue reactivity to poliglecaprone 25 in the feline linea alba. *Vet Surg*. 1999;28:466-71.
24. Salomão AJ. Sutura monocryl. avaliação prospectiva em ginecologia e obstetrícia. *J Brasil Ginecol*. 1996;106(112):35-9.
25. Samel ST, Heinrich A, Becker H, Post S. Continuous single layer anastomoses with monofilament poliglecaprone sutures in abdominal surgery. *Eur J Surg*. 1999;165:710-1.
26. Santos Filho HA. Macroscopic and microscopic evaluation and videoendoscopic observation of the gastric sutures in dogs with polyglactin and polyglactin. Doctoral Thesis. Rio de Janeiro Federal University, 2004.
27. Schauffert MD, Simões MJ, Juliano Y, Novo NF, Gomes PO, Ortiz V. Study of the action of chromed catgut and polyglactin 910 of the threads in the ileocystoplasty in rats, highlighting the formation of stone. *Acta Cir Bras*. 2000;15(1):23-7.
28. Trautwein VM. Jejunorrhaphy with polyglycolic acid glicomer: A comparative study in dogs. Master's thesis. Evangelical School of Paraná. Curitiba. 2000.
29. Whitfield RR, Stills HF, Huls HR, Crouch JM, Hurd WW. Effects of peritoneal closure and suture material on adhesion formation in a rabbit model. *Am J Gynecol*. 2007;197(6):1-5.
30. Wise L, Mcalister W, Stein T, Schuck P. Studies on the healing of anastomoses of small and large intestines. *Surg Gynec Obstet*. 1975;141:190-4.