

# GIANT INCISIONAL HERNIAS

## *Grandes hérnias incisionais*

Manlio Basilio **SPERANZINI**<sup>1</sup>, Claudio Roberto **DEUTSCH**<sup>2</sup>

From <sup>1</sup>ABC School of Medicine and <sup>2</sup>Faculty of Medicine, University of São Paulo, Brazil

**ABSTRACT – Background** – The correction of abdominal hernias remains one of the most common surgical procedures since it occurs in about 11% of laparotomies. There are several risk factors. Arise, in general, the first five years after the operation and their management is controversial. **Aim** – Update the means and methods for surgical repair of giant abdominal hernias. **Method** – Literature review based on PubMed, Lilacs and Scielo with crossing the keywords “abdominal hernia, prostheses, surgical techniques and complications”, and adding its own contribution based on the authors’ experience in handling this condition. **Conclusion** – Even the successful correction with the use of large prostheses, may happen procedure inconvenient, because the abdominal wall does not resume its elasticity and compliance at the normal. For this reason, it is important that the patient be advised of the possibility of their expectations regarding the outcome, both aesthetic and functional, not be achieved.

**HEADINGS** – Abdominal hernia. Prostheses. Surgical techniques and complications.

### **Correspondência:**

Manlio Basilio Speranzini,  
E-mail: manlio.sp@uol.com.br

Fonte de financiamento: não há  
Conflito de interesses: não há

Recebido para publicação: 27/05/2010  
Aceito para publicação: 05/10/2010

**DESCRIPTORES** – Hérnia abdominal. Próteses. Complicações cirúrgicas. Técnica cirúrgica.

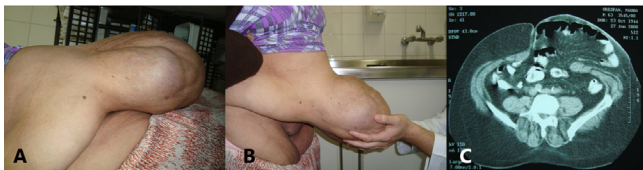**RESUMO – Introdução** – A correção de hérnias incisionais abdominais permanece como um dos procedimentos cirúrgicos mais comuns uma vez que ela ocorre em cerca de 11% das laparotomias. Vários são os fatores de risco. Surgem, em geral, nos primeiros cinco anos após a operação e seu manuseio ainda é controverso. **Objetivo** – Atualizar os meios e métodos empregados para a correção cirúrgica das hérnias abdominais gigantes. **Método** – Revisão da literatura com base no Pubmed, Scielo e Lilacs com cruzamento dos descritores “hérnia abdominal, próteses, complicações e técnicas cirúrgicas”, e adicionando contribuição própria baseada na experiência dos autores no manuseio desta afecção. **Conclusão** – Mesmo as correções bem sucedidas, com a utilização ou não de grandes próteses, não são os procedimentos isentos de inconvenientes, pois a parede abdominal não retoma a sua elasticidade e complacência normais. Por este motivo, é importante que o paciente seja alertado da possibilidade da sua expectativa em relação ao resultado, tanto estético quanto funcional, não ser alcançada.

## INTRODUCTION

The correction of abdominal hernias (HIA) remains one of the most common surgical procedures since it occurs in about 11% of laparotomies. There are several risk factors that include obesity, advanced age, malnutrition, multiple laparotomies, type of incision and technical care in closing the abdominal wall (including the quality and diameter of suture material used), postoperative infection of surgical wounds, illness chronic obstructive pulmonary disease and diabetes. The HIA arise, in general, the first five years after the operation<sup>1</sup>.

The initial per-operative factors - wound infection, suture technique imperfect, poor quality of aponeurotic tissue and increased intra-abdominal pressure - may play an important role on hernia evolution. Its late appearance is due to a little-known mechanisms, such as changes in connective tissue<sup>5,9</sup>. However, studies with metallic markers at the edges of the sheath of the rectus muscles<sup>20</sup> and with CT by measuring the distance between the inside edges of these three muscles<sup>5</sup>, showed that the process that leads to the formation of HIA starts in the first week after surgery and that its clinical manifestation may take years, contributing to both increased weight, the deterioration of patients’ physical status and age. This finding emphasizes the responsibility of the surgeon in its prevention by adequate care in both the abdominal wall closure as the prophylaxis of wound infection.

There are difficulties in drawing up a classification of HIA because of its great diversity and heterogeneity<sup>18</sup>. A simple classification for which data are readily obtained is that of Chevrel and Rath<sup>7</sup>, which proposed three criteria to classify the HIA: location (medial and lateral), size (assuming that the width of the defect is more important than the surface, length or size of the hernia sac) and the number of relapses<sup>6</sup>. Hernia with a width of less than 5 cm is considered small, between 5 and 10 cm wide, 10 to 15 cm is very large and giant<sup>14</sup> above this value. In this article the focus will be on the giants HIA that emerge, especially after median incisions, responsible for 80% of them (Figure 1 A, B, C).



A- Patient in supine showing the "second abdomen".  
 B- With the patient standing, abdomen sustained by the examiner can reach the middle 1/3 of the thighs.  
 C- Computed tomography scan showing abdominal viscera between the skin and abdominal wall

**FIGURE 1** – Great HIA post umbilicus midline incision

Large hernias are accompanied by marked reduction of muscle-aponeurotic tissue of the abdominal wall, muscle atrophy of the abdomen with a large loss of their anatomical and physiological features that determine severe visceral and respiratory impairment<sup>24</sup>. The low intra-abdominal pressure, changes the function of the diaphragm promoting its lower and progressive lethargy. As a result, patients may have respiratory problems due to the synergism changed the abdominal wall, the incoordination between the chest wall, diaphragm and abdominal muscles. Occurs a decrease in total respiratory compliance almost entirely due to also decrease chest wall compliance - whereas the lung remains substantially unchanged - which induces an increase in mechanical work and O<sup>2</sup> consumption by respiratory muscles<sup>17</sup>. Develops chronic respiratory failure, often latent, with functional tests and blood gas little changed in the absence of restrictive or obstructive pulmonary disease pre-existing<sup>14</sup>. However, in patients with low respiratory reserve that will be submitted to correction of HIA, all preoperative care must be taken and surgical maneuvers aiming to minimize the increased work of breathing<sup>4</sup>.

The tendency of HIA is to progressively increase the traction of the lateral rectus muscles, caused by the antagonist action of the lateral muscles of the

abdomen, with the consequent enlargement of the hernia fibrotic ring, small resistance offered by the hernia sac and the herniated contents of their own weight<sup>22</sup>. In large hernias the amount of viscera which progressively stretch and hold the hernia sac is such that it can form a "second abdomen"<sup>14</sup>.

The herniated viscera are adapted to local and extra-abdominal, due to the position before the "second abdomen," the meso extends and becomes thickened by the difficulty of venous and lymphatic return, and there are chronic bowel dilatation due to loss of balance between the visceral and parietal tonus<sup>16,24</sup>. The growth of loops and its meso and retraction of the abdominal cavity cause the intestines lose of their "right to housing" hindering the re-introduction into the cavity - in particular when trying to reconstruct the normal anatomy of the abdomen by approximation of the rectus muscles in the midline -, conditions to produce exaggerated increase of intra-abdominal pressure with serious systemic consequences, particularly respiratory<sup>17</sup>.

The progressive expansion of the hernia sac causes the skin covering of the hernia to be thin, scarce and bad vascularized subcutaneous, and, therefore, frequent areas of necrosis, trophic ulcers and possible intestinal fistulae.

## SURGICAL PROCEDURE

Given the serious and possible postoperative complications of surgical treatment are authors that restrict the indication for surgery for patients with severe skin lesions, obstruction, recurrent intestinal sub-occlusion or marked reduction in the quality of life<sup>15,24</sup>.

### Preoperative

In addition to thorough clinical examination, laboratory tests required for the patient's clinical condition, the size of the operation and repair and/or compensation of associated disease, are other measures aimed at pre-operative preparation. As an example, the ulcers on the skin overlying the hernia, often colonized by bacteria, increase the risk of infection and hence the need to treat them with appropriate care<sup>13</sup>.

Other measures, mainly, aim to improve the respiratory conditions. The CPT held for at least two weeks before the operation and the elimination of smoking, allow the patient to improve the lung capacity and the cough reflex. Weight reduction is highly desirable, although attempts are generally disappointing.

Progressive pneumoperitoneum is a procedure designed to pre-operative more than 60 years. Intent to increase the volume of the abdominal cavity, to enable the re-introduction of the hollow herniated viscera with mesenteric edema by decreasing the the volume of the hollow viscera,

and with this, perform the closure of the abdominal wall without tension. Allow progressive improvement in diaphragm function and would also have the advantage of promoting preoperatively, lysis of intra-abdominal adhesions<sup>21,25,27</sup>. The physiological basis of the technique is the gradual stretching of the abdominal muscles, increasing intra-abdominal space and restoring muscle function and physiological adaptation of many organ systems. For this, the authors injected a total of 15 to 20 liters of air or gas (CO<sub>2</sub>) in three to six weeks, during which, in general, the patient remains in hospital<sup>25</sup>. Given the difficulty in establishing the volume of gas or air needed to promote adequate pneumoperitoneum, computed tomography was used to establish parameters for the quantity of gas to be injected. For this, was calculated the volume of the hernia sac (HSV) and the abdominal cavity (LCA). With these data, the principle was adopted to achieve the progressive pneumoperitoneum case the ratio (VR) between HSV/ACV was greater than or equal to 25%. In this protocol the amount of CO<sub>2</sub> used was an average of 4000 ml (2000-7000) being required by roughly 10 daily injections (4-18) so that the patients in this period remain hospitalized<sup>23</sup>.

Computed tomography of the abdomen performed before and after progressive pneumoperitoneum, can prove the significant increase in the width of the rectus muscle, the anterolateral abdomen space and the hernia orifice<sup>8</sup>, contradicting the view that increasing the width muscles of the abdominal wall does not occur due to the difference in compliance between the hernia sac and abdominal wall<sup>25</sup>. Dumont, et al.<sup>8</sup> point out, however, that the increased percentage of the abdominal muscles does not seem to be correlated with the success in hernia treatment, because, in their series of 61 patients undergoing progressive pneumoperitoneum, the abdominal wall closure without tension was possible in about half the cases, requiring other measures such as relax incisions and even resection of viscera as right hemicolectomy in four patients, and in one was not possible to correct the hernia.

There are differing opinions with those who consider the interest of progressive pneumoperitoneum questionable<sup>7</sup> or even obsolete<sup>25</sup>. According Kingsnorth<sup>13</sup> this procedure was not widely adopted due to its complexity and lack of efficacy<sup>24</sup>. For others it is considered impracticable when the abdominal musculature is atrophic or absent. Moreover, its effects in increasing intra-abdominal pressure are not well known, just as several major abdominal organs are able to adapt to this increase during the pneumoperitoneum, and so, it is possible that they also can tolerate some degree of wall muscle-aponeurotic tension<sup>8,21</sup>.

In large hernias Han, et al.<sup>11</sup> advocate the use of abdominal dressing for two weeks, concurrently

with respiratory therapy until cardiorespiratory function improves, the patient does not feel chest discomfort or dyspnea, normalizes blood gas, and intra-abdominal pressure remains lower than 15 cm H<sub>2</sub>O<sup>11</sup>.

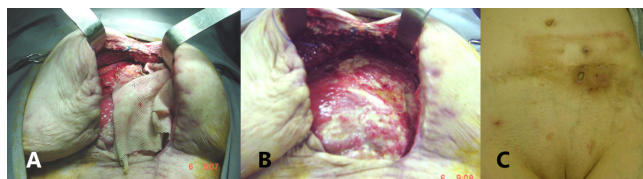
Other measures must be taken preoperatively, as the passage of a nasogastric tube with suction to reduce the distension of the bowel and mechanical preparation of the colon<sup>1,11,24</sup>.

### Operative strategy

Ideally, the abdominal wall reconstruction in patients with large HIA and with loss of "housing rights", should allow the re-introduction of the abdominal viscera without inducing the collapse of the physiological compartment syndrome of the abdomen while making the abdominal wall complacent functional and dynamically<sup>15</sup>.

The ideal surgical treatment, therefore, satisfies the principle of not restricting the volume of the abdominal cavity to avoid raising the intra-abdominal pressure. If it can, there will be an improved compliance of the chest wall while the lung remained unchanged. The expansion of the abdominal cavity restores respiratory acceptable situation by minimizing the total mechanical work of breathing muscles<sup>17</sup>. Despite the numerous techniques available, none of them can fully achieve these goals<sup>14</sup>.

The primary repair of the HIA with the use of own tissues, is only permitted in small hernias (less than 5 cm) given the high incidence of recurrence (63%), with preference for larger hernias be managed with prosthesis, although these also have recurrence rates of to 32%<sup>19</sup> and occasional inconveniences as the development of local complications between 2% and 16%<sup>6</sup>. Among the complications, the most serious is the infection of the prosthesis that occurs particularly in patients with previous skin lesions (skin ulcers, foreign body reaction due to suture material or implants from previous operations) that may lead to its extrusion (Figure 2).

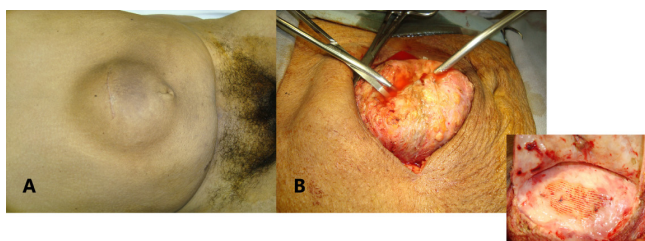


A – After opening the skin, is noted partially loose prosthesis on the muscle-aponeurotic plane.  
 B – Appearance of the wound after removal of the prosthesis, apparently without hernia recurrence.  
 C – Fistulous consequent oozing of the prosthesis. Through one of the holes it can be see the prosthesis.

FIGURE 2 – Suppuration in HIA corrected by prosthesis



The absence of adequate barrier between the prosthesis (in particular macroporous) and the intestine, leads to adhesions and have, as a consequence, syndromes of sub-occlusion/occlusion or intestinal fistulization. Seromas are common, especially observed in the laparoscopic approaches (78% of cases), and is spontaneously resolved, but, sometimes, may last up to 24 weeks<sup>2</sup>. In open surgery, especially when the implant is placed above the muscleaponeurotic layer, the prevention of seromas is made with closed suction drainage and maintained in the first weeks after surgery. Sometimes, especially when care in its prevention is not met, the persistent seromas should be corrected surgically (Figure 3) since the puncturing and emptying, in most cases, is followed by relapse. Furthermore, the incorporation of the prosthesis by connective tissue to the abdominal wall does not support dynamic<sup>10</sup> contractile and often is referred by the patient as a foreign body sensation<sup>11</sup>.



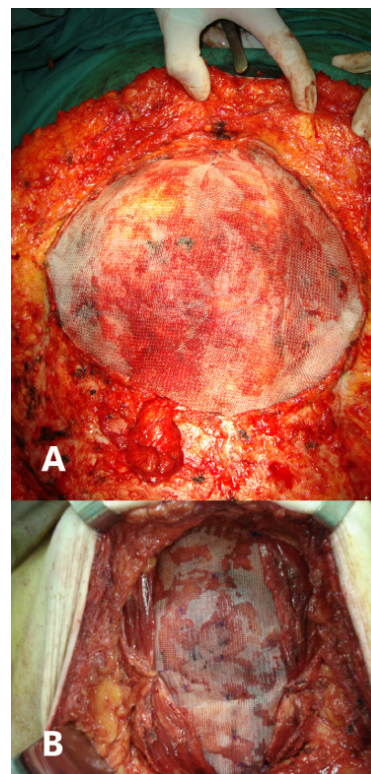
**A** – Bulging tight work under transverse scar.  
**B** – Opening of the skin and dissection of the bulge consisted of a capsule with thick liquid contents; sectioned, drained out sero-hematic fluid. After partial resection of the capsule, note the prosthesis partially enclosed by fibrous tissue.

**FIGURE 3** – Seroma after correction of large epigastric hernia with graft onlay

The choice of surgical technique (open or laparoscopic), the prosthesis and method of fixing it remains controversial. Centers with high volume showed very good early results in selected patients operated both by open and by laparoscopic, although serious complications in 3.5% of cases and reoperation rate after 5 years of 24% were seen<sup>3,12</sup>.

There are three options with respect to the location of the prosthesis: pre- muscleaponeurotic (onlay), retro-muscleaponeurotic (underlay or sublayer) or retro-muscular, and intraperitoneal (inlay) (Figure 4).

Seems to be no statistically significant the difference regarding recurrence between prostheses placed in retro-muscular or pre-muscleaponeurotic position<sup>26</sup>. Theoretically, intraperitoneal prosthesis exhibit greater resistance to abdominal pressure, because pressure would force the prosthesis against the wall. The main problem is the potential risk of visceral lesions as obstruction and fistulization. To reduce these complications it is recommended to use composite prosthetic, being the face that is in contact with the parietal peritoneum



**A** – Correction with onlay graft. The hernia sac was partially resected and sutured to the midline. The sheath of the rectal muscle was opened longitudinally and the prosthesis was placed over the hernia sac, fixed in the lateral edge of the anterior sheath of rectal muscle.  
**B** – Fixing prosthesis with underlay. The same procedure was followed in closing the hernia sac. The prosthesis is placed on the hernia sac, and the posterior lamina of the sheath of rectal muscle is fixed on it. In both figures the arrows indicate the medial border of the rectal muscle

**FIGURE 4** – Surgical correction of large HIA

macroporous (polypropylene or polyester) and the other in contact with the peritoneal cavity of low porosity to prevent adhesions.

The placement of the prosthesis intraperitoneally in the open operation, is an indication to the large incisional hernias, to the multi-recurrent, when associated with intra-abdominal injury, in obese patients and when the laparoscopic approach is contraindicated. Advantages would render unnecessary extensive dissection of the subcutaneous muscleaponeurotic tissue. Despite the cited protection of composite prosthetic against intestinal adhesions, it is recommended, whenever possible, bringing the greater omentum between the viscera and prosthesis<sup>1</sup>. Bernard, et al.<sup>1</sup> showed in their series of 61 patients using polypropylene mesh coated on the intra-cavity face by PTFE, satisfactory results with only 5% of recurrence and morbidity rates of around 5%.

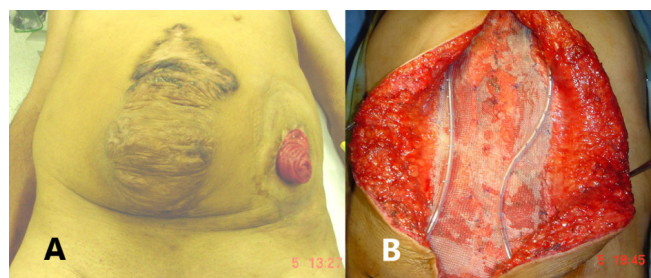
In extreme cases, the so-called giant hernias, the muscles are atrophied and are completely away from the midline, often found near the anterior superior iliac spine, in these cases; Trivellini, et al.<sup>24</sup> proposed that the skin should only be resected after hernia correction and that the hernia sac be not reduced; if the peritoneum

is absent, it can be replaced by polyglactin 910. Over the peritoneum or the polyglactin 910 prosthesis, two polypropylene prosthesis are placed in the preperitoneal space, in retromuscular position and fixed inferiorly to Cooper ligament, superiorly to the ribs and laterally in the muscles with transparietal sutures. Lipman, et al.<sup>15</sup> in these major defects proposed operation in stages; initially put a PTFE graft attached at the edges of the hernia ring and over it the sub-dermal skin. Around 4 or 5 days after surgery, patients return to the operating room, the incision is reopened to remove a 3-4 cm fusiform zone from the prosthesis; then it is closed again at skin edges; this procedure is repeated until only 3-4 cm of the prosthesis is left on. In the final re-intervention, the prosthesis is resected and separation of the components of abdominal wall (longitudinal section of the aponeurosis of external oblique muscle lateral to the edge of the rectus muscle) is done, by open or laparoscopic procedure, and closure of the aponeurosis. With this procedure they operated only eight patients being required, on average, six re-interventions and hospital average stay of 36 days (9-90 days).

### Surgical technique

After the period of physiotherapy, the patient tolerating the supine position and abdominal elastic straps, he was considered fit for operation. The coverage of preoperative antibiotic prophylaxis was routinely performed, usually using cephalosporin (cefazolin), as well as the prevention of deep venous thrombosis of the limbs and pulmonary embolism in patients at risk (pharmacological prevention, compression stockings and early active movement on the bed).

Additional operations, such as fistula or stoma closure should be performed before the dissection for hernia treatment, with the change of the surgical dressing and instruments. After the dissection and preparation for placement of the prosthesis, surgeon and assistants should change gloves and skin antisepsis remake before manipulating the prosthesis (Figure 5). Hemostasis should be always accurate.



A – Note the large extension of the dermal scar with thinning of the skin.

B – After rebuilding the transit and exchange of material, the hernia was corrected by median suture of the edges of the sheath of rectal muscles, followed by longitudinal incision relaxation and placement of onlay graft fixed in the usual manner. Two continuous suction drains (Porto-Vac®) were placed.

FIGURE 5 – Great HIA with colostomy

The skin incision is usually fusiform around the skin changes. The skin over the hernia sac is not dissected, and the sac is dissected until reaching the hernia ring approximately 2 cm from the aponeurotic tissue. In order to not restrict the abdominal cavity after dissection of the hernia sac, opening and lysis of adhesions is done. After reducing the hernia contents, the edges of the hernia sac are approximated by sutures of Vycril® 2-0. Additional maneuvers are performed to increase the abdominal cavity. Among them the most common are: 1) rectus muscle relaxation maneuver (Gibbons technique) held sectioning both anterior sheath of the rectus muscles, and 2) section of the external oblique muscle aponeurosis along the lateral border of rectus muscle (changed Ramirez technique), both to the full extent of the hernia defect.

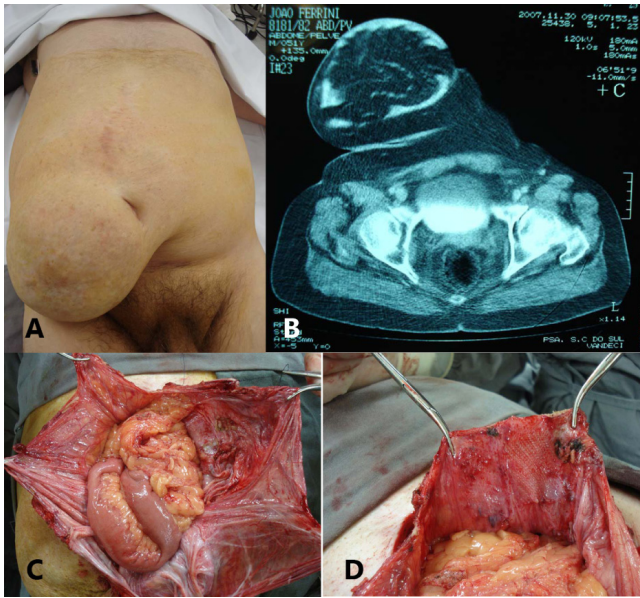
Whatever the maneuver adopted, the use of a prosthesis is most often compulsory. Preference is done to the polypropylene prosthesis (Marlex® or Prolene®) which are individually prepared. It is noted the length and width of the defect, and transfer these measurements to 20x30 or 30x30 cm prosthesis, which is sectioned rounding their edges. The outer edge of the aponeurosis (anterior lamina of the rectus sheath or external oblique aponeurosis) is dissected approximately 1 cm in all its extension to allow placement, under it, the prosthesis fixed with u shape Prolene® 2-0 or 3-0 sutures at intervals of about 3 cm. After that, there is a continuous suture with the same material (3-0) between the free edge of the aponeurosis and the prosthesis in all its perimeter, keeping the prosthesis stretched, but not tense. In addition, several sutures between the prosthesis and the underlying hernia sac (Figure 6A) is done. After correction the wound is washed with saline solution under pressure and redone the skin disinfection. In order to provide better accolade of the subcutaneous tissue to the wall, are given separate absorbable sutures in the middle portion of the flap and subcutaneous aponeurosis/prosthesis. Are placed routinely two closed suction drains (Porto-Vac®). In addition is made a sub-dermal suture. The skin is closed with continuous intradermal absorbable sutures (Monocryl® 4-0).

Drainage, usually serohematic, remains till it is high (100 to 150 ml), and withdrawn when it reduces to 20 or 30 ml, usually at 4 or 5 days postoperatively. The patient is discharged using a elastic strap.

### Complications

Recurrences may occur under the prosthesis, in most cases, when it was placed in an onlay way, set improperly and causing disruption with the intra-abdominal pressure producing marginal recurrence of the hernia (Figure 8). To eliminate this problem was adopted the technique fixing the prosthesis under the outer edge of the aponeurosis.





- A - Median HIA becoming evident to the right.  
 B - CT showing intestinal loops in the "second abdomen"  
 C - After opening the large peritoneal sac, there is small prosthesis on the medial side, still fixed on its edge  
 D - Detail showing the prosthesis coated by fibrous tissue

**FIGURE 6 – Re-recurrence under prosthesis**

Another side effect is infection that often promotes the total detachment of the prosthesis. To avoid this infectious complication, whether by rejection of the prosthesis or sutures abscesses in the previous correction, the new prosthesis approach should be done only after elimination of the prior infected process

## FINAL CONSIDERATIONS

The surgical correction of HIA in asymptomatic cases is controversial. However, it is known that over time, the usual tendency of incisional hernias is to progressively increase, leading also to higher complications (incarceration/strangulation, skin changes from ulcers to intestinal fistulization, loss of living standards with limited physical activity, and, why not, aesthetic effects often embarrassing), and more technical difficulties for its correction. In addition, early correction of HIA, especially when they are still small, and present better results, make the use of prostheses or be performed laparoscopically without the presence of skin deformities as those seen in large hernias. Moreover, despite the modern techniques with the use of prosthesis, there is a considerable number of re-recurrences, often motivated by complications resulting from their surgery.

Even the successful correction with the use of large prosthesis are not without drawbacks, the abdominal wall does not resume its normal elasticity and compliance. For this reason, it is important that

the patient be advised of the possibility of their expectations regarding the outcome, both aesthetic and functional, not be achieved.

These considerations call the attention to the importance of technical care in closing the laparotomy incisions, in the prevention of surgical wound infections, in care about the nutritional conditions and taking measures aimed to control the increase in intra-abdominal pressure, as the best prophylaxis of HIA.

## REFERÊNCIAS

- Bernard C, Polliand C, Mutelica L, Champault G – Repair of giant abdominal wall hernias using open intraperitoneal mesh. *Hernia* (2007) 11: 315-320.
- Birch DW – Characterizing laparoscopic incisional hernia repair. *Can J Surg* (2007) 50:195-201.
- Bisgaard T, Kehlet H, Bay-Nielsen MB, Iversen MG, Wara P, Rosenberg J, Friis-Andersen HF, Jorgensen LN – Nationwide study of early outcomes after incisional hernia repair. *Br J Surg* (2009) 96: 1452-1457.
- Brandolese R, Grigoletto R, Munegato G – The importance of measurement of respiratory mechanics during surgery of the abdominal wall. *Hernia* (2000) 4: 197-201.
- Burger JWA, Lange JF, Halm JA et al – Incisional hernia: early complication of abdominal surgery. *World J Surg* (2005) 29: 1608-1613.
- Cassar K, Munro A – Surgical treatment of incisional hernia. *Br J Surg* (2002) 89: 534-535.
- Chevreil JP, Rath AM – Classification of incisional hernias of the abdominal wall. *Hernia* (2000) 4: 7-11.
- Dumont F, Fuks D, Verhaeghe P et al. – Progressive pneumoperitoneum increases the length of abdominal muscles. *Hernia* (2009) 13: 183-187.
- Ellis H, Gajraj H, George CD – Incisional hernias: when do they occur? *Br J Surg* (1983) 70: 290-291.
- Espinosa-de-los-Monteros A, De la Torre JJ, Ahumada LA et al – Reconstruction of the abdominal wall for incisional hernia repair. *Am J Surg* (2006) 191: 173-177.
- Han JG, Ma SZ, Song JK, Wang ZJ – Operative treatment of ventral hernia using prosthetic materials. *Hernia* (2007) 11:419-423.
- Heniford BT, Park A, Ramshaw BJ, Voeller G – Laparoscopic repair of ventral hernias: nine years' experience with 850 consecutive hernias. *Ann Surg* (2003) 238: 391-399.
- Kingsnorth A – The management of incisional hernia. *Ann R Coll Surg Eng* (2006) 88: 252-260.
- Lechaux JP, Lechaux D, Chevreil JP – Traitement des éventrations de la paroi abdominale. Editions Techniques – Encycl Méd Chir (Paris-France), Techniques chirurgicales – Appareil digestif. 40-165, 2004, 14p.
- Lipman J, Medalie D, Rosen MJ – Staged repair of massive incisional hernias with loss of abdominal domain: a novel approach. *Am J Surg* (2008) 195: 84-88.
- Mayagoitia JC, Suárez D, Arenas JC, Díaz de Leon V – Preoperative progressive pneumoperitoneum in patients with abdominal-wall hernias. *Hernia* (2006) 10: 213-217.
- Munegato G, Grigoletto R, Brandolese R – Respiratory mechanics in abdominal compartment syndrome and large hernias of the abdominal wall. *Hernia* (2000) 4: 282-285.
- Muysoms FE, Miserez M, Berrevoet F et al – Classification of primary and incisional abdominal wall hernias. *Hernia* (2009) 13: 407-414.
- Nieuwenhuizen J, Kleinrensink GJ, Hop WCJ et al – Indications for incisional hernia repair: a international questionnaire among hernia surgeons. *Hernia* (2008) 12: 223-225.

20. Pollock AV, Evans M – Early prediction of late incisional hernias. *Br J Surg* (1989) 76: 953-954.
21. Raynor RW, Del Guercio LRM – The place for pneumoperitoneu in the repair of massive hernia. *World J Surg* (1898) 13: 581-585.
22. Read RC – Recurrent and incisional hernias. In: McQuarrie DG, Humphrey EW, Lee JT – *Reoperative General Surgery*. St Louis, Mosby 2nd ed 1997. Cap 28 pp 558-567.
23. Tanaka EY, Yoo JH, Rodrigues Jr AJ, Utiyama EM et al – A computerized tomography scan method for calculating the hernia sac and abdominal cavity volume in complex large incisional hernia with loss of domain. *Hernia* (2010) 14: 63-69.
24. Trivellini G, Bagni CM, Sollini A, Senni M, et al – Repair of giant hernias using more prosthesis. *Hernia* (2001) 5: 124-128.
25. Van Geffen Hendrikus JAAA, Simmermacher RKJ – Incisional hernia repair: abdominoplasty, tissue expansion and methods of augmentation. *World J Surg* (2005): 1080-1085.
26. Vidovic D, Jurisic D, Franjic BD et al – Factors affecting recurrence after incisional hernia repair. *Hernia* (2006) 10: 322-325.
27. Willis S, Shumpelick V – Use of pneumoperitoneum in the repair of giant hernias. *Hernia* (2000) 4: 105-111.