

## FIREARM INJURY PATIENTS WITH SITUS INVERSUS TOTALIS - CASE REPORT

*Tratamento cirúrgico em paciente com situs inversus totalis após ferimento por arma de fogo – relato de caso*

Jurandir Marcondes **RIBAS-FILHO**, Ivan **MALUF-JUNIOR**, Fernanda Marcondes **RIBAS**,  
Leticia Elizabeth Augustin **CZECZKO**, Igor Yudi **KURADOMI**, Eli Augusto **BADIA**

From Department of General Surgery, Evangelic University Hospital of Curitiba, Curitiba, PR, Brazil.

### Correspondence:

Jurandir Marcondes Ribas Filho, e-mail: ipem@evangelico.org.br

Financial source: none

Conflicts of interest: none

Received for publication: 12/06/2010

Accepted for publication: 15/03/2011

## CASE REPORT

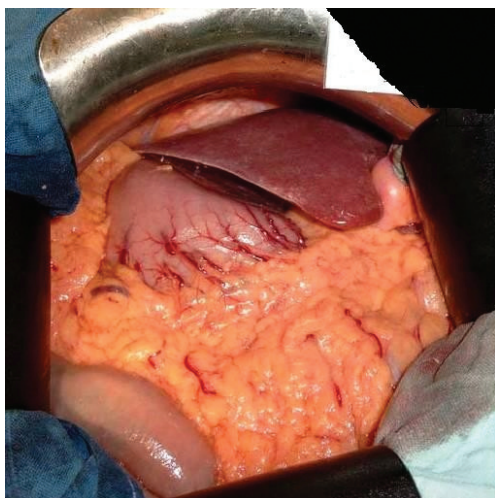
Man of 40 years suffered gunshot wounds in the thoracoabdominal transition with entrance hole in the right midaxillary line at the 10<sup>th</sup> intercostal space, without outlet.

On physical examination, patent airway, spontaneous ventilation wearing a neck collar on rigid board. Pulmonary auscultation presented vesicular murmur in the left hemithorax and decreased in the right lung base. Hemodynamically unstable. Had Glasgow coma scale 15 and pupils isochoric. The abdomen was distended with signs of peritoneal irritation. The patient had no other injury.

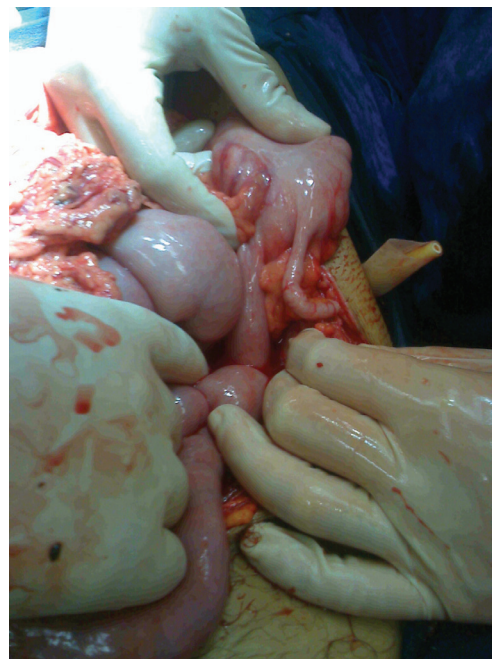
The initial procedure was fluid replacement, blood transfusion, bladder catheterization of delay-sealed tube drainage water to the right. Then, revealed presence of about 1000 mL of blood intra-cavity with lots of clots, visualization of situs inversus totalis (Figures 1 and 2), grade V splenic

## INTRODUCTION

**S**itus inversus is a rare congenital anomaly of reversal site of thoracic and abdominal organs<sup>3</sup>. It can be partial (only one cavity) or with total abdominal and thoracic organs affected<sup>1</sup>. The first case was described in 1600 by Fabricius<sup>2</sup>. Incidence of 1/10000-50000 live births. This anatomical anomaly does not affect survival and is not considered pre-malignant<sup>2,3</sup>. It is usually diagnosed incidentally with imaging. A few decades ago it had the diagnosis made only intraoperatively<sup>8</sup>. Surgical procedures are considered more difficult in patients with this condition by the anatomical difference and position of organs<sup>11,12</sup>.



**FIGURE 1** – Situs inversus: liver located in the left hypochondrium



**FIGURE 2** – Situs inversus: appendix located in the left iliac fossa

injury (Figure 3), gastric lesion grade III, grade II pancreatic injury, diaphragmatic injury grade II. The procedures were total splenectomy, gastrotomy, pancreatorrhy, diaphragmatic repairs cavity washing. He was discharged on the 8<sup>th</sup> day after surgery in good clinical condition.

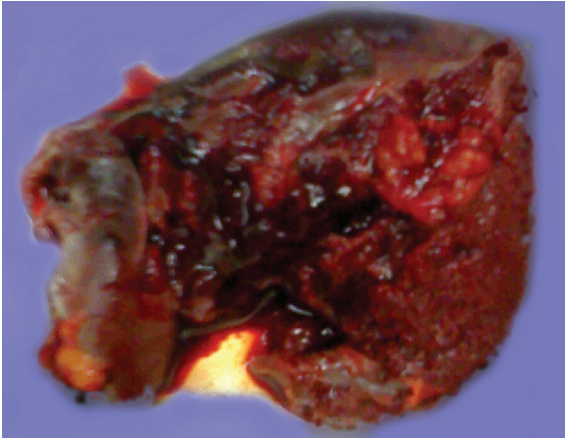


FIGURE 3 – Extensive splenic injury

## DISCUSSION

Penetrating abdominal trauma is associated with hemodynamic instability, immediate indication for laparotomy<sup>5,13</sup>. As in the case described, hemodynamically unstable patient had surgical indication without further investigation or examination<sup>6,10,14</sup> and no delay in trying to resuscitate the patient before the operation<sup>4,9,15</sup>.

Due to the complexity of vascular anomalies, situs inversus in the past was considered a contraindication to liver operations. The orientation of the hepatic vessels is reversed and the upper right quadrant contains the spleen and stomach making its handling technically difficult<sup>6</sup>. Several cases have been reported for elective operations such as laparoscopic cholecystectomy, even with success rates similar to the procedures in patients without situs inversus.

This condition can lead to some problems of orientation and dissection during the procedure, because at least two thirds of the surgeons are right-handed<sup>7</sup>. The total splenectomy procedures and primary suture of injury, in relation to the patient in

question, were carried out with relative difficulty, but without complications.

## CONCLUSION

Although the surgical procedures in patients with situs inversus have more complex situations, the operation can to be successfully performed even with extensive trauma.

## REFERENCES

1. Akbulut S, Caliskan A, Ekin A, Yagmur Y. Left-sided Acute Appendicitis with Situs Inversus Totalis: Review of 63 Published Cases and Report of Two Cases. *J Gastrointest Surg.* 2010 Jun 22.
2. Aydin U, Unalp O, Yazici P, Gurcu B, Sozbilen M, Coker A. Laparoscopic cholecystectomy in a patient with situs inversus totalis. *World J Gastroenterol.* 2006 Dec 21;12(47):7717-9.
3. Benjelloun el B, Zahid FE, Ousadden A, Mazaz K, Ait Taleb K. A case of gastric cancer associated to situs inversus totalis. *Cases J.* 2008 Dec 12;1(1):391.
4. Fujiwara Y, Fukunaga Y, Higashino M, Tanimura S, Takemura M, Tanaka Y, Osugi H. Laparoscopic hemicolectomy in a patient with situs inversus totalis. *World J Gastroenterol.* 2007 Oct 7;13(37):5035-7.
5. Haan J, Kole K, Brunetti A, Kramer M, Scalea TM. Nontherapeutic laparotomies revisited. *Am Surg.* 2003 Jul;69:562-5
6. Heimbach JK, Menon KV, Ishitani MB, Nyberg SL, Jankowski CJ, Lindor KD, Rosen CB. Living donor liver transplantation using a right lobe graft in an adult with situs inversus. *Liver Transpl.* 2005 Jan;11(1):111-3.
7. Hugh TB. New strategies to prevent laparoscopic bile duct injury—surgeons can learn from pilots. *Surgery.* 2002 Nov;132(5):826-35.
8. Israelit S, Brook OR, Nira BR, Guralnik L, Hershko D. Left-sided perforated acute appendicitis in an adult with midgut malrotation: the role of computed tomography. *Emerg Radiol.* 2009 May;16(3):217-8.
9. Leppaniemi A, Haapiainen R. Occult diaphragmatic injuries caused by stab wounds. *J Trauma.* 2003 Oct;55:646-50
10. Machado NO, Chopra P. Laparoscopic cholecystectomy in a patient with situs inversus totalis: feasibility and technical difficulties. *JSLS.* 2006 Jul-Sep;10(3):386-91.
11. Oms LM, Badia JM. Laparoscopic cholecystectomy in situs inversus totalis: The importance of being left-handed. *Surg Endosc.* 2003 Nov;17(11):1859-61.
12. Penetrating Abdominal Trauma: Guidelines for Evaluation. [www.trauma.org](http://www.trauma.org) Acesso em: August 09, 2004.
13. Renz BM, Feliciano D. The length of hospital stay after an unnecessary laparotomy for trauma: A prospective study. *J Trauma* 1996;40:187
14. Renz BM, Feliciano DV: Unnecessary laparotomy for trauma: A prospective study of morbidity. *J Trauma* 1995;38:350
15. Uludag M, Citgez B, Ozkurt H. Delayed small bowel perforation due to blunt abdominal trauma and periappendicitis in a patient with situs inversus totalis: a report of a case. *Acta Chir Belg* 2009;109(2):234–237.