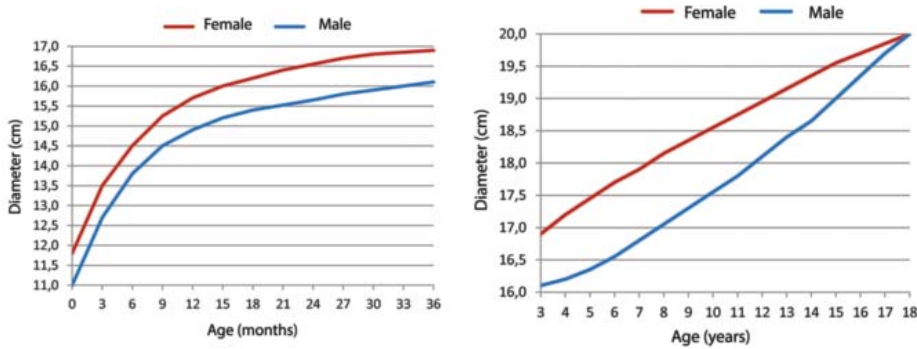


ERRATA

DOI: <http://dx.doi.org/10.1590/abd1806-4841.20132233e>

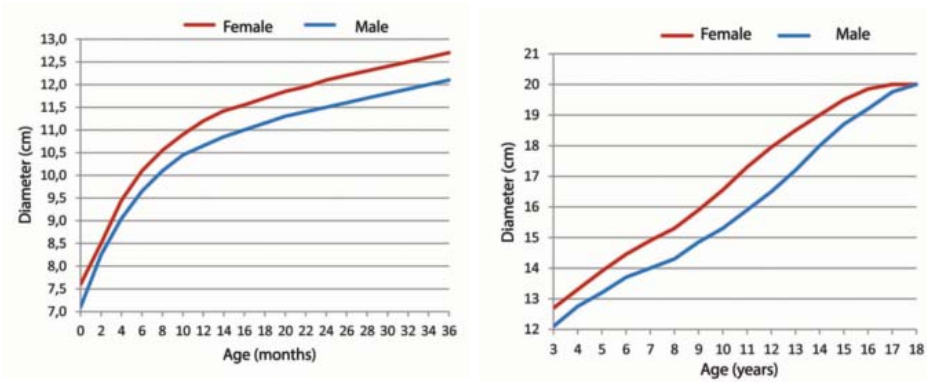
In the Continuing Medical Education article, Giant congenital melanocytic nevus, published in journal 88(6), the source of figures 4 and 5 was inadvertently left out. Below are the figures with their source.

FIGURE 4: Size of giant congenital melanocytic nevus located on the head, according to the age



Modified source: Dedavid *et al.*²⁸

FIGURE 5: Size of giant congenital melanocytic nevus located on the body, according to the age



Modified source: Dedavid *et al.*²⁸