

## Do you know this syndrome? \* Você conhece esta síndrome?

Lilian Mendes Ferreira Urbano <sup>1</sup>

Isabel Irene Ramos Leal <sup>2</sup>

Izelda Maria Carvalho Costa <sup>3</sup>

### CASE REPORT

The patient is an eighteen-year-old female born by cesarean section with multiple congenital malformations in Sao Luis - MA. She had omphalocele repair as a neonate and presents learning difficulty. She is the second daughter of a non-consanguineous couple with two children; the brother is healthy. Her mother reported three previous miscarriages. The patient displays body asymmetry, kyphoscoliosis, microcephaly, facial asymmetry, right-eyelid ptosis, left microphthalmia, low set ears, protruding ears and auricular cartilage thinning, thinning hair in the right frontoparietal area, dry and brittle hair. (Figure 1A) Erythematous plaque was present in the upper and lower lip, extending into the oral cavity, with a papillomatous aspect. (Figure 1B) The patient presented only eight teeth, some conical, and lower alveolar bone hypotrophy. Auscultation of the heart revealed systolic heart murmurs 3 + / 6 + in the accessory aortic focus. On the abdomen, she presented median xiphopubic surgical scar. An evaluation of the extremities showed hand asymmetric brachydactyly, digital clubbing, syndactyly of 2nd and 3rd, 4th and 5th right toes, syndactyly of 2nd and 3rd left toes and ectrodactyly of the 4th right toe. (Figures 1C and 1d) She was mixed-race

(pardo) and her skin had hypochromic atrophic papules that were confluent, forming dyschromic plaques with areas of brownish crusts and sagging skin on the face, neck, trunk, abdomen, upper and lower limbs following Blaschko lines. A skull radiograph showed a reduction of the craniofacial ratio with anteroposterior diameter, without signs of intracranial hypertension, orbital asymmetry, with reduction of the diameter of the left orbit, mandibular, maxillary and dental changes. A dorso-lumbar spine radiograph revealed left dorsolumbar convex scoliosis and dorsal kyphosis. Radiographs of the skeleton showed cross striations in the distal extremities of the bones of the forearms, femurs, tibiae and fibulae. (Figure 2A) Ultrasonography of the kidneys and urinary tract showed mild right calyceal and renal pelvis dilatation. Histopathology of the skin showed epidermal hyperkeratosis, acanthosis and hypergranulosis. The dermis revealed vessel proliferation, mononuclear inflammatory cell infiltrate, areas of fibrosis and subcutaneous tissue extending to the epidermis, showing a marked reduction in dermal thickness. (Figure 2B) The lip lesion was papillomatous with areas of parakeratosis.

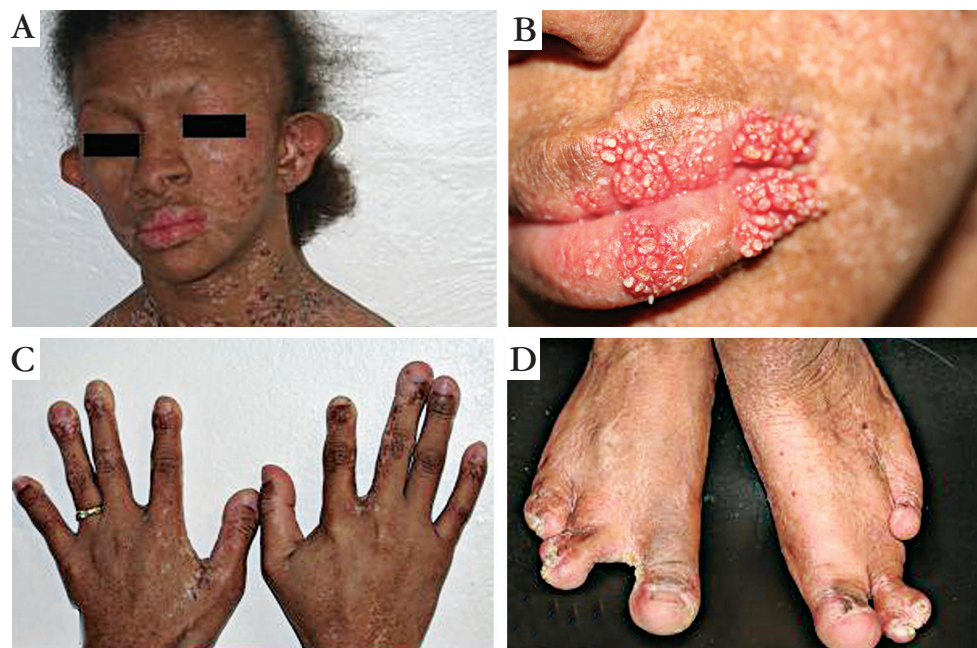

FIGURE 1: A. Cutaneous lesions following Blaschko lines B. Oral Papillomas; C. Asymmetric brachydactyly; D. Syndactyly and ectrodactyly

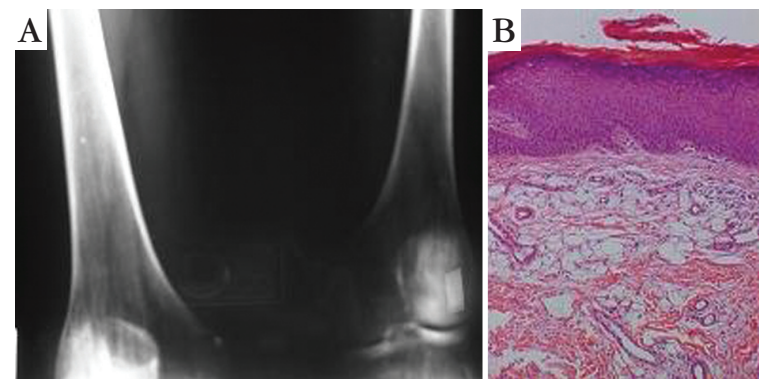


FIGURA 2: A. Osteopathia striata B. Histopathological exam of oral lesions. Papillomatous aspect with areas of parakeratosis

Approved by the Editorial Board and accepted for publication on 13.03.2010.

\* Work conducted at the University Hospital of Brasilia – University of Brasilia (HuB-UnB) – Brasilia (DF), Brazil.  
Conflito de interesse: Nenhum / *Conflict of interest: None*  
Suporte financeiro: Nenhum / *Financial funding: None*

<sup>1</sup> Volunteer physician at the outpatient clinic of dermatology at the University Hospital of Brasilia – University of Brasilia (HuB – UnB) - Brasilia (DF), Brazil.

<sup>2</sup> Pathologist – Preceptor of Medical Residency in Anatomic Pathology at the University Hospital of Brasilia - University of Brasilia (HuB – UnB) - Brasilia (DF), Brazil.

<sup>3</sup> PhD – Coordinator of the outpatient clinic of pediatric dermatology at the University Hospital of Brasilia (HuB) and Professor of Dermatology at the University Hospital of Brasilia (UnB) – Brasilia (DF), Brazil.

# Do you know this syndrome? \*

## Você conhece esta síndrome?

Urbano LMF, Leal IIR, Costa IMC

### DISCUSSION

The syndrome was first described in 1962 by Goltz. This is a rare genetic disease of X-linked dominant inheritance<sup>1-5</sup> more common in females, often leading to abortion of male fetuses. It affects all germ layers: ectoderm (skin and teeth), mesoderm (dermis and bones) and endoderm (oral cavity and larynx).<sup>2</sup> Approximately 200 cases are reported in the literature.<sup>6</sup> Etiopathogenic mechanisms of focal dermal hypoplasia are unknown. There is impairment of the growth potential of dermal fibroblasts, resulting in decreased production and defective formation of collagen fibers.<sup>2</sup> The molecular basis of GS is a mutation in the PORCN gene located on chromosome Xp11.23.<sup>7-9</sup> GS has a broad spectrum of possible clinical manifestations.<sup>1-8</sup> The main general characteristics are female gender, short stature, mental retardation, asymmetry of the face, trunk and extremities. Cutaneous abnormalities may be characterized by sparse, dry and brittle hair, areas of alopecia on the scalp, anogenital, periungual or perioral papillomas, linear areas of skin hypoplasia, resembling striae, telangiectasia, hypopigmentation or hyperpigmentation following Blaschko lines, subcutaneous herniation, unguis malformations and dystrophy.<sup>1-3</sup> Possible anomalies of soft tissues are protrusion and asymmetry of the ears, hypoplastic helix, umbilical hernia, omphalocele, abnormal kidney and ureter.<sup>5</sup> The oral and dental anomalies described are cleft lip, prognathism, microdontia, enamel defects, irregular spacing, retarded eruption, dental agenesis or dysplasia, gingivitis, median lingual cleft. The ocular anomalies are

strabismus, microphthalmia, aniridia, vitreous degeneration, colobomas of the pupil, retina, lens, and nystagmus.<sup>1</sup> Skeletal abnormalities are typically osteopathia striata, generalized osteoporosis, scoliosis, spina bifida, rudimentary tail, vertebral anomalies, clavicular deformities, hypoplasia or absence of fingers, syndactyly, arachnodactyly, anomalies of carpal, metacarpal, tarsal and metatarsals, fusion of phalanges.<sup>1,5</sup> The diagnosis is the sum of numerous clinical, radiological findings, and histopathological examinations of skin lesions.<sup>1</sup> In the clinical case under study, there are several different findings comprising the syndrome. The patient has birth defects of ectodermal, mesodermal and endodermal origin, which constitute focal dermal hypoplasia with herniated adipose tissue, oral papillomas, anomalies of the extremities including syndactyly, ectrodactyly and brachydactyly, microphthalmia, defects of dental and oral structures, osteopathia striata, asymmetry of the face and trunk, low-set ears, short stature and mild mental retardation. Differential diagnosis between GS and anhidrotic and hidrotic ectodermal dysplasia, EEC syndrome (ectrodactyly, ectodermal dysplasia, cleft lip and palate), pigmentary incontinence, and aplasia cutis congenita must be carried out.<sup>1</sup> The treatment consists of a genetic counseling, reconstructive surgery and multidisciplinary approach in order to improve the quality of life of these patients and provide them with a normal and productive life.<sup>3</sup> □

**Abstract:** Goltz syndrome is a rare genetic disease of X-linked dominant inheritance. It is more common in female patients and, in most cases, results in miscarriage of male fetuses. It has a broad scope of possible clinical manifestations. Its diagnosis consists of the sum of the many clinical, radiological and histopathological findings. The treatment options are genetic counseling, reconstructive surgery and multidisciplinary approach, aiming to improve quality of life and ensure a normal and productive life.

**Keywords:** Focal dermal hypoplasia; Genetic diseases, X-linked; Radiography

**Resumo:** A síndrome de Goltz é uma doença genética rara, de herança dominante ligada ao X, mais comum em doentes do sexo feminino e, na maioria das vezes, resulta no aborto dos fetos do sexo masculino. Tem um amplo espectro de manifestações clínicas possíveis. O diagnóstico consiste no somatório dos numerosos achados clínicos, radiológicos e histopatológicos. O tratamento é o aconselhamento genético, cirurgias reconstrutivas e abordagem multidisciplinar com objetivo de melhorar a qualidade de vida e garantir uma vida normal e produtiva.

**Palavras-chave:** Doenças genéticas ligadas ao cromossomo X; Hipoplasia dérmica focal; Radiografia

### REFERÊNCIAS

1. Maymi MA, Martín-García RF. Focal Dermal Hypoplasia with Unusual Cutaneous Features. *Pediatr Dermatol*. 2007;24:387-90.
2. del Carmen Boente M, Asial RA, Winik BC. Focal dermal hypoplasia: ultrastructural abnormalities of the connective tissue. *J Cutan Pathol*. 2007;34:181-7.
3. Sacoor MF, Motswaledi MH. Three cases of focal dermal hypoplasia (Goltz syndrome). *Clin Exp Dermatol*. 2005;30:35-7.
4. Balmer R, Cameron AC, Adès L, Aldred MJ. Enamel defects and Lyonization in focal dermal hypoplasia. *Oral Surg Oral Med Oral Pathol Oral Radiol Endod*. 2004;98:686-91.
5. Glória ER, Araújo MG, Valério FF. Hipoplasia dérmica focal - Descrição de um caso. *An Bras Dermatol*. 1987;62:9-14.
6. Riyaz N, Riyaz A, Chandran R, Rakesh SV. Focal Dermal Hypoplasia (Goltz Syndrome). *Indian J Dermatol Venereol Leprol*. 2005;7:279-81.
7. Paller AS. Wnt Signaling in Focal Dermal Hypoplasia. *Nat Genet*. 2007;39:820-1.
8. Clements SE. Importance of PORCN and Wnt signaling pathways in embryogenesis. *Am J Med Genet Part A*. 2009;149A:2050-1.
9. Banihashemi M, Yazdanpanah MJ, Pezeshkpoor F. A six year-old girl with several eskeletal deformities and cutaneous lesions. *Indian J Dermatol Venereol Leprol*. 2008;74:427-8.

ENDEREÇO PARA CORRESPONDÊNCIA / MAILING ADDRESS:  
*Lilian Mendes Ferreira Urbano*  
SQN 109, Bloco I, Apartamento 502, Asa Norte,  
70752-090 Brasília DF  
*lilianmf@bommail.com*

Como citar este artigo/How to cite this article: Urbano LMF, Leal IIR, Costa IMC. Você conhece esta síndrome? Hipoplasia dérmica focal (síndrome de Goltz). *An Bras Dermatol*. 2011;86(2):391-440.