

## Authors' contributions

Thiago Rubim Batista Bellott Nascimento: Design and planning of the study; drafting and editing of the manuscript; collection, analysis, and interpretation of data; intellectual participation in the propaedeutic and/or therapeutic conduct of the studied cases; critical review of the literature; critical review of the manuscript.

Flávio Barbosa Luz: Approval of the final version of the manuscript; effective participation in research orientation; critical review of the manuscript.

Rafael Brandão Varella: Approval of the final version of the manuscript; collection, analysis, and interpretation of data; critical review of the manuscript.

Mayra Carrijo Rochaël: Approval of the final version of the manuscript; effective participation in research orientation; critical review of the manuscript.

## Conflicts of interest

None declared.

## References

1. Wong HH, Wang J. Merkel cell carcinoma. *Arch Pathol Lab Med.* 2010;134:1711–6.
2. Feng H, Shuda M, Chang Y, Moore PS, et al. Clonal integration of a polyomavirus in human Merkel cell carcinoma. *Science.* 2008;319:1096–100.

3. Becker JC, Kauczok CS, Ugurel S, Eib S, Bröcker EB, Houben R. Merkel cell carcinoma: molecular pathogenesis, clinical features and therapy. *J Dtsch Dermatol Ges.* 2008;6:709–19.
4. Pang C, Sharma D, Sankar T. Spontaneous regression of Merkel cell carcinoma: A case report and review of the literature. *Int J Surg Case Rep.* 2015;7:104–8.
5. Walsh NM. Complete spontaneous regression of Merkel cell carcinoma (1986–2016): a 30-year perspective. *J Cutan Pathol.* 2016;43:1150–4.

Thiago Rubim Bellott <sup>a,\*</sup>, Flávio Barbosa Luz <sup>b</sup>, Rafael Brandão Varella <sup>c</sup>, Mayra Carrijo Rochaël <sup>a</sup>

<sup>a</sup> Department of Pathology, Universidade Federal Fluminense, Niterói, RJ, Brazil

<sup>b</sup> Department of Dermatology, Universidade Federal Fluminense, Niterói, RJ, Brazil

<sup>c</sup> Department of Microbiology and Parasitology, Universidade Federal Fluminense, Niterói, RJ, Brazil

Corresponding author.

E-mail: [thiagorbbn@gmail.com](mailto:thiagorbbn@gmail.com) (T.R. Bellott).

Received 5 March 2021; accepted 20 April 2021; Available online 9 December 2022

<https://doi.org/10.1016/j.abd.2021.04.018>

0365-0596/ © 2022 Sociedade Brasileira de Dermatologia.

Published by Elsevier España, S.L.U. This is an open access article under the CC BY license (<http://creativecommons.org/licenses/by/4.0/>).

## Successfully treatment of penile vitiligo patches and their sexual dysfunction consequences, by suction blister epidermal grafting<sup>☆</sup>



Dear Editor,

Vitiligo is a common pigmentary disease with many psychosocial consequences such as sexual dysfunction (SD). In the treatment of refractory vitiligo such as vitiligo lesions in glabrous areas, medical treatment is disappointing. In recent years' surgical interventions such as autologous non-cultured melanocyte grafting (ANCMG) and suction blister epidermal grafting (SBEG) were developed for the treatment of stable vitiligo.<sup>1,2</sup> But vitiligo patches on problematic-to-treat areas, such as male genital even with this method may be with poor outcomes.<sup>2,3</sup>

A 32-year-old male was presented with depigmented patches located on the glans penis and associated SD from 58 and 32 months ago respectively. Laboratory examination, including thyroid, showed no abnormal findings. The patient was married 6 years ago, but 28 months later suffered from SD, because he and his wife feared that vitiligo was contagious. He had been subjected to multiple treat-

ments including ANCMG by dermatology and Sexual Disorder Center (SDC) but had no appropriate treatment response. New lesions had not developed in the last 12 months.

We suggested SBEG because of problematic-to-treat areas and not responding to previous treatment. Firstly, anesthetized depigmented patches were abraded. The anterolateral of the leg consider a donor site and used funnel cylinder technique<sup>3</sup> is in order to harvest grafts. The harvested blister was detached; was then located over the recipient site.

We recommended partial bed rest for 7 days, being very careful when using the toilet, and avoidance of situations that induce penile erection. Complete repigmentation was achieved without any complication after 3 months (Figs. 1–3).

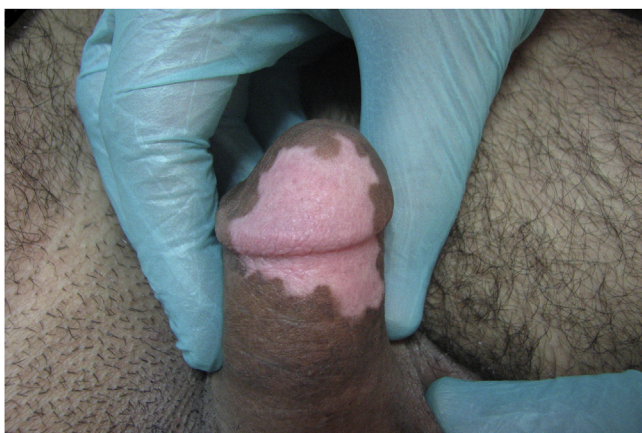
For the management of SD, we referred the patient to SDC. After 12 months, he presented with persistent repigmentation, improvement of SD and pregnancy of his wife.

Sukan and co-workers<sup>4</sup> demonstrated that chronic skin diseases such as vitiligo have undesirable influences on sexual activity. But other studies showed the presence or absence of genital vitiligo patches had not different effects on sexual functions.<sup>5</sup>

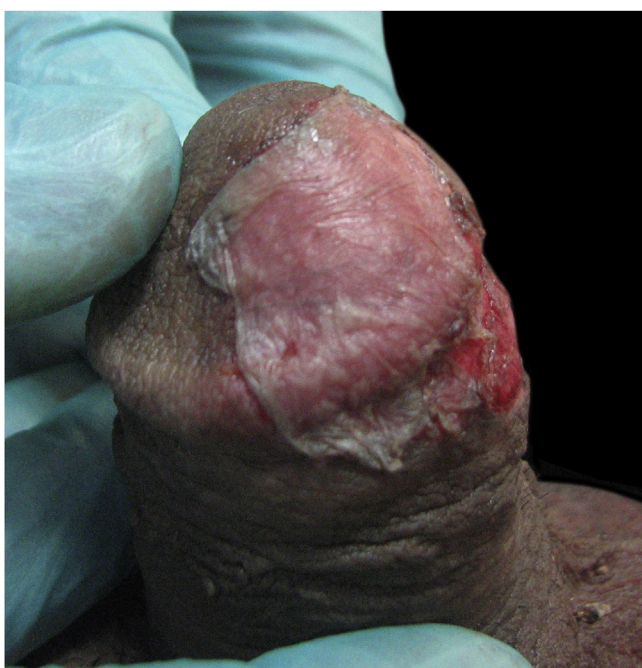It seems in our patient, SD was consequence of vitiligo, because of was absent of no abnormality finding throughout evaluations at SDC and was induced SD prior to vitiligo.

In limited studies with a few cases of genital vitiligo, that were treated by ANCMG, poor to good repigmentation outcome was obtained.<sup>1,3</sup>

<sup>☆</sup> Study conducted at the Hajdaie Dermatology Clinic, Kerman-shah, Iran.



**Figure 1** Penile vitiligo.



**Figure 2** Harvested epidermal graft located over the recipient abraded site.

We believe that the failure of surgical interventions in male genital is related to its mobility, change in size, erection, susceptibility to infection and care, especially during the toilet.

SBEG is an efficient method for the management of limited, stable, and resistant vitiligo with variable treatment results.<sup>2,3</sup> In the SBEG method, fixation of recipient sites is very important in order to achieve an optimal outcome.<sup>2</sup> It is very difficult to keep male genital in an immobility state.

In the literature review, our patient is the first case, that successfully improved both vitiligo patches and SD through SBEG. We suggest SBEG in stable vitiligo patches on male genital with its SD consequence.

This case report was approved by the Ethics Committee of Kermanshah University of Medical Sciences. The patient signed informed consent.



**Figure 3** Successful outcome of treated sites after 3 months.

### Financial support

None declared.

### Authors' contributions

Mahmoudreza Moradi: Study conception and planning; critical literature review.

Hossein Kavoussi: Approval of the final version of the manuscript; effective participation in research orientation; study conception and planning; manuscript critical review.

Reza Kavoussi: Intellectual participation in propaedeutic and/or therapeutic management of studied cases; preparation and writing of the manuscript.

### Conflicts of interest

None declared.

### References

1. Ramos MG, Ramos DG, Ramos CG. Evaluation of treatment response to autologous transplantation of noncultured melanocyte/keratinocyte cell suspension in patients with stable vitiligo. *An Bras Dermatol.* 2017;92:312–8.
2. Ebrahimi A, Radmanesh M, Kavoussi H. Recipient site preparation for epidermal graft in stable vitiligo by a special fraise. *An Bras Dermatol.* 2015;90:55–60.
3. Dellatorre G, Bertolini W, Castro CCS. Optimizing suction blister epidermal graft technique in the surgical treatment of vitiligo. *An Bras Dermatol.* 2017;92:888–90.
4. Sukan M, Maner F. The problems in sexual functions of vitiligo and chronic urticaria patients. *J Sex Marital Ther.* 2007;33:55–64.

5. Yucel D, Sener S, Turkmen D, Altunisik N, Sarac G, Cumurcu HB. Evaluation of the Dermatological Life Quality Index, sexual dysfunction and other psychiatric diseases in patients diagnosed with vitiligo with and without genital involvement. *Clin Exp Dermatol*. 2021;46:669–74.

Mahmoudreza Moradi<sup>a</sup>, Hossein Kavoussi<sup>b,\*</sup>, Reza Kavoussi<sup>a</sup>

<sup>a</sup> Kermanshah University of Medical Science, Kermanshah, Iran

<sup>b</sup> Hajdaie Dermatolgy Clinic, School of Medicine, Kermanshah University of Medical Sciences, Kermanshah, Iran

Corresponding author.

E-mail: [hkavoussi@gmail.com](mailto:hkavoussi@gmail.com), [hkawosi@kums.ac.ir](mailto:hkawosi@kums.ac.ir) (K. Hossein).

Received 14 April 2021; accepted 20 May 2021;

Available online 23 December 2022

<https://doi.org/10.1016/j.abd.2021.05.025>

0365-0596/ © 2022 Published by Elsevier España, S.L.U. on behalf of Sociedade Brasileira de Dermatologia. This is an open access article under the CC BY license (<http://creativecommons.org/licenses/by/4.0/>).

## Unilateral linear syringoma on the right chest and arm<sup>☆</sup>



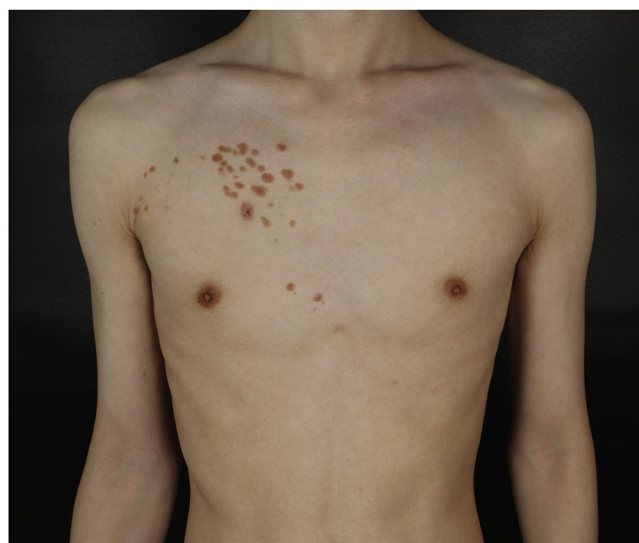Dear Editor,

A 25-year-old man presented to the dermatology department with an 8-year history of yellowish-brown skin lesions on his right chest, axilla, and arm. The lesions first appeared on the right chest and increased in number and size gradually, showing a linear distribution, with no pain or itching. He was otherwise healthy with no other special medical history. Physical examination revealed a yellowish-brown firm, smooth papules and plaques on his right chest, axilla, and arm, ranging from 1 to 10 mm in diameter (Figs. 1–4). The distribution of the lesions followed Blaschko's lines. Histopathology showed multiple small tubules, cysts, and nests forming by epithelial proliferation, with some of them morphologically like a comma or a tadpole, in the superficial dermis (Fig. 5). A diagnosis of sporadic linear syringoma was made. As it is a benign disease with no malignant potential, the patient has been followed up regularly without any treatment.

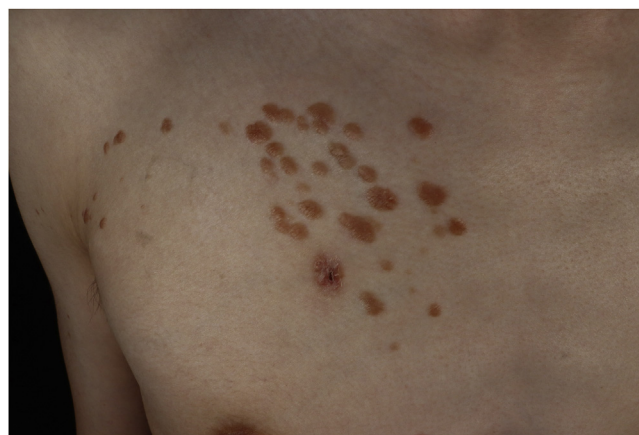### Discussion

Syringoma is a benign neoplasm that derives from eccrine sweat gland ducts. The typical clinical manifestation is single or multiple skin-color or yellowish papules on the lower eyelid, 1 to 3 mm in size. Friedman and Butler classified syringoma into 4 clinical variants: generalized forms, localized forms, familial forms and variants associated with Down's syndrome.<sup>1</sup> Differential diagnosis of syringoma based on a variety of clinical manifestations includes milia, xanthoma, hidrocystoma, trichoepithelioma, and flat warts, especially for the eyelids; other considerations include cutaneous mastocytosis, fibrofolliculomas, vellus hair cysts, angiofibroma, and fibroelastic papulosis, lichen planus, steatocystoma multiplex, eruptive vellus hair cysts, disseminated granuloma annulare, secondary

syphilis and so on.<sup>2,3</sup> Diagnosis can be confirmed by typical histopathologic manifestations.



**Fig. 1** Physical examination revealed yellowish-brown firm, smooth papules, and plaques on his right chest. Distribution of the lesions followed Blaschko's lines.



**Fig. 2** Closer look on the right chest. There is a wound after skin biopsy at the bottom.

<sup>☆</sup> Study conducted at the Department of Dermatology, the Fifth Affiliated Hospital of Sun Yat-sen University, Zhuhai (ZH), Guangdong (GD), China (CHN).