

We have no explanations for the association of serum UA levels with pain in LU; however, it is possible to hypothesize that an individual with higher levels of UA in the blood may also have higher UA levels in the ulcerated wound.

The association of UA with presence of fibrin was also observed. The accumulation of fibrin in tissues results from fibrinogen escape through capillary pores enlarged by increased local venous pressure. Burnand *et al.*<sup>5</sup> suggested that pericapillary fibrin affects the diffusion of oxygen and nutrients, favoring ischemia and impairing healing. Thus, it is possible to theorize that elevated levels of UA are associated not only with the presence of fibrin but also with oxygenation impairment and diminished healing. However, we have not been able to demonstrate this last hypothesis.

We conclude that UA levels are associated with pain severity and with the local formation of fibrin in LU, demonstrating that this radical is somehow involved in the pathophysiology of chronic ulcers. □

#### REFERENCES

1. Parker CN, Finlayson KJ, Shuter P, Edwards HE. Risk factors for delayed healing in venous leg ulcers: a review of the literature. *Int J Clin Pract.* 2015;69:967-77.
2. Fernandez ML, Upton Z, Shooter GK. Uric acid and xanthine oxidoreductase in wound healing. *Curr Rheumatol Rep.* 2014;16:396.
3. Fernandez ML, Upton Z, Edwards H, Finlayson K, Shooter GK. Elevated uric acid correlates with wound severity. *Int Wound J.* 2012;9:139-49.
4. Hoffmeister C, Trevisan G, Rossato MF, de Oliveira SM, Gomez MV, Ferreira J. Role of TRPV1 in nociception and edema induced by monosodium urate crystals in rats. *Pain.* 2011;152:1777-88.
5. Burnand KG, Whimster I, Naidoo A, Browse, NL. Pericapillary fibrin in the ulcer-bearing skin of the leg: the cause of lipodermatosclerosis and venous ulceration. *Br Med J (Clin Res Ed).* 1982;285:1071-2.

#### AUTHORS' CONTRIBUTIONS

Rodrigo Araldi Nery  ORCID 0000-0001-8805-983X

Approval of the final version of the manuscript, Elaboration and writing of the manuscript, Obtaining, analyzing and interpreting the data, Critical review of the literature, Critical review of the manuscript

Thelma Larocca Skare  ORCID 0000-0002-7699-3542

Statistical analysis, Approval of the final version of the manuscript, Conception and planning of the study, Elaboration and writing of the manuscript, Effective participation in research orientation, Critical review of the literature, Critical review of the manuscript

**How to cite this article:** Nery RA, Skare TL. Serum uric acid and leg ulcers. *An Bras Dermatol.* 2019;94(3):369-70.

## CASE LETTERS ▼

### Wells' syndrome: the importance of differential diagnosis\*

Lilian Geronimo Brasileiro<sup>1</sup>  
Marilda Aparecida Milanez Morgado de Abreu<sup>1</sup>  
Renato Soriani Paschoal<sup>2</sup>

DOI: <http://dx.doi.org/10.1590/abd1806-4841.20197840>

Dear Editor,

We describe three female patients with recurrent episodes of skin lesions that were diagnosed with Wells' syndrome (WS). The first case we report is a 37-year-old female patient that has presented with red, infiltrated, circular plaques with high and precise borders for the past two years. Some lesions show a central dissected blister, as well as erythematous maculas on the periphery; lesions are asymptomatic and located on the face and upper limbs (Figure 1). The episodes resolved spontaneously in approximately eight weeks and reoccurred, on average, every two months. The second case is a 34-year-old white woman who has shown recurrent erythematous-edematous plaques and papules with central desquamation for the last five years; the lesions first appeared after her first pregnancy. Initially, the lesions were limited to the left forearm, however they later affected the sternal region, being more intense in each crisis. The third case is a 42-year-old white female patient that has presented pruritic erythematous-edematous plaques with papules for 6 months in the cervical region and asymptomatic erythematous maculas on the left shoulder. (Figure 2). Peripheral eosinophilia was only observed in one patient. The anatomopathological findings of the three patients showed eosinophilic inflammatory infiltrate compatible with WS (Figure 3). In all three cases, treatment with oral steroids led to the disappearance of the lesions but relapses occurred after the drug was discontinued. Late diagnosis of WS is common,

Received 07 November 2017.

Accepted 07 August 2018.

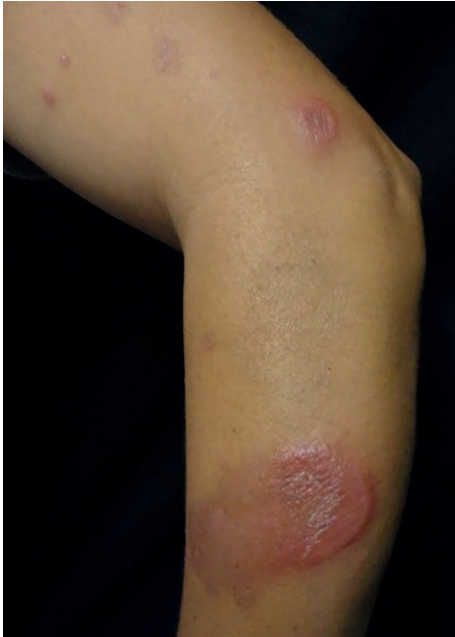\* Work conducted at the Hospital Regional de Presidente Prudente, Universidade do Oeste Paulista, Presidente Prudente (SP), Brazil. Financial support: None. Conflict of interest: None.

- 1 Dermatology Service, Hospital Regional de Presidente Prudente, Universidade do Oeste Paulista, Presidente Prudente (SP), Brazil.
- 2 RSP Dermatologia, Ribeirão Preto (SP), Brazil.

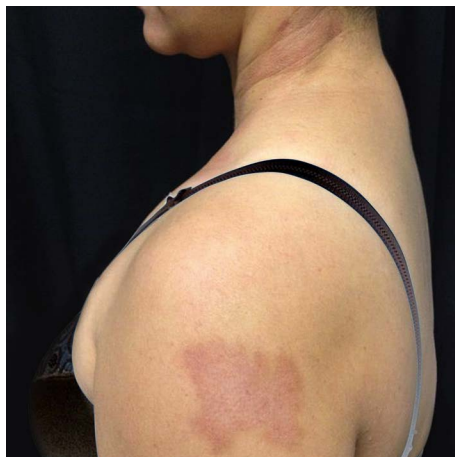MAILING ADDRESS:  
Lilian Geronimo Brasileiro  
E-mail: [dermatolilianbrasileiro@gmail.com](mailto:dermatolilianbrasileiro@gmail.com)

©2019 by Anais Brasileiros de Dermatologia

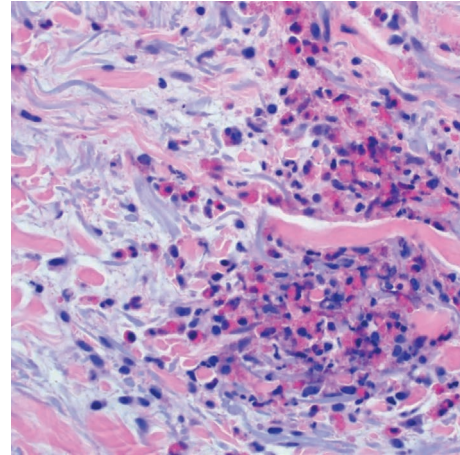




**FIGURE 1:** Erythematous-edematous plaques with high and precise borders in the upper limbs



**FIGURE 2:** Brownish-erythematous lesion in the left shoulder



**FIGURE 3:** Eosinophilic inflammatory infiltrate (Hematoxylin & eosin, x400)




mainly due to the polymorphism of cutaneous lesions and the absence of well-established diagnostic criteria and pathognomonic aspect. Thus, a wide range of differential diagnoses is possible, such as Sweet's syndrome, erythema multiforme, lupus erythematosus, and bacterial cellulitis.<sup>1,2</sup> The etiopathogenesis remains unknown but the hypothesis of type IV hypersensitivity reaction, sensitizing T lymphocytes, has been suggested.<sup>3</sup> Eosinophil, the main pathophysiological element, is believed to be cytotoxic and protein-secreting of cellular modulators, such as histamine, cationic proteins and free radicals. As a circulating cell, the eosinophil migrates to various tissues through chemotactic stimuli of T lymphocytes, keratinocytes, and mast cells. The involvement of interleukin (IL)-2 in the degranulation of eosinophils in patients with eosinophilia, such as SW, has been suggested. Eosinophils of these patients express the

IL-2 receptor  $\alpha$ -chain (CD25) and platelet-activating factor, thus IL-2 would stimulate the release of eosinophilic cationic protein from CD 25.<sup>2,4</sup> Eosinophils are activated by cytokines of type 2 helper (TH2) cells, which produce IL-4 and IL-5. IL-5 would attract eosinophils and regulate their adhesion molecules. CD4 + and CD7- circulating cells in patients with WS participate in the production of IL-5. An increase in the ratio of CD3 + and CD4 + suggests that activation of T cells is involved in the pathogenesis of WS. Systemic involvement is rare, but fever, malaise, and arthralgia are described. Clinically, the initial symptoms of the disease include ardent prodromes, mild pruritus, and the presence of well-defined annular or arcuate plaques, sometimes with a violet halo, erythematous nodules, infiltrates, vesicles, hemorrhagic blisters or hives. These lesions evolve rapidly during the first 2 - 3 days and then shrink, reducing the edema to a brownish-gray, residual, transient, sclerodermiform hyperpigmentation. The spontaneous resolution occurs in 4 to 8 weeks.<sup>1,2</sup> The predominant topographies are the lower limbs, followed by the upper limbs, trunk, face and neck.<sup>3</sup> In terms of histopathology, three stages are recognized. At first, there is dense dermal infiltrate, rich in eosinophils and extending up to the subcutaneous tissue. The second stage is characterized by the appearance of flame figures, which consist of a dense aggregate of adherent eosinophilic grains surrounding the collagen.<sup>5</sup> In the last stage, the flame figures are surrounded by histiocytes and multinucleated giant cells with a foreign body reaction arranged in palisade.<sup>5</sup> Although the flame figures are characteristic of WS, they are not pathognomonic as they may be present in insect bites, pemphigoid, mastocytoma, dermatophytosis, scabies, scurvy, and eczemas.<sup>1,2</sup> The therapy of choice is oral corticosteroid.<sup>2</sup> In cases where the drug is contraindicated or in cases of therapeutic failure, other options have been described, such as dapson, minocycline, tetracycline, antihistamines, griseofulvin, azathioprine, cyclosporine, mycophenolate mofetil, and anakinra.<sup>2</sup> WS seems to be a reactional cutaneous state to several stimuli, thus requiring research. Drug management is indicated, although spontaneous resolution of the condition may occur. □

## REFERENCES

- Haddad F, Helm TM. Wells syndrome. *Cutis*. 2014;93:38-9.
- Silva CMR, Ottoni FA, Andrade-Filho JS, Pena GPM, Gontijo JRV. Do you know this syndrome? *An Bras Dermatol*. 2007;82:575-8.
- Weins AB, Biedermann T, Weiss T, Weiss JM. Wells syndrome. *J Dtsch Dermatol Ges*. 2016;14:989-93.
- Rajpara A, Liolios A, Fraga G, Blackmon J. Recurrent paraneoplastic wells syndrome in a patient with metastatic renal cell cancer. *Dermatol Online J*. 2014;20. pii: 13030/qt35w8r1g3.
- Avelleira JCR, Viana FR, Boechat AM, Fleury RN. Well's syndrome or eosinophilic cellulitis. *An Bras Dermatol*. 1999;74: 53-7.

## AUTHORS' CONTRIBUTIONS

Lilian Geronimo Brasileiro	 ORCID	0000-0002-8300-3949
Conception and planning of the study, Elaboration and writing of the manuscript, Obtaining, analyzing and interpreting the data, Intellectual participation in propaedeutic and/or therapeutic conduct of the cases studied, Critical review of the literature		
Marilda Aparecida Milanez Morgado de Abreu	 ORCID	0000-0001-9099-6013
Approval of the final version of the manuscript, Intellectual participation in propaedeutic and/or therapeutic conduct of the cases studied, Critical review of the manuscript		
Renato Soriani Paschoal	 ORCID	0000-0003-0493-9966
Approval of the final version of the manuscript, Critical review of the manuscript		

**How to cite this article:** Zanoni LGB, Morgado de breu MAM, Paschoal RS. Wells' syndrome: the importance of differential diagnosis. *An Bras Dermatol*. 2019;94(3):370-2.



## Follicular *tinea faciei incognito*: the perfect simulator\*

Nelson Turra<sup>1</sup>  
 Jorge Navarrete<sup>1</sup>  
 Julio Magliano<sup>1</sup>  
 Carlos Bazzano<sup>1</sup>

DOI: <http://dx.doi.org/10.1590/abd1806-4841.20197892>

Dear Editor,

Tinea faciei is a relatively uncommon superficial dermatophyte infection limited to the glabrous skin of the face.<sup>1</sup> Studies define its classical presentation as single or multiple blemishes and circular erythematous-scaling patches with central clearing.<sup>2</sup> On the other hand, clinical manifestations are defined as atypical when the inflammatory component is more severe, presenting follicular papules and pustules.<sup>2</sup> When atypical clinical manifestations are present, the disease is known to mimic several disorders, such as cutaneous lupus erythematosus, rosacea, and granuloma annulare.<sup>1,3,4</sup> Additionally, treatment with corticosteroids makes its presentation incognito, becoming a great diagnostic challenge.<sup>5</sup> We report the case of a patient with follicular tinea faciei incognito, an atypical presentation of the disease, in which the diagnosis required a skin biopsy and successful treatment required the use of systemic antifungals.

A 31-year-old woman with no relevant medical history was referred to our university hospital with a facial dermatosis that compromised nose, cheeks, periocular region, and forehead. The lesion was characterized by an extensive erythematous and desquamative plaque of about 10 centimeters in diameter in which pustules were found in the central region and an inflammatory edge in the peripheral region (Figure 1). The lesion had appeared 4 months earlier, after the patient underwent a biopsy of a benign nasal nevus. The physical examination revealed no other remarkable findings and there was no evidence of tinea pedis or unguium. The lesion grew

Received 20 November 2017.

Accepted 04 August 2018.

\* Work performed at Dermatology Department "Prof. Dr. Miguel Martínez", Clinical Hospital "Dr. Manuel Quintela", Montevideo - Uruguay.  
 Financial support: None.  
 Conflict of interest: None.

<sup>1</sup> Dermatology Department, Clinical Hospital, School of Medicine, University of the Republic, Montevideo, Uruguay

MAILING ADDRESS:  
 Nelson Turra  
 E-mail: [nelsonturra85@gmail.com](mailto:nelsonturra85@gmail.com)

©2019 by Anais Brasileiros de Dermatologia

