

## Clouston syndrome associated with eccrine syringofibroadenoma\*

Ana Carolina Dias Viana de Andrade<sup>1</sup>  
Olga Maria Oiticica Harris<sup>3</sup>

Denise Cardoso Vieira<sup>2</sup>  
Matheus Melo Pithon<sup>1</sup>

DOI: <http://dx.doi.org/10.1590/abd1806-4841.20142837>

**Abstract:** Eccrine syringofibroadenoma is a rare benign neoplasia derived from acrosyringium cells of the eccrine sudoriferous glands. It affects the extremities of elderly individuals as solitary tumors, or may also present as multiple lesions. There are controversies about the pathogenesis and differentiation of the tumor. Eccrine syringofibroadenoma has been associated with subjacent conditions, such as for example, hypohidrotic ectodermic dysplasias. The authors describe a case report of a patient with Clouston Syndrome, who presented papules and nodules in extremities, clinically and histologically compatible with eccrine syringofibroadenoma. There are only three cases described in the literature, associated with Clouston Syndrome, and this is the fourth case.

**Keywords:** Dermatology; Ectodermal dysplasia; Keratoderma, palmoplantar

### INTRODUCTION

Congenital hypohidrotic ectodermal dysplasia, also known as Clouston Syndrome, is a rare autosomal dominant genodermatosis characterized by nail dystrophy, alopecia and palmoplantar hyperkeratosis.<sup>1</sup>

Eccrine syringofibroadenoma (ESFA) is a rare neoplasm, that originates from acrosyringium cells of the eccrine sudoriferous glands. It was described in 1963 by Mascaro, being classified as a hamartoma. Clinical presentation is variable, non-specific, varying from single lesions on extremities of the elderly to papules and nodules.<sup>2</sup>

When multiple, ESFA may be associated with diabetes mellitus or hypohidrotic ectodermal dysplasias. Clouston syndrome associated with ESFA was described in only 3 previous cases.<sup>3,4</sup> Therefore the authors' proposal is to describe a clinical case of ESFA in a patient carrying Clouston syndrome.

### CASE REPORT

Female patient, 41 years old, of mixed race, from Tremedal, Bahia, came to the dermatology ambulatory reporting that since birth she had not had hair anywhere in her body besides nail dystrophy and palmoplantar hyperkeratosis (Figures 1 and 2). She denied previous history of cutaneous neoplasms, den-

tal abnormalities, intolerance to heat or other significant medical problems and also informed that two of her siblings presented similar symptoms.

She reports that for 10 years coalescent papules and nodules of pinkish color, verrucous aspect appeared on her feet and hands, growing in number and size with time. She denied pain, burning sensation or bleeding at the site of the cutaneous lesions.

During physical examination the presence of coalescent pinkish papules was noticed, forming plaques with cobblestone aspect on the feet, besides alopecia and nail dystrophy. Laboratory exams were normal. The possible differential diagnoses of cutaneous lesions included diffuse eccrine poromatosis, plane warts, Clouston Syndrome, pachyonychia congenita and other forms of ectodermal dysplasias (Figure 3).

An incisional biopsy of the right foot lesion was performed, which revealed thin cords of anastomosed epithelial cells in continuity with the epidermis. The cords were composed of round and oval nucleated cells. Luminal structures which varied in size were also found, whose walls contained a single layer of cells. These findings were compatible with the diagnosis of ESFA (Figure 4). PCR for HPV 10 was negative.

Received on 01.06.2013.

Approved by the Advisory Board and accepted for publication on 14.08.2013.

\* Work performed at Universidade Estadual do Sudoeste da Bahia (UESB) – Jequié (BA), Brazil.

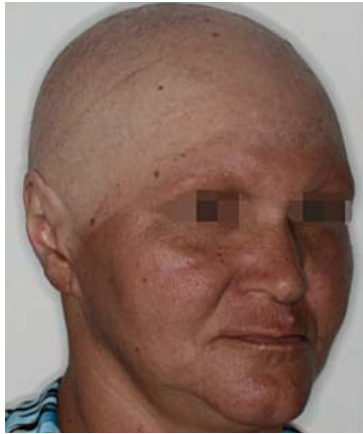Conflict of interest: None

Financial funding: None

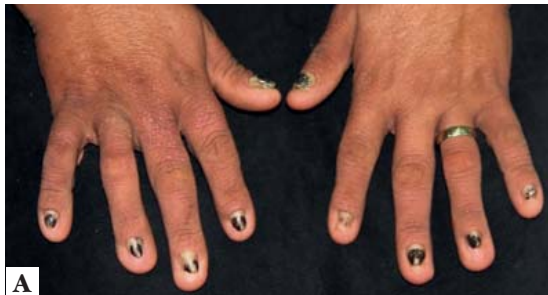<sup>1</sup> Universidade Estadual do Sudoeste da Bahia (UESB) – Jequié (BA), Brazil.

<sup>2</sup> Centro Municipal de Atenção Especializada (Cema) – Vitória da Conquista (BA), Brazil.

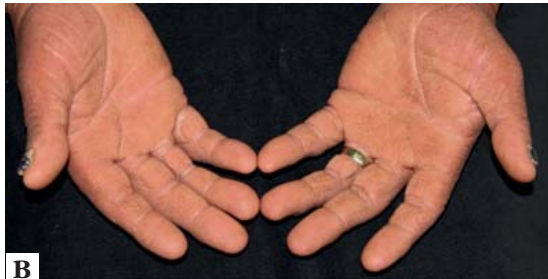<sup>3</sup> Universidade Federal do Rio de Janeiro (UFRJ) – Rio de Janeiro, Brazil.



**FIGURE 1:** Clinical aspect of alopecia

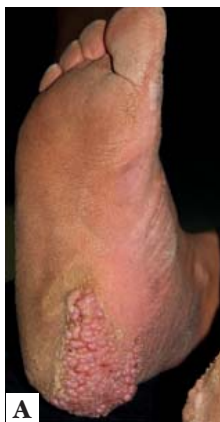

**A**

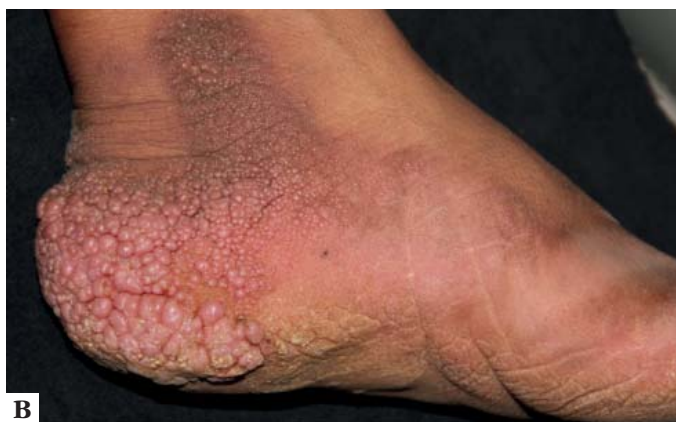

**B**

**FIGURE 2:** A. clinical aspect of nail dystrophy; B. clinical aspect of palmar hyperkeratosis

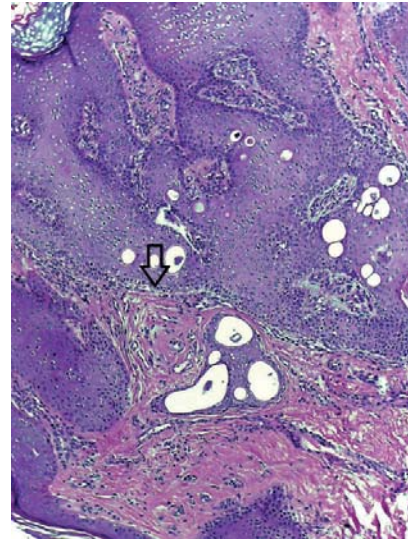


**A**



**B**

**FIGURE 3:** A. Clinical aspect of lesions demonstrating coalescent pinkish papules forming plaques with cobblestone aspect on feet; B. Clinical aspect of lesions demonstrating coalescent pinkish papules forming plaques with cobblestone aspect on feet



**FIGURE 4:** Histopathological exam revealing thin cords of anastomosed epithelial cells in continuity with the epidermis. Cords composed of round nucleated cells, luminal structures which vary in size and walls with a single layer of cells. (HE, 40X)

## DISCUSSION

ESFA was described in 1963 by Mascaro as a rare benign cutaneous disorder with eccrine differentiation.<sup>5</sup> It is characterized by the presence of anastomoses of thin epithelial cell cords embedded in a fibrovascular stroma.<sup>6</sup> Clinical presentation varies from solitary lesions to multiple papules, nodules and plaques. Although it occurs more frequently between the seventh and eighth decades of life, it can occur in younger patients.<sup>4</sup> Complications include an association with Squamous Cell Carcinoma and malignant transformation into eccrine syringofibrosarcoma.<sup>7</sup> There are several etiological factors associated with the development of syringofibroadenoma, among them the HPV type 10.<sup>3</sup> This type of tumor may appear in patients with Clouston syndrome, but it is a rare event, with only 3 cases described in the literature.<sup>4</sup>

Ectodermal dysplasias are heterogeneous, hereditary disorders, characterized by hindered development of epidermal appendages, which involve one or more of the following tissues: hair, teeth, nails or sweat glands. More than 170 syndromes have been characterized; of such, 30 were evaluated at the molecular level with identification of the causing gene. Clouston syndrome is an ectodermal dysplasia caused by mutations in the connexin gene, autosomal dominant, with no sex differences.<sup>8</sup> The clinical characteris-

tics of this syndrome include nail dystrophy, alopecia and palmoplantar hyperkeratosis. Although the association of this syndrome with ESFA has been described, it is rare.

In a study with 45 individuals affected by Clouston syndrome, none of them was identified as presenting ESFA, emphasizing the relative rarity of this clinical phenomenon.<sup>9</sup>

In the present case, the exuberance and rarity of cutaneous lesions were the reasons for its description. □

#### ERRATUM

The wrong DOI was published for the article "Clouston syndrome associated with eccrine syringofibroadenoma", in the edition: v. 89, n. 3, p. 504-6.

The correct DOI for this article is: DOI: <http://dx.doi.org/10.1590/abd1806-4841.20142837>

#### REFERENCES

- Melkote S, Dhurat RS, Palav A, Jerajani HR. Alopecia in congenital hidrotic ectodermal dysplasia responding to treatment with a combination of topical minoxidil and tretinoin. *Int J Dermatol*. 2009;48:184-5.
- Tey HL, Chong WS, Wong SN. Leprosy-associated eccrine syringofibroadenoma of Mascaro. *Clin Exp Dermatol*. 2007;32:533-5.
- Carlson JA, Rohwedder A, Daulat S, Schwartz J, Schaller J. Detection of human papillomavirus type 10 DNA in eccrine syringofibroadenomatosis occurring in Clouston's syndrome. *J Am Acad Dermatol*. 1999;40:259-62.
- Poonawalla T, Xia L, Patten S, Stratman EJ. Clouston syndrome and eccrine syringofibroadenomas. *Am J Dermatopathol*. 2009;31:157-61.
- Mascaro JM. Considerations sur les tumeurs fibro-epitheliales. Le syringofibroadenome eccrine. *Ann Dermatol Syphiligr* 1963;90:146-53.
- Takeda H, Mitsuhashi Y, Hayashi M, Kondo S. Eccrine syringofibroadenoma: case report and review of the literature. *J Eur Acad Dermatol Venereol*. 2001;15:147-9.
- Schadt CR, Boyd AS. Eccrine syringofibroadenoma with co-existent squamous cell carcinoma. *J Cutan Pathol*. 2007;34:71-4.
- Lamartine J. Towards a new classification of ectodermal dysplasias. *Clin Exp Dermatol*. 2003;28:351-5.
- Kibar Z, Der Kaloustian VM, Brais B, Hani V, Fraser FC, Rouleau GA. The gene responsible for Clouston hidrotic ectodermal dysplasia maps to the pericentromeric region of chromosome 13q. *Hum Mol Genet*. 1996;5:543-7.

#### MAILING ADDRESS:

Matheus Melo Pithon  
 Av. Otávio Santos, 395, sala 705  
 Centro Odontomédico Dr. Altamirando da Costa Lima  
 Bairro Recreio  
 45020-750 - Vitória da Conquista - BA  
 Brazil  
 E-mail: [matheuspithon@gmail.com](mailto:matheuspithon@gmail.com)

How to cite this article: Andrade ACDV, Vieira DC, Harris OMO, Pithon MM. Clouston syndrome associated with eccrine syringofibroadenoma. *An Bras Dermatol*. 2014;89(3):504-6.