

## LETTER - THERAPY

### Darier's disease: treatment with topical sodium diclofenac 3% gel<sup>☆</sup>

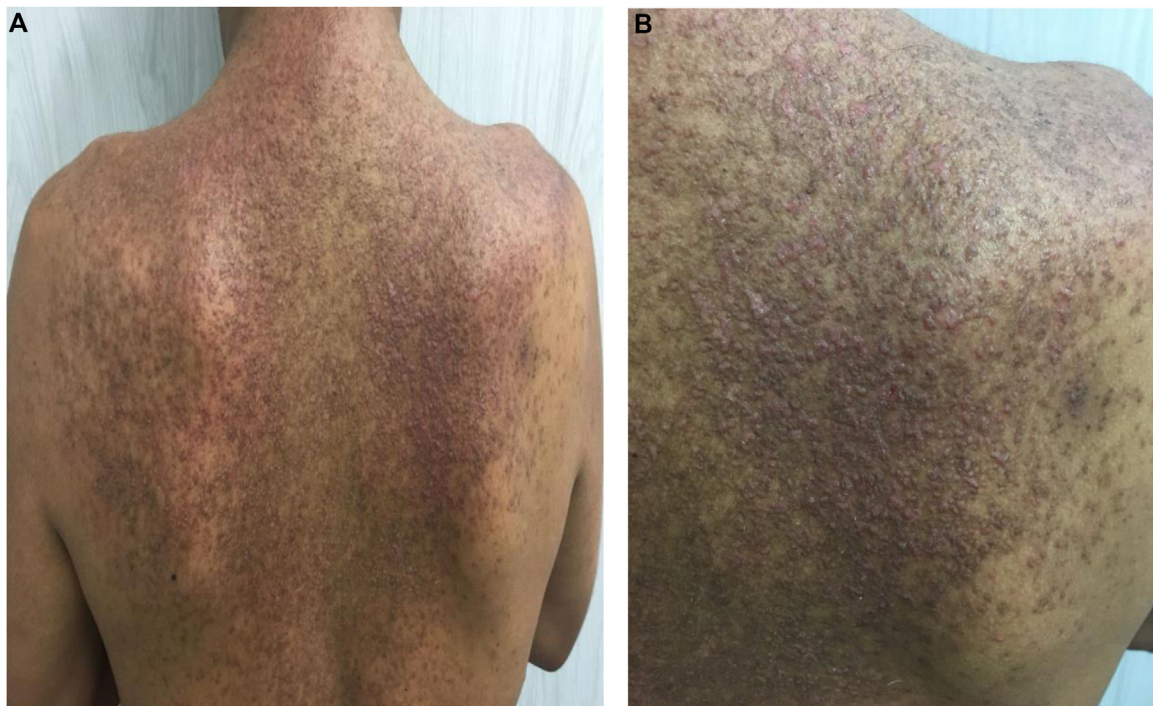


Dear Editor,

A 32-year-old male patient came to the authors outpatient clinic with a previous history of epilepsy and cognitive impairment, using carbamazepine and a clinical and histopathological diagnosis of Darier's disease for eight years. On physical examination, he had multiple erythematous-brown, keratotic papules, some of them crusted, located on the dorsal region, shoulders and anterior thorax (Fig. 1). He had previously used topical keratolytics, corticosteroids and retinoids, in addition to systemic anti-

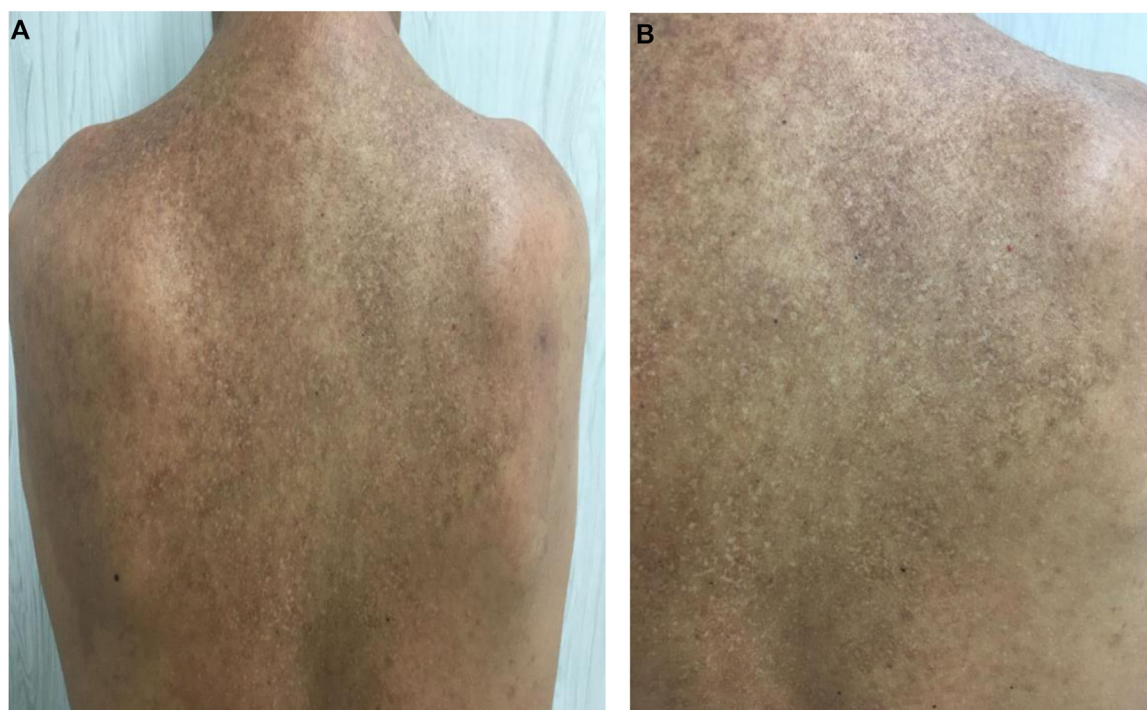
otics, without achieving lesion control. Systemic retinoids were avoided due to possible drug interactions (carbamazepine).

After reviewing the literature, the authors found some reports on the use of topical sodium diclofenac in Darier's disease. They chose to start with 3% sodium diclofenac and 2.5% hyaluronic acid in natrosol gel, applied twice a day only on the affected areas on the left side of the body, for eight weeks. After significant improvement of the lesions, the patient was instructed to apply it on all affected areas, twice a day. He denied local or systemic adverse reactions during medication use and no laboratory changes were observed during this period. After four months of treatment, he showed significant lesion regression, with post-inflammatory hypo- and hyperchromic macules and the presence of a few residual keratotic papules (Fig. 2). Medi-



**Figure 1** (A) Dorsal region – before treatment. (B) Right scapular region, before treatment

<sup>☆</sup> Study conducted at the General Outpatient Clinic of the Dermatology Service, Hospital Federal dos Servidores do Estado do Rio de Janeiro, Rio de Janeiro, RJ, Brazil.



**Figure 2** (A) Dorsal region, four months after starting treatment. (B) Detail of the dorsal region, right scapular region after treatment

cation use was reduced to once a day for another four weeks and the treatment was discontinued, with good clinical control maintained since then.

Darier's disease occurs due to a mutation in the ATP2A2 gene, which encodes a protein involved in epidermal differentiation and intercellular communication called SERCA2B, leading to impaired SERCA21 function.<sup>1,2</sup> It manifests as erythematous-brown, keratotic-crusted papules, in seboreic areas of the trunk, scalp, face, and neck associated with a foul odor and pruritus.<sup>1</sup> Ungual changes may also be observed, such as erythematous and white longitudinal bands, longitudinal fissures, subungual keratosis, and brittleness, forming 'V'-shaped notches.<sup>1</sup>

Treatment of Darier's disease includes general measures such as wearing light clothing and sunscreen protection; use of topical medications, such as keratolytics, corticoids, retinoids, tacrolimus, and 5-fluorouracil; and systemic drugs such as acitretin, isotretinoin, or cyclosporine. Surgical and photodynamic therapy can also be performed.<sup>1</sup>

Sodium diclofenac 3% was recently described as a therapeutic option in Darier's disease.<sup>2–4</sup> Its mechanism of action occurs by inhibiting cyclooxygenase-2, resulting in the suppression of prostaglandin E2 activity, which in turn downregulates the ATP2A2 gene. This leads to the normalization of SERCA2 levels in keratinocytes.<sup>1</sup> Its use is combined with hyaluronic acid 2.5%, which acts by maintaining the drug on the epidermis and superficial dermis, with better local action and less systemic absorption.<sup>5</sup>

### Financial support

None declared.

### Authors' contributions

Marcella Oliveira Menezes Quitete de Campos: Drafting and editing of the manuscript; critical review of the literature.

Giovanna Abrantes Pimenta de Figueiredo: Drafting and editing of the manuscript; critical review of the literature.

Allyson Capobiango Evangelista: Drafting and editing of the manuscript; critical review of the literature.

Alexander Richard Bauk: Approval of the final version of the manuscript; design and planning of the case report; effective participation in research orientation; intellectual participation in the propaedeutic and/or therapeutic conduct of the studied cases; critical review of the literature; critical review of the manuscript.




### Conflicts of interest

None declared.

### References

1. Kamijo M, Nishiyama C, Takagi A, Nakano N, Hara M, Ikeda S, et al. Cyclooxygenase-2 inhibition restores ultraviolet B-induced downregulation of ATP2A2/SERCA2 in keratinocytes: possible therapeutic approach of cyclooxygenase-2 inhibition for treatment of Darier disease. *Br J Dermatol.* 2011;166:1017–22.
2. Millan-Parrilla F, Rodrigo-Nicolas B, Moles-Poveda P, Armengot-Carbo M, Quecedo-Estebanez E, Gimeno-Carpio E. Improvement of Darier disease with diclofenac sodium 3% gel. *J Am Acad Dermatol.* 2014;70:89–90.
3. Santos-Alarcon S, Sanchis-Sanchez C, Mateu-Puchades A. Diclofenac sodium 3% gel for Darier's disease treatment. *Dermatol Online J.* 2016;22:17–20.

4. Palacios-Alvarez I, Andres-Ramos I, Silva MY, Simal G. Treatment of Darier's disease with diclofenac sodium 3% gel. *Dermatol Ther.* 2017;30:1-3.
5. Nelson CG. Diclofenac gel in the treatment of actinic keratosis. *Ther Clin Risk Manag.* 2011;7:207-11.

Marcella Oliveira Menezes Quitete de Campos \*,  
Giovanna Abrantes Pimenta de Figueiredo ,  
Allyson Capobianco Evangelista ,  
Alexander Richard Bauk 

Department of Dermatology, Hospital Federal dos Servidores do Estado do Rio de Janeiro, Rio de Janeiro, RJ, Brazil

\* Corresponding author.

E-mail: [marcellamqcampos@gmail.com](mailto:marcellamqcampos@gmail.com) (M.O. Campos).

Received 29 December 2021; accepted 31 January 2022

Available online 29 June 2023

<https://doi.org/10.1016/j.abd.2022.01.019>

0365-0596/ © 2023 Sociedade Brasileira de Dermatologia.

Published by Elsevier España, S.L.U. This is an open access article under the CC BY license (<http://creativecommons.org/licenses/by/4.0/>).

## Pityriasis rubra pilaris induced by topical use of imiquimod 5%<sup>☆</sup>



Dear Editor,

Pityriasis rubra pilaris (PRP) is a rare papulosquamous inflammatory dermatosis whose pathogenesis remains unclear, it is accepted that some drugs may be involved.<sup>1</sup> Four cases of PRP triggered by imiquimod have been previously reported.<sup>2-5</sup>

A 67-year-old male with no relevant medical history presented multiple actinic keratosis on the chest. Imiquimod 5% cream was prescribed three times per week. During the fourth week of treatment, the patient developed painful, erythematous lesions at the site of application, so treatment with topical corticosteroid was started and imiquimod was suspended. Nonetheless, there was a worsening of the eruption, developing follicular papules with extensive coalescence, salmon colored, with superficial desquamation. It expanded with craniocaudal sense, involving the rest of the body with islands of sparing (Fig. 1). He also showed palmo-plantar keratoderma (Fig. 2). He presented with flu-like symptoms such as myalgia and fever. Blood tests were within the normal range. A biopsy was performed revealing psoriasiform acanthosis, follicular plugging with parakeratosis at the edges of the follicular orifice, and marked acantholysis in multiple areas. Immunofluorescence studies were negative. Clinical-histopathological diagnosis of PRP was made. He denied any symptoms suggesting the current condition, so the etiology of the ongoing process was attributed to the treatment with Imiquimod. Oral acitretin was introduced at a dose of 50 mg per day achieving a maintained response after five months of follow-up.

PRP is a keratinization disorder, whose pathogenesis remains unclear. It has been postulated that it could be an exacerbated immune response to antigenic triggers. The

T-Helper1 (Th1) pathway is activated, causing altered signaling of retinoid keratinocyte receptors, blocking the vitamin A action, and developing a keratinization disorder.<sup>2</sup>

Imiquimod is a topical treatment approved for many tumoral and viral diseases. It is an immune response stimulating agent, binding to Toll-Like Receptor (TLR)-7, which activates the Th1 pathway, resulting in a proinflammatory cascade, as it occurs in PRP.<sup>3</sup>

Four more cases of PRP induced by imiquimod with some features in common (Table 1) have been reported. It is remarkable that all of them showed acantholysis in light microscopy,<sup>2-5</sup> while it has been described in approximately only 30% of PRP biopsies in previous studies.<sup>1</sup> Imiquimod has been previously reported to be involved in developing acantholytic alterations with negative direct immunofluorescence studies. It has been proposed that acantholysis could be a result of the increased levels of proinflammatory cytokines induced by imiquimod.<sup>4</sup> Also, it should be pointed out that most of the patients presented systemic symptoms.<sup>5</sup> Most of them showed an excellent response to conventional treatments, assuming imiquimod-induced PRP is likely to have a favorable prognosis.<sup>2-5</sup>

Other inflammatory dermatoses that can be developed or exacerbated with topical use of imiquimod have been reported, such as psoriasiform eruptions, pemphigus-like lesions, erythema multiforme, subacute lupus, lichen planus, and vitiligo-like depigmentation.<sup>2</sup> Thus, the systemic proinflammatory role of imiquimod seems to be reinforced.

Imiquimod, as an immune response stimulating treatment, could have a systemic effect, increasing the levels of proinflammatory cytokines and Th1 response and resulting in the developing PRP. Nevertheless, we should consider imiquimod as a useful treatment for many dermatological diseases, but we should be aware of the risk of onset and exacerbation of inflammatory dermatoses.

<sup>☆</sup> Study conducted at the Department of Dermatology, Hospital Universitario Sagrat Cor, Grupo Quirónsalud, Barcelona, Spain.