

Case for diagnosis

Caso para diagnóstico

Jonas Ribas¹

Carla Barros da Rocha Ribas³

Antonio Pedro Mendes Schettini²

Clarisse de Albuquerque Corrêa⁴

HISTORY OF THE DISEASE

ECSS, an 18-year old female born and living in Manaus in the Brazilian state of Amazonas presented with a single, well-defined erythematous, desquamative plaque with a maximum diameter of 4 cm, situated in the abdominal region, which had been present for the past year (Figure 1). The patient stated that she had not used any medication previously. A skin biopsy was performed for diagnostic evaluation.

At histopathology, the hematoxylin-eosin-stained sections showed the presence of a group of mononuclear cells containing atypical lymphocytes and mild spongiosis. In the papillary dermis an infiltrate of perivascular lymphoid cells was found reaching the epidermis. No further alterations were identified in the rest of the dermis or hypodermis (Figures 2 and 3). The paraffin block was sent for immunohistochemical evaluation, which showed that the majority of the lymphoid cells present were CD3-positive in addition to being CD20 negative; CD45RO-positive; CD30-negative; and AE1/AE3-negative. The set of histopathological and immunohistochemical findings were conclusive for a diagnosis of unilesional mycosis fungoides.

The patient was submitted to laboratory evaluation (full blood count, glucose and clinical chemistry) and systemic evaluation (chest x-ray, bone x-ray, a magnetic resonance imaging scan of the head and computed tomography). No abnormalities were found.

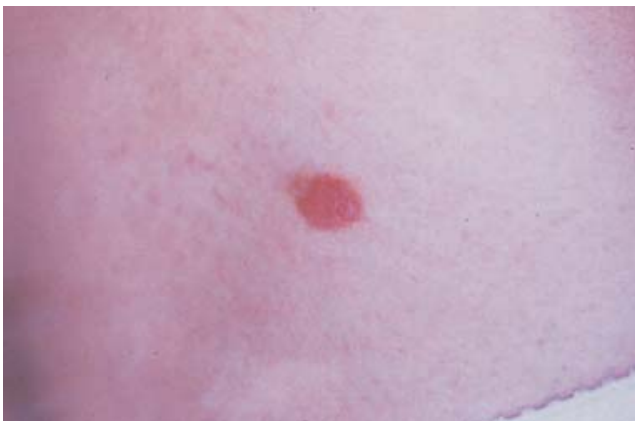

FIGURA 1: Placa eritemato-descamativa, única, bem delimitada, com 4 cm de diâmetro, localizada na região abdominal

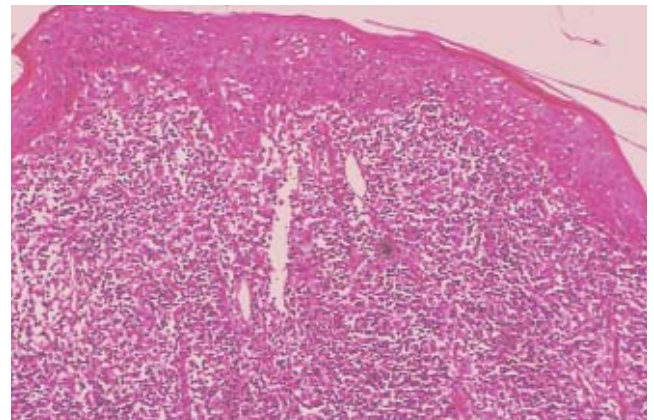


FIGURA 2: Denso infiltrado inflamatório na derme constituído de células linfóides com núcleos de morfologia variada (H&E 3,2 X 10)

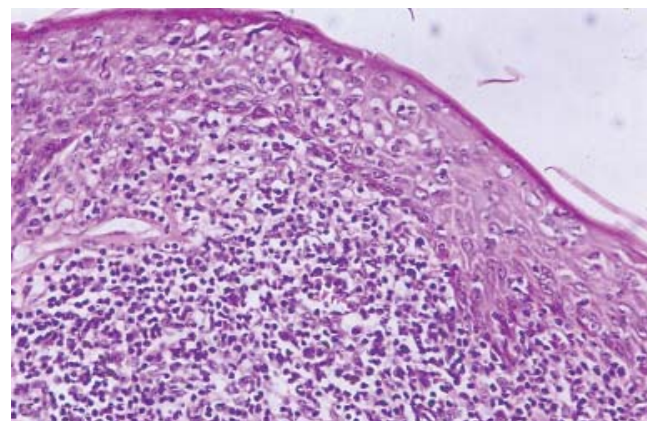


FIGURA 3: Detalhe do infiltrado celular mostrando células atípicas com núcleos grandes, hiper cromáticos e hiperconvolutos. Há também presença de atipias em arranjos intraepidérmicos (microabscessos de Pautrier) (H&E 10 X 10)

Approved by the Editorial Board and accepted for publication on 01.07.2009.

* Study conducted at the Federal University of Amazonas, (UFAM), Manaus, Amazonas, Brazil

Conflict of interest: None / *Suporte Financeiro: Nenhum*

Financial funding: None / *Conflito de Interesses: Nenhum*

¹ Head of the Department of Dermatology, School of Medicine, Federal University of Amazonas (UFAM), Manaus, Amazonas, Brazil.

² Dermatologist, Master's degree in Tropical Medicine, Dermatologist, Alfredo da Matta Foundation (FUAM), Manaus, Amazonas, Brazil.

³ Coordinator of the medical residency in Dermatology, Alfredo da Matta Foundation (FUAM), Manaus, Amazonas, Brazil.

⁴ Physician, Brazilian Airforce, Dermatology Department, Airforce Hospital, Manaus, Amazonas, Brazil.

The authors opted for complete surgical removal of the lesion. At a follow-up visit twelve months later the patient was asymptomatic and there was no recurrence of the lesion.

COMMENTS

Mycosis fungoides is a cutaneous T-cell lymphoma (CTCL) of primary cutaneous origin. Classically, it is characterized by an initial stage during which lesions are nonspecific, generally erythematous, squamous plaques. In the second stage, the initial lesions become infiltrated and new lesions appear. In the third stage, reddish-brown tumors appear that may progress to ulceration.¹ Histologically, mycosis fungoides is characterized by an infiltrate of atypical lymphoid cells with T-helper immunophenotype and accentuated epidermotropism forming an intraepidermal collection of cells known as Pautrier's microabscess.² In 1939, Woringer and Kolopp described a variant of this classic form in which skin involvement was limited to one or a few lesions. The presence of atypical mononuclear cells with a pagetoid appearance, marked epidermotropism and sparse dermal involvement was shown histologically.³

Other clinical forms with limited skin involvement have been described, including unilesional mycosis fungoides, recognized by its clinical, histolog-

ical and progressive characteristics. Clinically, it presents as a lesion in a plaque with an eczematous, psoriasis-like or poikilodermal appearance, while histological evaluation reveals lymphoid cells with atypia that are always limited to the papillary dermis or epidermis. Immunohistochemical studies show a predominance of CD4 over CD8 cells.⁵⁻⁷ The condition progresses with no tendency towards becoming systemic. Treatment with aggressive methods of radio or chemotherapy is not justified, since a good response is obtained with local therapies such as PUVA therapy, localized electron beam, topical nitrogen mustard, topical corticoids, topical bexarotene or surgical removal of the lesion.⁸

In addition to topical therapy with imiquimod, photodynamic therapy, a new, effective treatment for precancerous lesions and non-melanocytic skin cancer, is currently being used with success for the treatment of mycosis fungoides.^{9,10}

In conclusion, attention should be paid to recognizing this clinical variant of mycosis fungoides, since its characteristics of a favorable outcome, absence of systemic involvement and good response to local therapies permit less aggressive management of these patients and provide more accurate data regarding prognosis. □

Abstract: An 18-year old female patient presented with a single, erythematous, desquamative plaque. The clearly outlined lesion was situated in the abdominal region. The patient reported that it had been present for the past year and that she had used no previous medication. Histopathology showed lymphocytic infiltration with atypia, principally affecting the superficial dermis with epidermotropism and mild spongiosis. Immunophenotyping revealed a predominance of CD3-positive cells, confirming the diagnosis of mycosis fungoides.

Keywords: Diagnosis; Cutaneous T-cell lymphoma; Mycosis fungoides

Resumo: Paciente do sexo feminino, 18 anos, apresentando única placa eritemato-descamativa, bem delimitada, na região abdominal com evolução de 1 ano e sem uso anterior de medicação. O histopatológico demonstrou infiltrado linfocítico com atipias acometendo principalmente derme superficial com epidermotropismo e discreta espongiose. E a imunofenotipagem demonstrou predomínio de células CD3-positivo, confirmando o diagnóstico de Micose Fungóide.

Palavras-chave: Diagnóstico; Linfoma cutâneo de células T; Micose fungóide

REFERENCES:

1. Heald PW, Edelson LR. Cutaneous T Cell Lymphomas. In: Freedberg IM, Eisen AZ, Wolff K, Austen KF, Goldsmith LA, Katz SI, Fitzpatrick TB, editors. *Dermatology in General Medicine*. 7th ed. New York: McGraw-Hill; 2008. p. 146.
2. Kazakov DV, Burg G, Kempf W. Clinicopathological Spectrum of Mycosis Fungoides. *J Eur Acad Dermatol Venereol*. 2004;18:397-415.
3. Lisboa F, Piñeiro-Maceira J. Micose fungóide: métodos de apoio ao diagnóstico. *An Bras Dermatol*. 2002;77:95-107.
4. Oliver GF, Winkelmann RK. Unilesional mycosis fungoides: a distinct entity. *J Am Acad Dermatol*. 1989;20:63-70.
5. Evans LT, Mackey SL, Vidmar DA. An Asymptomatic scaly plaque. Unilesional mycosis fungoides (MF). *Arch Dermatol*. 1997;133:231-4.
6. Duncan LM. Cutaneous Lymphoma. Understanding the New Classification Schemes. *Dermatol Clin*. 1999;17:569-92.
7. Glusac EJ, Shapiro PE, McNiff JM. Cutaneous T-Cell Lymphoma. Refinement in the application of controversial histologic criteria. *Dermatol Clin*. 1999;17:601-14.
8. Sanches J, Moricz C, Neto C. Processos linfoproliferativos da pele. Parte 2 – linfomas cutâneos de células T e de células NK. *An Bras Dermatol*. 2006;81:7-25.
9. Ardigo M, Cota C, Berardesca E. Unilesional mycosis fungoides successfully treated with imiquimod. *Eur J Dermatol*. 2006;16:446.
10. Recio ED, Zambrano B, Alonso ML, de Eusebio E, Martín M, Cuevas J, et al. Topical 5-aminolevulinic acid photodynamic therapy for the treatment of unilesional mycosis fungoides: a report of two cases and review of the literature. *Int J Dermatol*. 2008;47:410-3.

MAILING ADDRESS / ENDEREÇO PARA CORRESPONDÊNCIA:

Jonas Ribas

Rua 24 de Maio, 220, Sala 510, Centro

69010 080

Phone: 92 3232 5687

How to cite this article/*Como citar este artigo*: Ribas J, Schettini APM, Ribas CBR, Corrêa CA. Case for diagnosis. Mycosis fungoides. *An Bras Dermatol*. 2010;85(6): 927-9.