

# Linear IgA bullous dermatosis: report of an exuberant case\*

## Dermatose por IgA Linear: relato de um caso exuberante

Beatriz Cavalcanti de Souza<sup>1</sup>  
Antônio José Tebcherani<sup>2</sup>  
Valéria Aoki<sup>4</sup>

Nádire Cristina Freire Pontes Fregonesi<sup>1</sup>  
Ana Paula Galli Sanchez<sup>3</sup>  
Juliana Christien Fernandes<sup>5</sup>

DOI: <http://dx.doi.org/10.1590/abd1806-4841.20132154>

**Abstract:** Linear immunoglobulin A dermatosis is a rare autoimmune bullous disease, but the most common autoimmune bullous dermatosis in children. We report a typical exuberant case of linear IgA dermatosis in a ten-month old child, who showed good response to treatment with corticosteroids and dapsone.

**Keywords:** Basement membrane; Immunoglobulin A; Skin diseases, vesiculobullous

**Resumo:** A dermatose por imunoglobulina A (IgA) linear é doença bolhosa autoimune rara, porém a mais comum das dermatoses bolhosas autoimunes da infância. Relatamos caso típico e exuberante de dermatose por IgA linear em uma criança de 10 meses, que apresentou boa evolução com o tratamento com corticóide e dapsona.

**Palavras-chave:** Dermatopatias vesiculobolhosas; Imunoglobulina A; Membrana basal

### INTRODUCTION

Linear immunoglobulin A (IgA) dermatosis is an autoimmune bullous disease characterized by subepidermal blister formation and the linear and homogenous deposition of IgA at the basement membrane zone (BMZ).<sup>1</sup> In linear IgA dermatosis (LAD), autoantibodies recognize multiple BMZ antigens, which are responsible for the different clinical aspects of the disease.<sup>2</sup> Although it is a rare dermatosis, it is the most common autoimmune bullous dermatosis in children.<sup>3</sup> It is essential that dermatologists know about it, for a delay in its diagnosis can lead to secondary infection of the lesions and, less frequently, produce morbidities such as ocular scarring and pharyngolaryngeal stenosis.<sup>4</sup>

### CASE REPORT

We report the case of a ten-month old white male patient from Guarulhos presenting with isolated and grouped tense serum-filled vesicles and bullae on healthy skin or on an erythematous base, mostly in a rosette pattern (Figures 1 and 2). The patient did not present mucosal lesions or fever, and there was no impairment of the patient's general condition. There was intense pruritus. His complete blood count was normal. We raised a suspicion of linear IgA dermatosis and of erythema multiforme. An anatomopathological examination of a bullous lesion showed subepidermal cleavage with neutrophilic inflammatory infiltrate (Figures 3 and 4). Direct immunofluorescence (DIF) of perilesional skin showed intense linear

Received on 23.09.2012.

Approved by the Advisory Board and accepted for publication on 23.10.2012.

\* Work conducted at Complexo Hospitalar Padre Bento de Guarulhos - Guarulhos (SP), Brazil.

Financial Support: none

Conflict of Interests: none

<sup>1</sup> Medical degree - Resident Physician, Dermatology Service, Complexo Hospitalar Padre Bento de Guarulhos - Guarulhos (SP), Brazil.

<sup>2</sup> PhD in Science, University of Sao Paulo (Universidade de Sao Paulo - USP) - Head of the Laboratory of Dermatopathology, Dermatology Service, Hospital Padre Bento de Guarulhos - Guarulhos (SP), Brazil.

<sup>3</sup> MSc in Science, School of Medicine, University of Sao Paulo (USP) - Attending physician, Dermatology Service, Complexo Hospitalar Padre Bento de Guarulhos - Guarulhos (SP), Brazil.

<sup>4</sup> Professor of Dermatology, School of Medicine, University of Sao Paulo (USP) - Associate Professor, Department of Dermatology, School of Medicine, University of Sao Paulo (USP) - Sao Paulo (SP), Brazil.

<sup>5</sup> Dermatologist - Preceptor of the Dermatology Service, Complexo Hospitalar Padre Bento de Guarulhos - Guarulhos (SP), Brazil.

deposition of IgA at the BMZ (Figure 5). As we awaited the results of the anatomopathological examination, DIF, and of the glucose-6-phosphate dehydrogenase test, we initiated treatment with prednisolone 1mg/kg and observed partial improvement of the patient's condition. After confirming the diagnosis of linear IgA dermatosis and detecting normal levels of glucose 6-phosphate dehydrogenase, we added dapsone 2mg/kg and maintained the oral corticosteroid therapy, with the patient achieving complete remission (Figure 6).

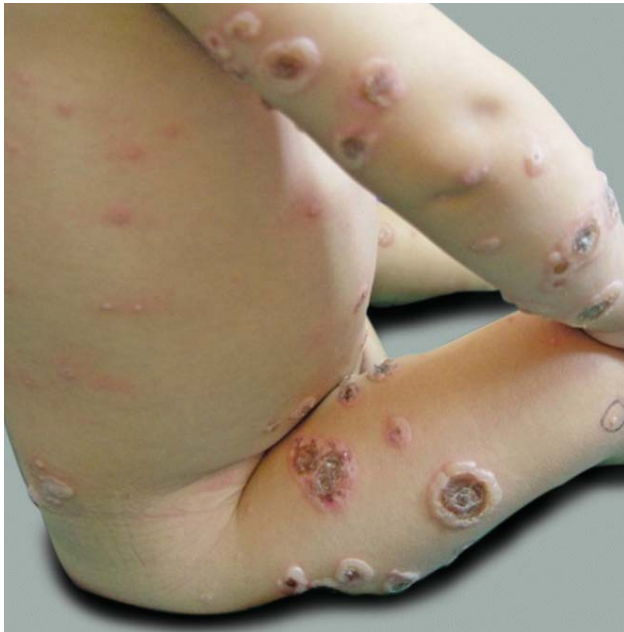

FIGURE 1: Disseminated bullous lesions

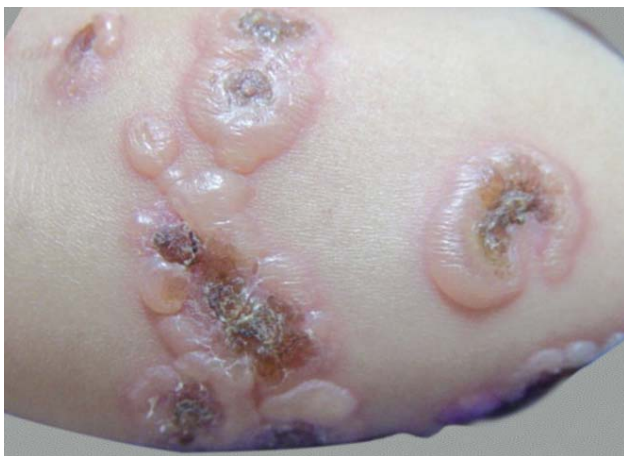

FIGURE 2: Typical lesions in a rosette pattern

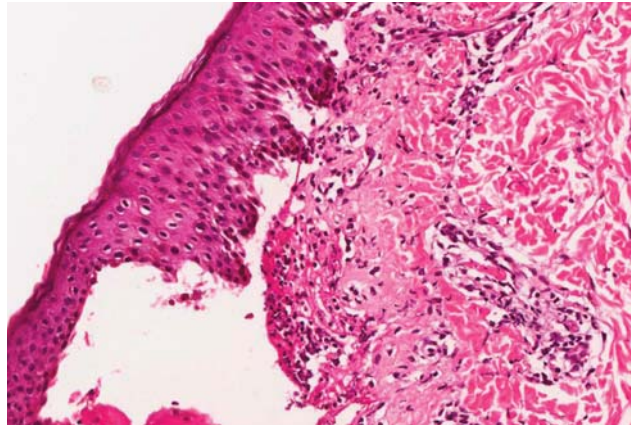


FIGURE 3: HE-200x. Subepidermal cleft showing intact roof and neutrophilic inflammatory infiltrate with fibrin deposition on the floor

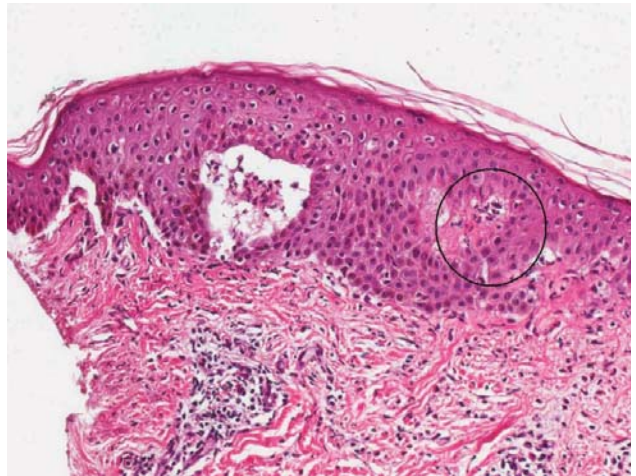


FIGURE 4: HE 200x. Focal subepidermal cleavage associated with intense neutrophilic infiltrate (circle)

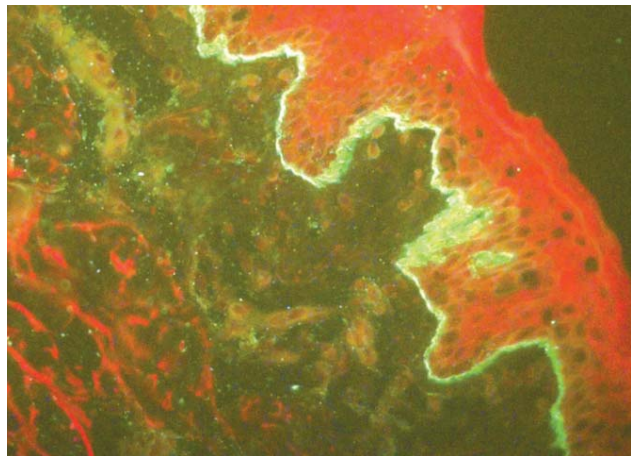


FIGURE 5: Linear deposition of IgA at the basement membrane

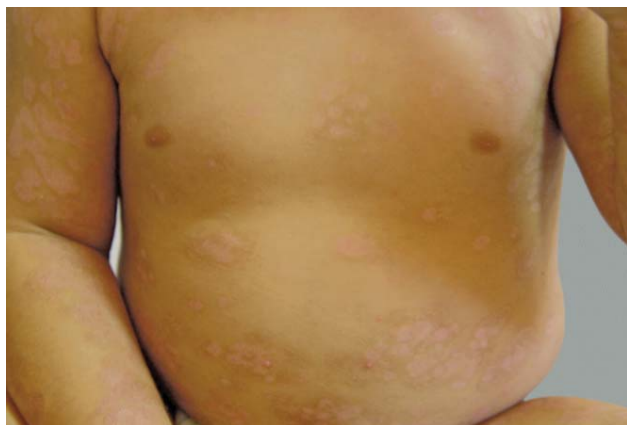

FIGURE 6: Clinical improvement after treatment with prednisolone and dapsone

## DISCUSSION

The first reports on LAD date from 1901-1905, when it was still considered a manifestation of dermatitis herpetiformis (DH). It was only 80 years later that it was differentiated from other bullous dermatoses of childhood.<sup>4</sup>

LAD can affect children as well as adults. In children, it usually begins after the age of six months, with a peak incidence at 4 to 5 years. It rarely persists after puberty. In adults, it usually commences after puberty or after the age of 60.<sup>4</sup> It affects all races, with a slight predominance in females.<sup>1,5,6</sup>

According to the age group affected, two different clinical patterns are found.<sup>5</sup> The childhood form is characterized by tense annular or arcuate bullae and vesicles with serous or hemorrhagic fluid. The emergence of new bullae at the periphery of previous lesions confers their classic rosette-like aspect.<sup>6</sup> They are mainly located on the lower abdomen, perineum, and perioral area.<sup>4</sup> Remission occurs until puberty in most cases, and spontaneous remission is often observed within two years.<sup>1,6</sup> The adult form can simulate lesions of bullous pemphigoid, DH, and epidermolysis bullosa acquisita.<sup>1</sup> It most commonly affects the limbs, trunk, buttocks, and face. In both forms, the intensity of pruritus is variable, and there can be mucosal involvement, with the oral and ocular mucosae being the most affected. Mucosal involvement is more common in adults. Oral lesions consist of painful ulcers and desquamative gingivitis. Chronic conjunctivitis can lead to synechia and even blindness. Pharyngolaryngeal involvement can lead to breathing difficulty due to stenosis of the mucosae.<sup>4</sup>

The etiologic factor triggering the autoimmune mechanism of the disease remains unknown. Some precipitating factors such as drugs and tumors of hematological lineage, especially in adults, have been described.<sup>1,4</sup> Of the drugs implicated, the most commonly associated with the disease is vancomycin, followed

by amiodarone, non-steroidal anti-inflammatory drugs, captopril, and ceftriaxone.<sup>2,4,5,6</sup> With respect to malignancy, it has not yet been elucidated if LAD can be considered a paraneoplastic manifestation or if it emerges concurrently with the malignancy, as mere coincidence.<sup>4</sup>

The target antigens of IgA are located at the BMZ, more specifically at the lamina lucida (LL) or sublamina dense (SL), or both locations. Some antigens have been identified, including collagen VII, BP230 and BP180. Most patients develop antibodies that react against LABD-97 (97 kd) and LAD-1 (120kd) subdomains, which are extracellular portions of BP180, a transmembrane glycoprotein that composes the hemidesmosome of keratinocytes of the basal layer.<sup>4,7</sup> Therefore, cleavage usually occurs at the LL.

An anatomopathological examination reveals subepidermal bullae with neutrophilic infiltrate and occasional eosinophils and lymphocytes. Microabscesses in the dermal papillae may occur.<sup>3</sup> Given these histopathological findings, which are common to other bullous dermatoses, it is essential to perform DIF, which shows linear and homogeneous deposition of IgA at the BMZ. Detection of IgG and/or C3 occasionally occurs.<sup>8,9</sup>

Indirect immunofluorescence (IIF), which is used to detect circulating antibodies, may be positive for IgA in 7-30% of cases and may be used to rule out other dermatoses.<sup>9</sup> Salt-split-skin, in general, shows fluorescence of the epidermal side of the bulla, since most antibodies are directed against BP180 antigens, located at the LL.<sup>9</sup> However, there may be dermal-epidermal or dermal fluorescence, depending on the target antigen.

The drug of first choice for treatment of LAD is dapsone, whose main adverse effects are methemoglobinemia and hemolytic anemia.<sup>10</sup> The risk of these complications may be minimized by measuring the level of glucose 6-phosphate dehydrogenase, with mild anemia being present even when the levels of this enzyme are normal. Other drugs used are sulfonamides, oral corticosteroids, mycophenolate mofetil, azathioprine, methotrexate, and cyclosporine. There are also reports of the use of antibiotics such as doxycycline, erythromycin, and oxacillin.<sup>4</sup>

We reported an exuberant typical case of LAD in a ten-month old child, who responded satisfactorily to treatment with dapsone and oral prednisolone, with dapsone being the drug of choice for treatment of LAD. This case report shows the importance of knowing about this disease, whose differential diagnosis includes bullous dermatoses of childhood such as erythema multiforme, primary herpes infection, congenital epidermolysis bullosa, and ichthyosis bullosa. We stress the importance of performing DIF to confirm the diagnosis of the disease and to establish an appropriate treatment. □

## REFERENCES

1. Rao CL, Hall III RP. Dermatoze por Imunoglobulina A e Doença Bolhosa Crônica da infância. In: Wolff K, Goldsmith LA, Katz SI, Gilchrist BA, Paller AS, Leffell DJ, editores. Fitzpatrick Tratado de Dermatologia. 7 ed. Rio de Janeiro: RevinterLda; 2011. p. 485-90.
2. Guide SV, Marinkovich MP. Linear IgA bullous dermatosis. Clin Dermatol. 2001;19:719-27.
3. Kharfi M, Khaled A, Karaa A, Zarea I, Fazaa B, Kamoun MR. Linear IgA bullous dermatosis: the more frequent bullous dermatosis of children. Dermatol Online J. 2010;16:2.
4. Fortuna G, Marinkovich MP. Linear immunoglobulin A bullous dermatosis. Clin Dermatol. 2012;30:38-50.
5. Venning VA. Linear IgA disease: clinical presentation, diagnosis, and pathogenesis. Dermatol Clin. 2011;29:453-8, ix.
6. Sampaio SAP, Rivitti EA, Maruta CW, Santi CG. Erupções Vésico-Bolhosas. In: Sampaio SAP, Rivitti EA, editores. Dermatologia. 3 ed. São Paulo: Artes Médicas; 2008. p. 326-7.
7. Horváth B, Niedermeier A, Podstawa E, Müller R, Hunzelmann N, Kárpáti S, et al. IgA autoantibodies in the pemphigoids and linear IgA bullous dermatosis. Exp Dermatol. 2010;19:648-53.
8. Morrison LH. Direct immunofluorescence microscopy in the diagnosis of autoimmune bullous dermatoses. Clin Dermatol. 2001;19:607-13.
9. Aoki V, Sousa JX Jr, Fukumori LM, Périgo AM, Freitas EL, Oliveira ZN. Direct and indirect immunofluorescence. An Bras Dermatol. 2010;85:490-500.
10. Passos L, Rabelo RF, Matsuo C, Santos M, Talhari S, Talhari C. Linear IgA/IgG bullous dermatosis: successful treatment with dapsone and mycophenolatemofetil. An Bras Dermatol. 2011;86:747-50.

---

### MAILING ADDRESS:

*Beatriz Cavalcanti de Souza*  
*Rua Bela Cintra, n 336, apto 34 - Consolação*  
*CEP 01415-000 - São Paulo - SP*  
*Brazil*  
*E-mail: biamedunesp@hotmail.com*

How to cite this article: Souza BC, Fregonesi NCFP, Tebcherani AJ, Sanchez APG, Aoki V, Fernandes JC. Linear IgA bullous dermatosis: Report of an exuberant case. An Bras Dermatol. 2013;88(6 Suppl 1):S67-70.