





exclusively within and around lipomas) and juxta-articular (deposition of painful solitary fat in the proximity of large joints).² The treatment aims to relieve pain and correct disfigurement. Medications, surgery and psychiatric care should be used in combination. Among the therapeutic options are the use of analgesics, non-steroidal anti-inflammatory drugs and opioids with variable response. The use of intralesional lidocaine in the form of adhesives or intravenous, seems to alleviate pain by regulating a possible hyperactivity of the sympathetic nervous system.^{1,3} Liposuction and lipectomy are effective in reducing symptoms and have the same efficacy in removing lipomas, alleviating pain and correcting disfigurement and associated psychiatric disorders, but with a risk of recurrence.¹ About the prognosis, there is little research done on the natural history of Dercum's disease, but case reports have suggested that pain may be aggravated over time.¹ There is a need to become familiar with this entity so that it is not an underdiagnosed condition anymore.⁴

This report describes a typical presentation of Dercum's disease in a female, obese and menopausal patient, with the development of painful lipomas mainly in the extremities and trunk, who had satisfactory control of symptoms with lipectomy. An overview of the pathogenesis, diagnosis and treatment of this rare and poorly understood disease is also presented. Because it is a rare disease with limited therapeutic options, the treatment modality chosen in this case is presented, which yielded a good result. The importance of new studies is also emphasized, which may help to understand its real etiology and the implementation of treatments capable of acting early, blocking the pathophysiological mechanisms. □

REFERENCES

- Hansson E, Svensson H, Brorson H. Review of Dercum's disease and proposal of diagnostic criteria, diagnostic methods, classification and management. *Orphanet J Rare Dis.* 2012;7:23.
- Desai MJ, Siriki R, Wang D. Treatment of pain in Dercum's disease with Lidoderm (lidocaine 5% patch): a case report. *Pain Med.* 2008;9:1224-6.
- Kosseifi S, Anaya E, Dronovalli G, Leicht S. Dercum's disease: an unusual presentation. *Pain Med.* 2010;11:1430-4.
- Rosmaninho A, Pinto-Almeida T, Fernandes IC, Machado S, Selores M. Do you know this syndrome?. *An Bras Dermatol.* 2012;87:324-5.
- Martinenghi S, Caretto A, Losio C, Scavini M, Bosi E. Successful treatment of Dercum's disease by transcutaneous electrical stimulation. *Medicine (Baltimore).* 2015;94:e950.

AUTHORS' CONTRIBUTIONS

Juliana D'Andrea Molina	 ORCID 0000-0001-9261-5739
Conception and planning of the study; Elaboration and writing of the manuscript; Critical review of the manuscript	
Gisele Alborghetti Nai	 ORCID 0000-0003-1674-7371
Intellectual participation in propaedeutic and/or therapeutic conduct of the cases studied	
Tatiana Cristina Pedro Cordeiro de Andrade	 ORCID 0000-0001-7804-2137
Critical review of the manuscript	
Marilda Aparecida Milanez Morgado de Abreu	 ORCID 0000-0001-9099-6013
Approval of the final version of the manuscript; Effective participation in research orientation; Critical review of the literature; Critical review of the manuscript	

How to cite this article: Molina JD, Nai GA, Andrade TCPC, Morgado de Abreu MAM. Dercum's disease: a rare and underdiagnosed disease. *An Bras Dermatol.* 2018;94(2): 251-3.

Kotatsu-induced erythema ab igne*

David Baltazar¹
Ross Brockman²
Eric Simpson²

DOI: <http://dx.doi.org/10.1590/abd1806-4841.20198792>

Erythema ab igne is a reticulated, hyperpigmented dermatosis that arises following chronic infrared exposure. It has been reported with prolonged exposure to heating pads or blankets, hot water bottles, heated furniture, laptop computers, prolonged bathing in hot water, open fires, and wood-burning stoves, among others.¹⁻³ It is usually asymptomatic and resolves with discontinuation of the offending heat source. There are several reported cases of neoplastic transformation occurring at the affected site.^{4,5}

A thirty-four-year-old Caucasian female presented to the dermatology clinic for routine follow-up. The patient had a history of alopecia totalis for the previous four years, which had been treated with a Janus kinase (JAK) inhibitor for the previous five months. The patient experienced regrowth of the majority of her scalp hair, eyebrows, and patches of leg hair. The patient's review of symptoms was essentially negative with the exception of a new rash on her bilateral medial thighs. Given her successful regrowth of hair, the patient was apprehensive that her JAK inhibitor would be discontinued given her developing skin rash. Physical examination of the bilateral medial thighs revealed reticulated, hyperpigmented-to-violaceous patches (Figure 1). The skin texture was normal, and there were no signs of venous stasis affecting the distal lower extremities. The patient was employed in computer science and worked primarily from home. She denied use of a laptop computer being placed on her lap or other common heat sources. However, she did report that for the previous two years she had been using a Japanese *kotatsu*

Received 14 September 2018.

Accepted 03 October 2018.

* Work conducted at the Western University of Health Sciences, Lebanon (OR), USA.

Financial support: None.

Conflict of interest: None.

¹ Department of Family Medicine, Western University of Health Sciences, Lebanon (OR), USA

² Department of Dermatology, Oregon Health and Science University, Portland (OR), USA

MAILING ADDRESS:

David Baltazar

E-mail: dbaltazar@westernu.edu

©2019 by Anais Brasileiros de Dermatologia



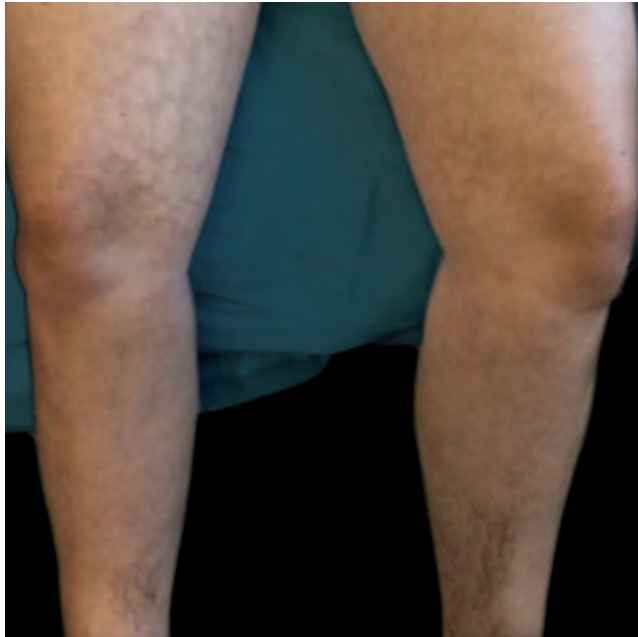

FIGURE 1: Reticulated, hyperpigmented-to-violaceous macules on the lower limbs

table as a workspace. The patient's legs rested just under the electric heating element for a considerable amount of time throughout the day. The patient was diagnosed with erythema ab igne, and she was counseled to avoid chronic exposure to heat on her lower extremities.

Erythema ab igne initially begins as transient, blanchable, macular erythema confined to the affected geographic area that reflects that shape and size of the heat source.⁴ With continued heat exposure, the area then develops into a fixed, reticulated pattern of hyperpigmentation, which can progress to skin atrophy, hyperkeratosis, and sometimes telangiectasias.³ Biopsy of the affected site may reveal a wide array of findings histologically, including nonspecific thinning of the epidermis, blunting of the rete ridges, and altered dermal elastic fibers with dermal hemosiderin and melanin incontinence.^{3,4} Since these findings are nonspecific, the diagnosis of EAI is usually made clinically as in our case, when reticulated hyperpigmentation and erythema are present in the context of skin that is chronically exposed to heat.

While EAI is more common in sites of chronic pain, such as the low back or abdomen, there are numerous case reports of EAI arising in other locations following long-term heat exposure. To date, most cases of EAI have described similar lesions caused by heating pads, hot water bottles, laptop computers, and heated massage chairs. While these cases have offered diverse presentations, our case demonstrates another novel presentation of erythema ab igne. With the gaining popularity of *kotatsu* tables, clinicians should be aware of this possible adverse effect associated with them.

Early identification and education for patients on the risks of using local heat sources chronically, as well as removing the offending heat source when EAI appears are of high priority. Once the heating source is identified, it is important to address the underlying cause for use of the heating agent, whether for pain or warmth. If

the reason for use is pain, the underlying cause should be identified and treated. There have been cases of occult gastrointestinal disease and malignancy identified after EAI developed in sites of overlying skin or areas of referred pain.¹ Alternatively, if the underlying reason is for warmth, another heating modality should be considered. Body heat instability should also be addressed. In our case, chronic external heat was used in the context of alopecia totalis. These are just a couple examples when clinicians may intervene and offer not only guidance for EAI but also treatment of the underlying cause.

Although there is generally a good prognosis when treating EAI, the risk of malignant transformation by various cells is well documented.^{4,5} Identifying and avoiding the offending exposure with continued monitoring of the affected area is important. Additionally, if any area affected with EAI demonstrates surface changes or symptoms, then biopsy should be obtained to evaluate for malignant transformation. □

REFERENCES

1. Meffert JJ, Davis BM. Furniture-induced erythema ab igne. *J Am Acad Dermatol.* 1996;34:516-7.
2. Bilic M, Adams BB. Erythema ab igne induced by a laptop computer. *J Am Acad Dermatol.* 2004;50:973-4.
3. Waldorf DS, Rast MF, Garofalo VJ. Heating-Pad Erythematous Dermatitis "Erythema Ab Igne". *JAMA.* 1971;218:1704.
4. Wharton JB, Sheehan DJ, Leshner JL Jr. Squamous cell carcinoma in situ arising in the setting of erythema ab igne. *J Drugs Dermatol.* 2008;7:488-9.
5. Jones CS, Tyring SK, Lee PC, Fine JD. Development of Neuroendocrine (Merkel Cell) Carcinoma Mixed with Squamous Cell Carcinoma in Erythema Ab Igne. *Arch Dermatol.* 1988;124:110-3.

AUTHORS' CONTRIBUTIONS

David Baltazar	ORCID 0000-0001-7159-8220
Approval of the final version of the manuscript; Elaboration and writing of the manuscript; Critical review of the manuscript	
Ross Brockman	ORCID 0000-0003-2243-2050
Approval of the final version of the manuscript; Elaboration and writing of the manuscript; Obtaining, analyzing and interpreting the data; Critical review of the literature; Critical review of the manuscript	
Eric Simpson	ORCID 0000-0002-8793-7087
Approval of the final version of the manuscript; Critical review of the literature; Critical review of the manuscript	

How to cite this article: Baltazar D, Brockman R, Simpson E. *Kotatsu-induced erythema ab igne.* *An Bras Dermatol.* 2019;94(2): 253-4.