

Pediatric case of trichilemmal cyst arising on the face*



Dear Editor,

Trichilemmal cyst is sometimes seen in the scalp of adults. We herein describe a rare case of a trichilemmal cyst arising on the forehead of a child.

A 9-year-old boy visited our hospital, complaining of a nodule above the left eyebrow that had increased in size over the previous year. He had no past medical history, and he and his parents denied any prior triggering events such as trauma on this site. Physical examination showed a 7 × 5 mm, normal skin-colored, slightly dome-shaped subcutaneous nodule (Fig. 1A). Laboratory examination was normal. The nodule was surgically removed under local anesthesia. Histopathological examination revealed a relatively well-circumscribed cystic structure located in the subcutaneous tissue (Fig. 1B). The cyst was filled with acidophilic amorphous substances, and the cyst walls consisted of epithelial cells without forming granular cell layers (Fig. 1C). The serial sections of histopathology showed cholesterol crystals and foreign body giant cells within and around the cyst (Fig. 1D). After the surgery was performed, 10 years have passed without local recurrence.

We diagnosed the case as a trichilemmal cyst based on the histopathological features of well-defined cystic structures consisting of epithelial cells showing trichilemmal keratinization. Cholesterol crystals and cholesterol clefts, which are often observed in epidermal cysts, were observed in the present case, but those histopathological features are not diagnostic. The presence of foreign body granuloma may suggest previous partial ruptures of trichilemmal cysts. The cyst wall was not adjacent to sebaceous glands, and hair follicles and hair shafts were not observed in and around the cysts. Moreover, the subcutaneous nodule did not exist at birth, and thus dermoid cyst was excluded. The trichilemmal cyst is a benign adnexal tumor that arises from the outer root sheath of a hair follicle. It usually presents as an asymptomatic firm nodule, which at times can be slightly painful. It is mainly seen in areas bearing hair follicles, mostly on the scalp. Middle-aged females are more commonly affected.¹ The onset of a trichilemmal cyst in a young boy is rare. To our knowledge, only 3 cases have been reported that developed trichilemmal cysts under the age of 10, including the present case.^{2,3} Clinical findings of these cases are shown in Table 1.^{2,3} The thigh, penis, and eyebrow were involved, which were rare sites. Our patient is now the youngest among the reported Japanese cases. On the other hand, the youngest case was in a 5-year-old male, who developed a trichilemmal cyst on the penis after hypospadias repair.³ The authors speculated that the distal hypospadias repair had triggered squamous metaplasia with keratinization, leading to the development of a trichilemmal cyst in a non-hair-bearing area of the body.

In our department, 25 cases including the present case were diagnosed as trichilemmal cysts over the past 10 years,

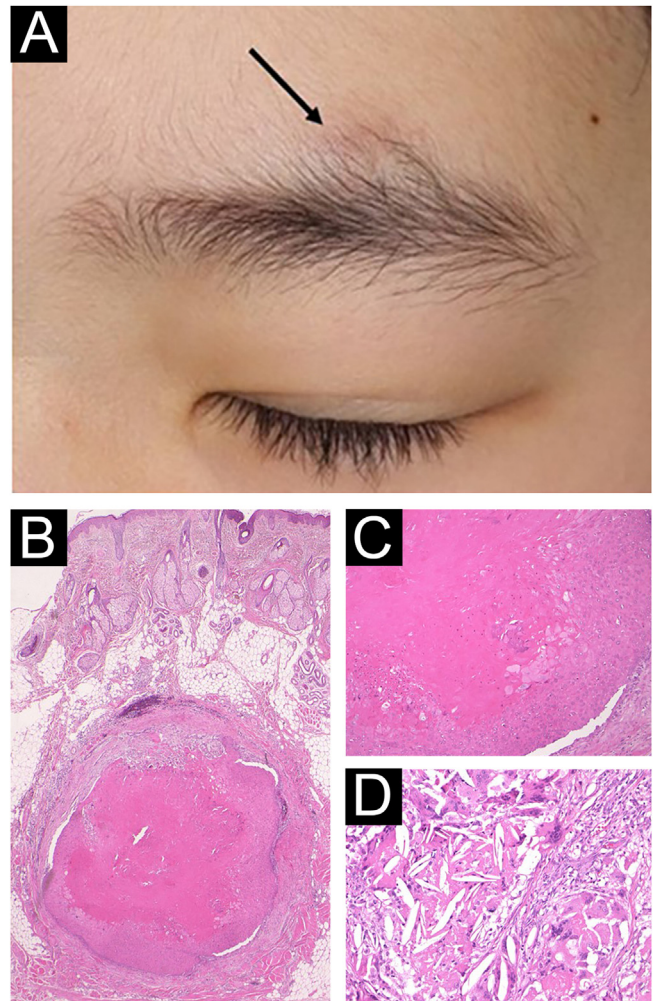


Figure 1 (A) A slightly dome-shaped subcutaneous nodule above the left eyebrow (arrow). (B) Histopathological examination showing a cystic structure located in the subcutaneous tissue (Hematoxylin & eosin, ×20). (C) Higher magnification shows that the cyst walls keratinize towards the lumen without forming granular cell layers (Hematoxylin & eosin, ×200). (D) Cholesterol crystals and foreign body giant cells (Hematoxylin & eosin, ×200).

with only 1 pediatric case (the present case). The patients consisted of 12 males and 13 females, and the mean age was 49 years. The involved sites were most frequently observed in the scalp (n = 16), followed by the face (7), abdomen (1), and forearm (1). Among the facial lesions, 2 were observed in the eyebrow, 2 were observed in the upper and lower eyelids, 2 were observed on the forehead, 1 was observed in the cheek. Trichilemmal cyst is one of the nodules arising on the head and neck, which rarely involves children.

Financial support

None declared.

* Study conducted at the Department of Dermatology, Fukushima Medical University, Fukushima, Japan.

Table 1 Summary of the reported cases of pediatric trichilemmal cyst

Authors	Age/sex	Site	Size	Clinical features	Color
Imamura H, et al. ²	10/male	Flexor aspect of thigh	About 15 × 20 mm	Elastic, soft, non-tender nodule	Slightly blue
Madan S, Joshi R. ³	5/male	Ventral aspect of the frenulum of the penis	15 × 16 mm	Soft, cystic, smooth-surfaced, elastic, non-tender, and relatively mobile mass	Unidentified
Our case	9/male	Above eyebrow	7 × 5 mm	Slightly dome-shaped, non-tender subcutaneous nodule	Slightly red

Authors' contributions

Mai Endo: Design of the study; Writing of the manuscript; data collection, analysis and interpretation; review and approval of the final version of the manuscript.

Toshiyuki Yamamoto: Design of the study; writing of the manuscript; data collection, analysis, and interpretation; review and approval of the final version of the manuscript.

- Imamura H, Izumi T, Kimura S. Two cases of trichilemmal cyst on the thigh. *Jpn J Clin Dermatol* (in Japanese). 1997;51:168–70.
- Madan S, Joshi R. Trichilemmal cyst of the penis in a paediatric patient. *Sultan Qaboos Univ Med J*. 2015;15:e129–32.

Mai Endo *, Toshiyuki Yamamoto 

Department of Dermatology, Fukushima Medical University, Fukushima, Japan

* Corresponding author.

E-mail: enmai04@fmu.ac.jp (M. Endo).

Received 29 March 2022; accepted 1 May 2022

Available online 16 September 2023

<https://doi.org/10.1016/j.abd.2022.05.012>

0365-0596/ © 2023 Sociedade Brasileira de Dermatologia.

Published by Elsevier España, S.L.U. This is an open access article under the CC BY license (<http://creativecommons.org/licenses/by/4.0/>).

Conflicts of interest

None declared.

References

- Jha AK, Sinha R, Prasad S, Kumar S. Multiple trichilemmal cysts of the scalp in a young male. *Int J Trichol*. 2015;7:167–9.

Pigmented squamous cell carcinoma in a non-photo-exposed area of an indigenous woman[☆]



Dear Editor,

A 67-year-old indigenous woman, living in a reservation in the north of the state of Espírito Santo, Brazil, previously hypertensive and a smoker, reported an erythematous area on her left thigh of more than ten years duration, with radial growth and mild pruritus. On examination, she had an infiltrated erythematous, brownish, hyperkeratotic plaque on the proximal portion of the left thigh, a non photo-exposed area (Fig. 1). There was no evidence of solar elastosis around the lesion. Inguinal lymph node enlargement was not identified. Dermoscopy showed deposits of a black pigment,

erythema, and central linear vessels, in addition to glomerular vessels and peripheral striae.

The main diagnostic hypotheses were Bowen's disease, melanoma and verrucous syndrome (PLECT - paracoccidiodomycosis, leishmaniasis, sporotrichosis, chromomycosis, cutaneous tuberculosis).

Cultures were performed for fungi and bacteria, which were negative. Histopathological evaluation of an incisional biopsy showed compact hyperkeratosis, acanthosis, impaired cell maturation, pigment deposits, without an increase in melanocytes, in addition to atypical keratinocytes and mitoses in the middle portion of the epidermis, confirming pigmented Bowen's disease (Fig. 2).

Initially, imiquimod 50 mg/g cream was prescribed to reduce the lesion and facilitate excision, but without a satisfactory response. The lesion was excised with a Limberg flap, and the anatomopathological analysis showed invasion of the deep reticular dermis, characterizing pigmented squamous cell carcinoma (SCC - Fig. 3). Immunohistochemistry showed positivity of keratinocytes for EMA (epithelial membrane antigen) and p53 and p63 proteins, confirming the diagnosis (Fig. 4).

Squamous cell carcinoma (SCC) accounts for 20% to 50% of skin cancers in Brazil. It is more common in Caucasians

[☆] Study conducted at the Department of Dermatology, Hospital Universitário Cassiano Antônio Moraes, Universidade Federal do Espírito Santo, Vitória, ES, Brazil.