





5. Singh A, Cook C, Kollmann K, Rajpara A. Acute cutaneous botryomycosis of the hands. *IDCases*. 2020;19:e00709.

Lina Paola González-Cardona  ^{a,*},
Adriana Mercedes Alejo Villamil  ^a,
Carolina Cortés Correa  ^b,
Elkin Omar Peñaranda Contreras  ^b

^a Pontificia Universidad Javeriana, Bogotá, Colombia

^b Hospital Universitario de la Samaritana, Bogotá, Colombia

* Corresponding author.

E-mail: linapgonzalez@gmail.com

(L.P. González-Cardona).

Received 17 September 2020; accepted 16 October 2020

Available online 21 May 2022

<https://doi.org/10.1016/j.abd.2020.10.023>

0365-0596/ © 2022 Sociedade Brasileira de Dermatologia.

Published by Elsevier España, S.L.U. This is an open access article under the CC BY license (<http://creativecommons.org/licenses/by/4.0/>).

Infectious dermatitis associated with HTLV-I: uncommon case in southern Brazil simulating refractory atopic dermatitis[☆]



Dear Editor,

HTLV-I (human T lymphotropic virus type-I), a human retrovirus discovered in the 1980s,¹ infects preferentially CD4 T lymphocytes. The worldwide prevalence is uncertain, with an estimated 5 to 10 million infected individuals,² mainly in Japan, Iran, Latin America, and Africa.^{3,4}

Infectious dermatitis associated with HTLV-I (IDH) was described in Jamaica in 1966, and associated with HTLV-I in 1990, being a rare and treatment-resistant form of exudative dermatitis.^{1,3-5}

We describe a case of a seven-year-old girl, from the south of Brazil, born through vaginal delivery, with severe recurrent eczema since she was 18 months of age, when she stopped being breastfed.

On examination, she had macerated, exudative, and foul-smelling eczematous lesions on the scalp and retroauricular, cervical, antecubital, and intergluteal regions; temporal alopecia; crusts in the umbilical, perioral and nasal regions (Figs. 1 and 2). Laboratory tests were normal, except serology for HTLV-I/II which was reactive, confirming the diagnosis of IDH according to the criteria described in Table 1.⁵ The other viral serologies were negative. The neurological examination was normal. Her mother also had positive serology for HTLV-I/II. Treatment with oral sulfamethoxazole and trimethoprim was started, with significant clinical improvement.

IDH usually starts in childhood and is considered an early clinical marker of HTLV-I infection.^{3,4} The main route of transmission is through breastfeeding.^{3,5} Its pathogene-

sis involves individual susceptibility, immune dysregulation, bacterial superinfection, environmental antigenic stimulation and persistent inflammation.⁴ The pro-inflammatory state may be related to the proliferation of T lymphocytes and high levels of IL-1, IL-6, TNF α and IFN α ; elevated IgE levels increase susceptibility to *S. aureus* and *S. beta-haemolyticus*.⁴

Patients should be screened for HTLV-I in cases of severe, resistant, recurrent eczema with secondary infection.⁴ Atopic dermatitis (AD) and seborrheic dermatitis are the main differential diagnoses.⁴ Histopathology is non-specific and CD8 T lymphocytes predominate in immunohistochemistry.⁴ Approximately 10% of those infected develop adult T-cell leukemia/lymphoma and HTLV-I-associated myelopathy/adult tropical spastic paraparesis.²⁻⁴ Symptoms tend to show remission at puberty but persist if they start at the adult age.^{1,4}

IDH does not have a specific treatment or vaccine; however, it usually responds to antibiotics such as sulfamethoxazole and trimethoprim, and cephalexin, for long periods, with recurrence being common.^{3,4} Infected individuals must be monitored due to the possibility of severe neurological and lymphoproliferative complications.

The interruption of the transmission involves screening blood donors, using condoms, family counseling, avoiding breastfeeding, and avoid sharing needles.⁴

IDH is relevant in the practices of dermatologists, infectologists, hematologists and neurologists and, despite its absence from the lists of neglected diseases, the perception is that it is very close to that situation.⁴ It is not compulsorily notified, and there are not even policies for the prevention or care for the virus carriers.

We emphasize the importance of this case, as it occurred outside the endemic areas in Brazil – which are the northern and northeastern regions – and because it was managed as a recalcitrant AD for a long period.

[☆] Study conducted at the Ambulatório de Dermatologia Sanitária do Rio Grande do Sul; Porto Alegre, RS, Brazil.

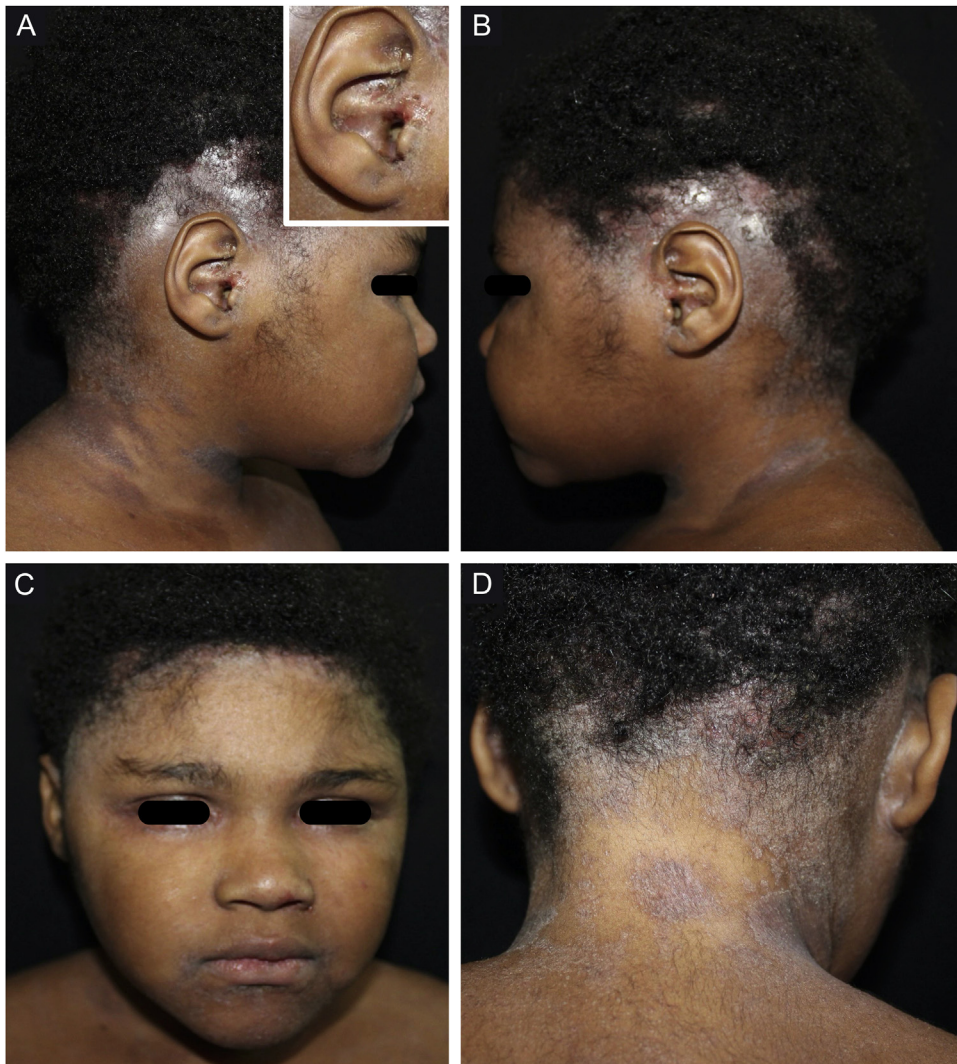

Figure 1 (A-D), Eczematous and exudative lesions on the scalp, with areas of alopecia, and excoriations in the external auditory canal. In A, a detail of the affected external auditory canal. C, infrapalpebral erythematous areas and perioral eczematous lesions. D, eczematous lesions in the cervical and retroauricular regions; occipital alopecia.

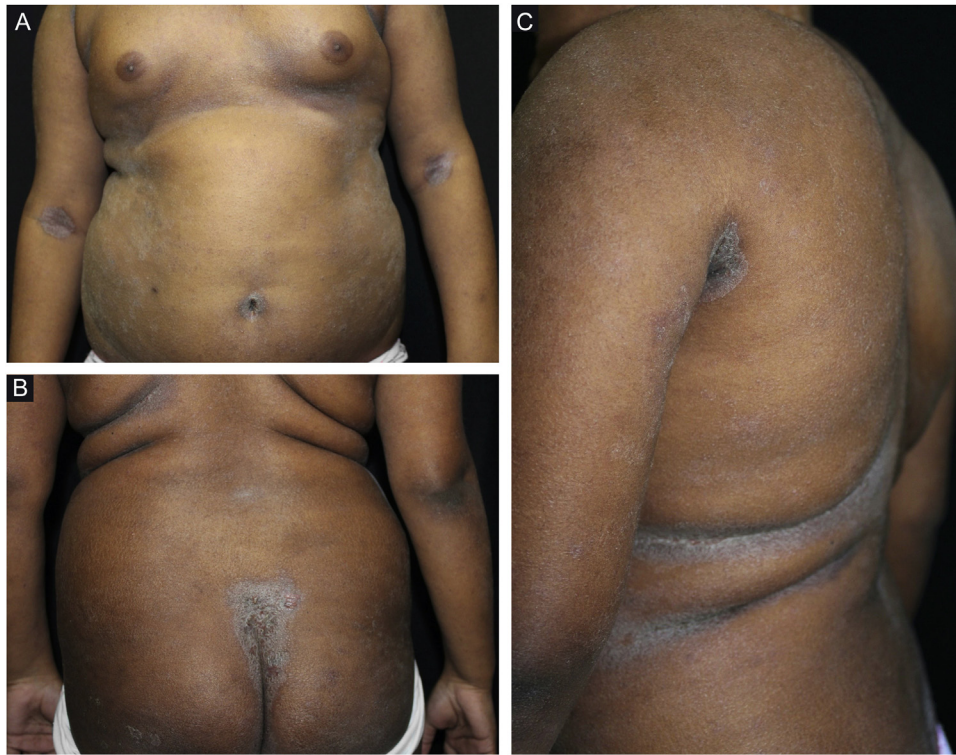

Figure 2 (A–C), Eczematous lesions on the trunk, antecubital fossae and intergluteal region, associated with diffuse xerosis.

Table 1 Major criteria for the diagnosis of infectious dermatitis associated with HTLV-I.

1. Presence of erythematous-desquamative, exudative and crusted lesions on the scalp, retroauricular areas, cervical and inguinal regions, axillae, perioral and paranasal skin, ears, chest, abdomen and other sites
2. Crusts on the nostrils
3. Chronic recurrent dermatitis with immediate response to appropriate therapy, but recurrence soon after discontinuation of antibiotics
4. Diagnosis of HTLV-I infection by serological or molecular biology tests

Adapted from La Grenade⁵ et al. apud De Oliveira et al.¹
 Of the four main criteria, three are necessary for the diagnosis; 1, 3 and 4 are mandatory.
 Criterion 1 requires the involvement of three or more sites, including the scalp and retroauricular areas.

Financial support

None declared.

Authors' contributions

Michele Caroline dos Santos Garcia: Design and planning of the study; drafting and editing of the manuscript; collection, analysis, and interpretation of data; intellectual participation in the propaedeutic and/or therapeutic conduct of the studied cases; critical review of the literature; critical

review of the manuscript; approval of the final version of the manuscript.

Renata Heck: Critical review of the manuscript; intellectual participation in the propaedeutic and/or therapeutic conduct of the studied cases; effective participation in research orientation; approval of the final version of the manuscript.

Renan Rangel Bonamigo: Critical review of the manuscript; intellectual participation in the propaedeutic and/or therapeutic conduct of the studied cases; effective participation in research orientation; approval of the final version of the manuscript.

Cristiane Almeida Soares Cattani: Design and planning of the study; critical review of the manuscript; intellectual participation in the propaedeutic and/or therapeutic conduct of the studied cases; effective participation in research orientation; approval of the final version of the manuscript.





Conflicts of interest

None declared.

References

1. Oliveira MFSP, Fatal PL, Leite Primo JR, Silva JLS, Batista ES, Farré L, et al. Infective dermatitis associated with human T-cell lymphotropic virus type 1: evaluation of 42 cases observed in Bahia, Brazil. *Clin Infect Dis.* 2012;54:1714–9.
2. Murphy EL. Infection with human T-lymphotropic virus types-1 and -2 (HTLV-1 and -2): Implications for blood transfusion safety. *Transfus Clin Biol.* 2016;23:13–9.

- Romero FT, Pinilla-Martín B, Pérez SIP. Infective dermatitis associated with HTLV-1: dermatosis to be considered in patients from endemic areas. *Aten Primaria*. 2020;52:785–6.
- Bravo FG. Infective dermatitis: a purely cutaneous manifestation of HTLV-1 infection. *Semin Diagn Pathol*. 2020;37:92–7.
- Grenade LL, Manns A, Fletcher V, Derm D, Carberry C, Hanchard B, et al. Clinical, pathologic, and immunologic features of human T-lymphotropic virus type I-associated infective dermatitis in children. *Arch Dermatol*. 1998;134:439–44.

Michele Caroline dos Santos Garcia  ^{a,*},
Renata Heck  ^a, Renan Rangel Bonamigo  ^{a,b},
Cristiane Almeida Soares Cattani  ^a

^a Ambulatório de Dermatologia Sanitária do Rio Grande do Sul, Porto Alegre, RS, Brazil

^b Faculty of Medicine, Universidade Federal do Rio Grande do Sul, Porto Alegre, RS, Brazil

* Corresponding author.

E-mail: michelecs Garcia@yahoo.com.br (M.C. Garcia).

Received 9 October 2020; accepted 17 October 2020

Available online 30 May 2022

<https://doi.org/10.1016/j.abd.2020.11.017>

0365-0596/ © 2022 Sociedade Brasileira de Dermatologia.

Published by Elsevier España, S.L.U. This is an open access article under the CC BY license (<http://creativecommons.org/licenses/by/4.0/>).

Laser-assisted delivery of imiquimod in Brooke-Spiegler syndrome[☆]



Dear Editor,

A 34-year-old female was admitted with Brooke-Spiegler Syndrome (BSS). On dermatologic examination, confluent, infiltrated papules compatible with trichoepithelioma were detected (Fig. 1A, Fig. 2A).

Initially, the prominent lesions on the left nasolabial sulcus skin were ablated by full-field erbium: YAG laser applied at the setting of 3-mm spot-size, 6 J/cm², 10 Hz with 100 μs pulse duration (Fotona, XS, Dynamis). Due to the requirement of sedoanalgesia for the remaining lesions, she was offered fractional erbium: YAG laser and topical imiquimod combination.

The pre-determined 4-week treatment cycles were repeated for 6-months as monthly Ablative Fractional Laser (AFL) applications immediately followed by imiquimod cream applied 5 consecutive days per week for the first 2-weeks. This was followed by a treatment-free period of 2-weeks. Severe irritation occurred that subsided during treatment-free periods. On 6-months control, her self-reported score changed from 10 to 0 for the part treated with full-field resurfacing and 10 to 2 for the parts treated with a combination of AFL and imiquimod (Fig. 1). She has been under follow-up for 1.5 years without recurrence (Fig. 1B, Fig. 2B).

BSS is an autosomal dominant disorder characterized by progressive, stigmatizing benign cutaneous neoplasms localized on the facial skin and the scalp.

Surgical excision and alternative destructive modalities were reported for BSS skin neoplasms.¹ The ideal goal of interventions is to remove lesions without scarring and dyspigmentation, still yet efficacious enough to prevent recurrences. Recently, topical sirolimus and imiquimod treatments were suggested as non-invasive approaches.^{1–4}

The first observation on the efficacy of imiquimod was reported in a case with Multiple Facial Trichoepitheliomas (MFT).⁴ Topical tretinoin was introduced in the 6th month to improve the penetration of imiquimod. This combination was continued till 3rd year. A retrospective study reported partial response after 32-weeks of imiquimod treatment in two BSS patients.² These treatment durations are significantly longer when compared to the approved indications of imiquimod (Table 1). In a single-subject case study, the efficacy of various treatments was evaluated. Two sites received either imiquimod or the combination of AFL and imiquimod. On the 3rd month, topical imiquimod wasn't

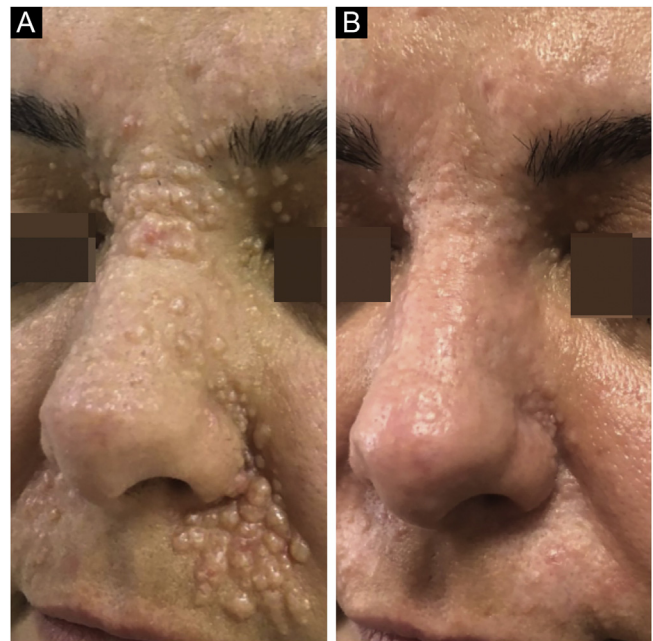

Figure 1 (A), On admission, multiple confluent, flesh-colored, infiltrated papules were detected on the nasal dorsum, bilateral alar grooves, and nasolabial regions. (B), At last control, the left nasolabial sulcus skin demonstrated a mild hypopigmentation. A prominent regression that was scored 80% by the patient was noted for the remaining parts receiving laser-assisted delivery of imiquimod.

[☆] Study conducted at the University of Health Sciences, Gulhane Training and Research Hospital, Department of Dermatology, Ankara, Turkey.