

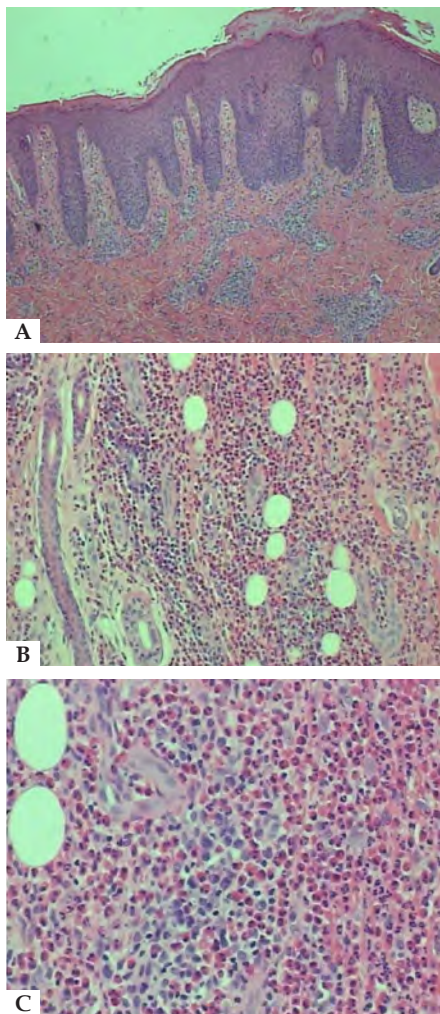FIGURE 2:
A - Skin showing acanthosis, parakeratosis and inflammatory infiltrate in superficial and deep dermis (Hematoxylin & eosin, x40),
B - Hypodermis with dense inflammatory infiltrate, predominantly eosinophilic (Hematoxylin & eosin, x100) and
C - Eosinophils in septa of subcutaneous adipose tissue (Hematoxylin & eosin, x200)

Histopathological changes of EP consist of intense infiltration of eosinophils in lobules and septa, extending to the reticular dermis or fascia. Flame figures and small areas of subcutaneous necrosis can also be found. Vasculitis is not usually seen by routine light microscopy.²

Once the diagnosis of EP has been established, associated clinical conditions should be investigated. Cases with infectious factors are more frequently related to toxocariasis and gnathostomiasis.² Considering the high prevalence of infestation in the Brazilian population, toxocariasis should always be considered when patients present eosinophilia and/or related symptoms. Human toxocariasis can be classified as visceral larva migrans, ocular and neurological larva migrans, asymptomatic toxocariasis and occult toxocariasis.⁵ In the classic systemic subtype, patients usually present fever, anemia, leukocytosis, nausea, hepatomegaly and pulmonary symptoms in addition to abnormalities in proteinogram, eosinophilia and positive serology. The serological diagnosis is made by ELISA, which uses *Toxocara* excretion-secretion antigens and has high sensitivity and specificity, varying according to the antigens tested. In the case reported here, the absence of hepatomegaly, fever, proteinogram changes and pulmonary symptoms excluded the classical form of toxocariasis. Conversely, eosinophilia, pruritus, cutaneous lesions, and lymphadenitis, as well as the ELISA test reagent for *Toxocara canis*

and the excellent response to therapy confirmed the occult subtype of toxocariasis.⁵ The treatment for toxocariasis may include albendazole, ivermectin or thiabendazole. The first medication is preferable due to better distribution through tissues after metabolized.

In endemic countries for toxocariasis, such as Brazil, the clinical presentation of pruritic nodules associated with eosinophilia should suggest the possibility of EP associated with toxocariasis. □

REFERENCES

1. Adame J, Cohen PR. Eosinophilic panniculitis: Diagnostic considerations and evaluation. *J Am Acad Dermatol.* 1996;34:229-34.
2. Winkelmann RK, Frigas E. Eosinophilic panniculitis: a clinicopathologic study. *J Cutan Pathol.* 1986;13:1-12.
3. Rook A, Staughton R. The Cutaneous Manifestations of Toxocariasis. *Dermatologica.* 1972;144:129-43.
4. Kraus A, Valencia X, Cabral AR, de la Vega G. Visceral larva migrans mimicking rheumatic diseases. *J Rheumatol.* 1995;22:497-500.
5. Carvalho EA, Rocha RL. Toxocariasis: visceral larva migrans in children. *J Pediatr (Rio J).* 2011;87:100-10.

AUTHORS' CONTRIBUTIONS

Julia Kanaan Recuero	ORCID 0000-0003-4308-2184
Conception and planning of the study; Elaboration and writing of the manuscript; Critical review of the literature	
Giovana Binda	ORCID 0000-0002-9127-6736
Conception and planning of the study; Elaboration and writing of the manuscript; Critical review of the literature	
Ana Elisa Kiszewski	ORCID 0000-0002-6287-6302
Approval of the final version of the manuscript; Elaboration and writing of the manuscript; Critical review of the manuscript	

How to cite this article: Recuero JK, Binda G, Kiszewski AE. Eosinophilic panniculitis associated with toxocariasis in a child. *An Bras Dermatol.* 2019;94(2): 250-1.

Dercum's disease: a rare and underdiagnosed disease*

Juliana D'Andrea Molina¹
 Gisele Alborghetti Nai¹
 Tatiana Cristina Pedro Cordeiro de Andrade¹
 Marilda Aparecida Milanez Morgado de Abreu¹

DOI: <http://dx.doi.org/10.1590/abd1806-4841.20198231>

Received 26 February 2018.

Accepted 23 June 2018.

* Work conducted at the Hospital Regional de Presidente Prudente, Universidade do Oeste Paulista, Presidente Prudente (SP), Brazil.

Financial support: None.

Conflict of interest: None.

¹ Dermatology Service, Hospital Regional de Presidente Prudente, Universidade do Oeste Paulista, Presidente Prudente (SP), Brazil.

MAILING ADDRESS:

Juliana D'Andrea Molina

E-mail: julianadandrea@gmail.com

©2019 by Anais Brasileiros de Dermatologia



Dear Editor,

Dercum's disease, or adiposis dolorosa, is a rare entity, characterized by overweight or obesity and the appearance of multiple painful lipomas, mainly in the upper limbs and trunk. By definition, the pain is chronic, with a duration of at least 3 months, symmetrical and generally resistant to conventional analgesics.¹ We report a typical case, with a good response to the surgical treatment, of a 76-year-old female, menopausal, obese (BMI=37) patient with arterial hypertension, hypertriglyceridemia and glaucoma, with painful nodules on the back and upper limbs for approximately twenty years. She reported growth of some nodules and increase in number over time. In the investigation of other symptoms, she denied depressive symptoms, chronic fatigue or associated sleep disorders. She reported only severe pain in three upper limb nodules and one in the back. On physical examination, she presented skin-colored subcutaneous nodules all over the upper limbs and on the back (Figures 1 and 2). Surgical removal of the painful nodules and anatomo-

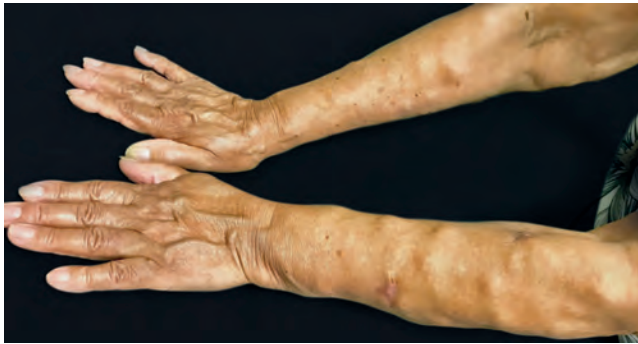

FIGURE 1: Nodules covered by normal-looking skin all over the upper limbs

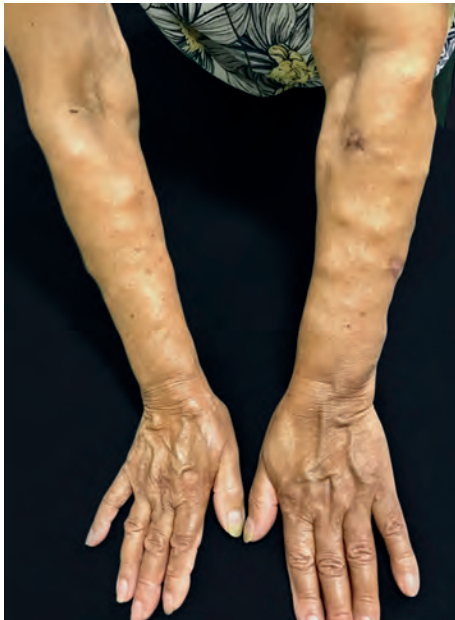

FIGURE 2: Nodules covered by normal-looking skin all over the upper limbs

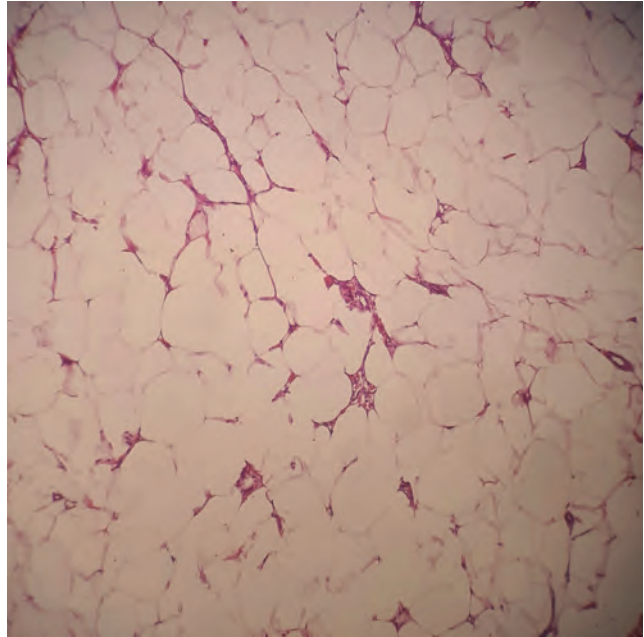


FIGURE 3: Photomicroscopy of a subcutaneous lesion. Mature adipose tissue with many capillaries (Hematoxylin and eosin, x100)

pathological examination were performed, which confirmed the proliferation of well differentiated and uniform adipocytes, sitting on a fibrovascular network, confirming the diagnosis of lipomas (Figure 3). After the surgical procedure, the patient had improvement in the pain and remains in outpatient care, with no signs of recurrence after 7 months of follow-up.

Dercum's disease is a rare entity, and the different treatment strategies that exist are based on case reports, which justifies the importance of this report. Its exact pathophysiology is unknown, but several pathogenic hypotheses have been presented, including abnormalities in carbohydrate metabolism and decreased conversion of glucose to triglycerides in painful adipose tissue. Endocrine disorders have also been reported and pain may be related to microthromboses or peripheral nerve abnormalities.¹⁻³

It is inherited in an autosomal dominant pattern, with variable penetrance, but most cases are sporadic.¹ It mainly affects women in the postmenopausal period and is 5 to 30 times more frequent in females. Exact prevalence has not yet been defined.^{1,4} The diagnosis is clinical and rest on basic criteria that include overweight or generalized obesity and chronic pain (> 3 months) in the adipose tissue.^{1,5} In the past, asthenia and psychiatric symptoms such as depression, emotional instability and sleep disturbances were considered as cardinal symptoms and were part of the diagnostic criteria. However, because they were not found in all cases and it was difficult to establish their real relationship with the disease, now they are considered as symptoms correlated with adiposis dolorosa.¹ Based on the distribution of the affected adipose tissue and the association with lipomas, Dercum's disease is classified into 4 types: generalized diffuse (very painful adipose tissue without lipomas), generalized nodular (generalized pain in the adipose tissue, more intense inside and around the lipomas), localized nodular (painful adipose tissue





exclusively within and around lipomas) and juxta-articular (deposition of painful solitary fat in the proximity of large joints).² The treatment aims to relieve pain and correct disfigurement. Medications, surgery and psychiatric care should be used in combination. Among the therapeutic options are the use of analgesics, non-steroidal anti-inflammatory drugs and opioids with variable response. The use of intralesional lidocaine in the form of adhesives or intravenous, seems to alleviate pain by regulating a possible hyperactivity of the sympathetic nervous system.^{1,3} Liposuction and lipectomy are effective in reducing symptoms and have the same efficacy in removing lipomas, alleviating pain and correcting disfigurement and associated psychiatric disorders, but with a risk of recurrence.¹ About the prognosis, there is little research done on the natural history of Dercum's disease, but case reports have suggested that pain may be aggravated over time.¹ There is a need to become familiar with this entity so that it is not an underdiagnosed condition anymore.⁴

This report describes a typical presentation of Dercum's disease in a female, obese and menopausal patient, with the development of painful lipomas mainly in the extremities and trunk, who had satisfactory control of symptoms with lipectomy. An overview of the pathogenesis, diagnosis and treatment of this rare and poorly understood disease is also presented. Because it is a rare disease with limited therapeutic options, the treatment modality chosen in this case is presented, which yielded a good result. The importance of new studies is also emphasized, which may help to understand its real etiology and the implementation of treatments capable of acting early, blocking the pathophysiological mechanisms. □

REFERENCES

- Hansson E, Svensson H, Brorson H. Review of Dercum's disease and proposal of diagnostic criteria, diagnostic methods, classification and management. *Orphanet J Rare Dis.* 2012;7:23.
- Desai MJ, Siriki R, Wang D. Treatment of pain in Dercum's disease with Lidoderm (lidocaine 5% patch): a case report. *Pain Med.* 2008;9:1224-6.
- Kosseifi S, Anaya E, Dronovalli G, Leicht S. Dercum's disease: an unusual presentation. *Pain Med.* 2010;11:1430-4.
- Rosmaninho A, Pinto-Almeida T, Fernandes IC, Machado S, Selores M. Do you know this syndrome?. *An Bras Dermatol.* 2012;87:324-5.
- Martinenghi S, Caretto A, Losio C, Scavini M, Bosi E. Successful treatment of Dercum's disease by transcutaneous electrical stimulation. *Medicine (Baltimore).* 2015;94:e950.

AUTHORS' CONTRIBUTIONS

Juliana D'Andrea Molina	 ORCID 0000-0001-9261-5739
Conception and planning of the study; Elaboration and writing of the manuscript; Critical review of the manuscript	
Gisele Alborghetti Nai	 ORCID 0000-0003-1674-7371
Intellectual participation in propaedeutic and/or therapeutic conduct of the cases studied	
Tatiana Cristina Pedro Cordeiro de Andrade	 ORCID 0000-0001-7804-2137
Critical review of the manuscript	
Marilda Aparecida Milanez Morgado de Abreu	 ORCID 0000-0001-9099-6013
Approval of the final version of the manuscript; Effective participation in research orientation; Critical review of the literature; Critical review of the manuscript	

How to cite this article: Molina JD, Nai GA, Andrade TCPC, Morgado de Abreu MAM. Dercum's disease: a rare and underdiagnosed disease. *An Bras Dermatol.* 2018;94(2): 251-3.

Kotatsu-induced erythema ab igne*

David Baltazar¹
Ross Brockman²
Eric Simpson²

DOI: <http://dx.doi.org/10.1590/abd1806-4841.20198792>

Erythema ab igne is a reticulated, hyperpigmented dermatosis that arises following chronic infrared exposure. It has been reported with prolonged exposure to heating pads or blankets, hot water bottles, heated furniture, laptop computers, prolonged bathing in hot water, open fires, and wood-burning stoves, among others.¹⁻³ It is usually asymptomatic and resolves with discontinuation of the offending heat source. There are several reported cases of neoplastic transformation occurring at the affected site.^{4,5}

A thirty-four-year-old Caucasian female presented to the dermatology clinic for routine follow-up. The patient had a history of alopecia totalis for the previous four years, which had been treated with a Janus kinase (JAK) inhibitor for the previous five months. The patient experienced regrowth of the majority of her scalp hair, eyebrows, and patches of leg hair. The patient's review of symptoms was essentially negative with the exception of a new rash on her bilateral medial thighs. Given her successful regrowth of hair, the patient was apprehensive that her JAK inhibitor would be discontinued given her developing skin rash. Physical examination of the bilateral medial thighs revealed reticulated, hyperpigmented-to-violaceous patches (Figure 1). The skin texture was normal, and there were no signs of venous stasis affecting the distal lower extremities. The patient was employed in computer science and worked primarily from home. She denied use of a laptop computer being placed on her lap or other common heat sources. However, she did report that for the previous two years she had been using a Japanese *kotatsu*

Received 14 September 2018.

Accepted 03 October 2018.

* Work conducted at the Western University of Health Sciences, Lebanon (OR), USA.

Financial support: None.

Conflict of interest: None.

¹ Department of Family Medicine, Western University of Health Sciences, Lebanon (OR), USA

² Department of Dermatology, Oregon Health and Science University, Portland (OR), USA

MAILING ADDRESS:

David Baltazar

E-mail: dbaltazar@westernu.edu

©2019 by Anais Brasileiros de Dermatologia

