

Financial support

None declared.

Authors' contributions

Miguel Santos Coelho: Data survey, data analysis and interpretation; drafting and editing of the manuscript; collection, analysis, and interpretation of data; intellectual participation in the propaedeutic and/or therapeutic conduct of the studied cases; critical review of the literature; approval of the final version of the manuscript.

Joana Alves Barbosa: Data survey, data analysis and interpretation; drafting and editing of the manuscript; collection, analysis, and interpretation of data; intellectual participation in the propaedeutic and/or therapeutic conduct of the studied cases; critical review of the literature; approval of the final version of the manuscript.

Margarida Moura Valejo Coelho: Critical review of the literature; approval of the final version of the manuscript.

Alexandre João: Data survey, data analysis and interpretation; collection, analysis, and interpretation of data; intellectual participation in the propaedeutic and/or therapeutic conduct of the studied cases; approval of the final version of the manuscript.

Conflicts of interest

None declared.

References

1. Forrestel AK, Kovarik CL, Katz KA. Sexually acquired syphilis: historical aspects, microbiology, epidemiology, and clinical manifestations. *J Am Acad Dermatol.* 2020;82:1–14.
2. Janier M, Unemo M, Dupin N, Tiplica GS, Potočník M, Patel R. 2020 European guideline on the management of syphilis. *J Eur Acad of Dermatol Venereol.* 2020;35:574–88.
3. Eccleston K, Collins L, Higgins SP. Primary syphilis. *Int J STD AIDS.* 2008;19:145–51.
4. Drago F, Ciccarese G, Cogorno L, Tomasini CF, Cozzani EC, Riva SF, et al. Primary syphilis of the oropharynx: an unusual location of a chancre. *Int J STD AIDS.* 2014;26:679–81.

Miguel Santos-Coelho *, Joana Alves Barbosa , Margarida Moura Valejo Coelho , Alexandre João 

Service of Dermatovenereology, Hospital de Santo António dos Capuchos, Centro Hospitalar Universitário de Lisboa Central, Lisbon, Portugal

* Corresponding author.

E-mail: mscoelho.derma@gmail.com (M. Santos-Coelho).

Received 6 August 2022; accepted 6 September 2022

Available online 6 December 2023

<https://doi.org/10.1016/j.abd.2022.09.018>

0365-0596/ © 2023 Sociedade Brasileira de Dermatologia.

Published by Elsevier España, S.L.U. This is an open access article under the CC BY license (<http://creativecommons.org/licenses/by/4.0/>).

Hypertrophic scar mimicking peristomal pyoderma gangrenosum[☆]



Dear Editor,

Peristomal Pyoderma Gangrenosum (PPG) is a subtype of pyoderma gangrenosum, arising around the stoma after surgical placement of an ileostomy or colostomy in patients with inflammatory bowel diseases.¹ Because there are a number of skin disorders involving the peristomal or parastomal areas, PPG may be overdiagnosed.² We herein describe an unusual case presenting with hyperkeratotic lesions around the stoma in a patient after colorectal cancer surgery.

A 78-year-old male after colorectal cancer surgery was referred to us, complaining of hypertrophic lesions surrounding the stoma. He received a colostomy 6-months previously, and peristomal skin lesions gradually worsened in these 2-months. He suffered from exudate from the lesions and pain associated with skin infections. Physical examination showed relatively well-circumscribed vegetating and kera-

totic lesions around the lower left abdominal stoma (Fig. 1). No abnormalities were found in the blood test.

Histological features showed irregular hypertrophy of the epidermis, with dilated blood vessels in the papillary dermis and edematous upper dermis (Fig. 2A). Neutrophil infiltration and histological malignancy were not observed. Immunohistochemistry showed dense staining for vimentin in the mesenchymal cells in the dermis (Fig. 2B). CD31 staining showed a number of vessels, and CD31-positive vascular endothelial cells were observed throughout the dermis (Fig. 2C). α -Smooth Muscle Actin (SMA)-positive myofibroblasts were proliferated (Fig. 3A), which were partially positive for p16 (Fig. 3B). A diagnosis of hypertrophic scar was made, and the patient received reoperation of the stoma including the surrounding skin lesions.

Peristomal pyoderma gangrenosum is a subtype of pyoderma gangrenosum, arising around the stoma in patients with inflammatory bowel diseases, and is observed in around 1% of patients with stoma.¹ By contrast, it is also suggested that PPG is overdiagnosed from its clinical features.² Currently, there are no standard diagnostic criteria, and there are several conditions that should be differentiated from PPG. Those conditions include irritant and contact dermatitis, infection, overgranulation, pseudo verrucous lesion, and squamous cell carcinoma.³ In addition, other reports showed two cases of peristomal ulcerative conditions, which were eventually reclassified to be caused by irritant dermatitis;⁴

[☆] Study conducted at the Department of Dermatology, Fukushima Medical University, Hikarigaoka, Fukushima, Japan.

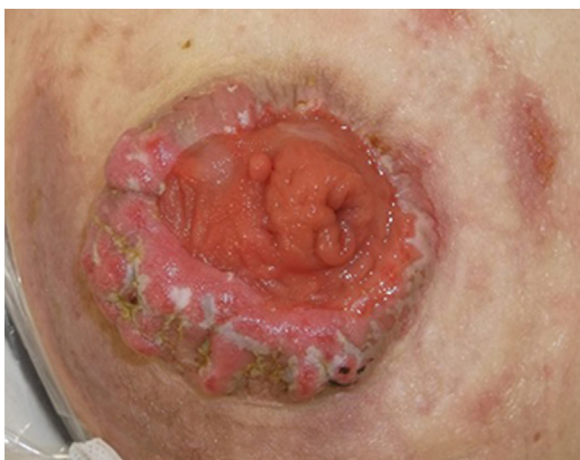

Figure 1 Hyperkeratotic lesions presenting with well-circumscribed vegetating and keratotic appearances surrounding the stoma.

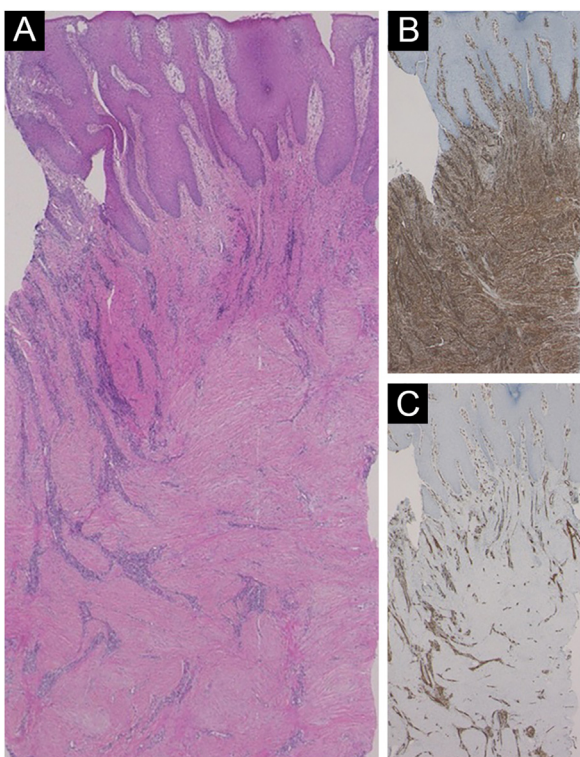


Figure 2 (A) Histopathological features showing fibrosis of the thickened dermis. (B) Immunohistochemical examination using anti-vimentin antibody showed proliferation of mesenchymal cells. (C) The vessels in the dermis were increased in number, which were positive for CD31.

however, the hypertrophic scar was not included. The present case did not present with surrounding ulcers but hyperkeratotic lesions around the stoma. Histopathological examination did not reveal neutrophil infiltration in the dermis, but increased, thickened, and whorled collagen bundles, and a number of CD31-positive vessels throughout the dermis. Recent studies demonstrated strong expression of vimentin, α -SMA, and p16 in the hypertrophic/keloid scars,

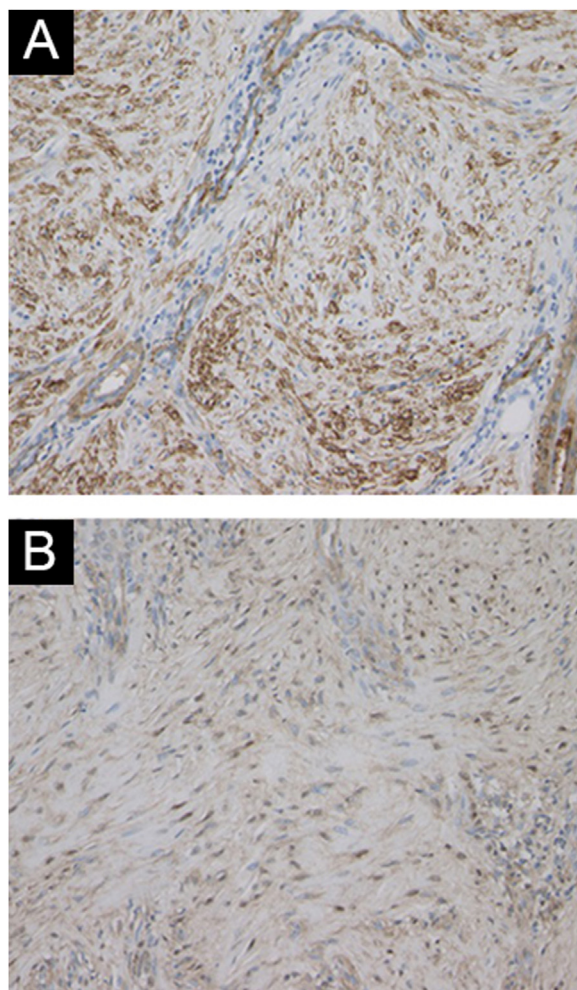


Figure 3 Myofibroblasts were increased in number, which were positively stained with α -SMA (A), and partially positive for p16 (B).

suggesting the proliferation of cellular senescence phase myofibroblasts.⁵ We should keep in mind that a number of inflammatory conditions assume clinical appearance mimicking PPG, and careful differentiation from other disorders is necessary for accurate diagnosis of PPG.

Financial support

None declared.

Authors' contributions

Takashi Ito: Conducted the dermatological examination and treatment of the patient, and wrote a draft of the manuscript.

Toshiyuki Yamamoto: Substantial contribution for interpretation, revision, and final approval.

Conflicts of interest

None declared.

References

1. Afifi L, Sanchez IM, Wallace MM, Braswell SF, Ortega-Loayza AG, Shinkai K. Diagnosis and management of peristomal pyoderma gangrenosum: a systematic review. *J Am Acad Dermatol*. 2018;78:1195–204, e1.
2. Le ST, Wang JZ, Alexanian C, Ellis S, Martinez-Alvarado YC, John S, et al. Peristomal pyoderma gangrenosum: an exceedingly rare and overdiagnosed entity? *J Am Acad Dermatol*. 2019;81:e15.
3. Almutairi D, LeBlanc K, Alavi A. Peristomal skin complications: what dermatologists need to know. *Int J Dermatol*. 2018;57:257–64.
4. Barton VR, Le ST, Wang JZ, Toussi A, Sood A, Maverakis E. Peristomal ulcers misdiagnosed as pyoderma gangrenosum: a common error. *J Eur Acad Dermatol Venereol*. 2020;34:e108–10.
5. Limandjaja GC, Belien JM, Scheper RJ, Niessen FB, Gibbs S. Hypertrophic and keloid scars fail to progress from the CD34-/α-smooth muscle actin (α-SMA)+ immature scar phenotype and show gradient differences in α-SMA and p16 expression. *Br J Dermatol*. 2020;182:974–86.

Takashi Ito *, Toshiyuki Yamamoto 

Department of Dermatology, Fukushima Medical University, Hikarigaoka, Fukushima, Japan

* Corresponding author.

E-mail: takashi1@fmu.ac.jp (T. Ito).

Received 10 March 2022; accepted 16 July 2022

Available online 14 December 2023

<https://doi.org/10.1016/j.abd.2022.07.012>

0365-0596/ © 2023 Published by Elsevier España, S.L.U. on behalf of Sociedade Brasileira de Dermatologia. This is an open access article under the CC BY license (<http://creativecommons.org/licenses/by/4.0/>).

Is Merkel cell carcinoma associated with high and chronic arsenic dose exposure?*



Dear Editor,

Merkel cell carcinoma (MCC) is a highly aggressive primary cutaneous tumor of neuroendocrine origin. It occurs predominantly in Caucasian male adults in photo-exposed areas. Despite being a rare tumor with an incidence of 0.1–1.6 cases per 100,000 inhabitants, diagnostic yield has increased these numbers.¹ We present a Hispanic man in his 70s from the Northern region of Mexico, known for high levels of arsenic in its water, presented at our clinic for evaluation of a localized dermatosis. He had a family history of maternal breast cancer and stomach cancer in his 2 sisters. Physical examination revealed multiple painless and rapidly growing flesh-colored and red-violaceous nodules on the right axillary region (Fig. 1). This began 2 months prior, accompanied by weight loss and fatigue. He had not sought medical attention before. Dermoscopic findings (polarized light) demonstrated milky pink and white structureless areas. An excisional skin biopsy was performed (Fig. 1). Histopathology revealed a flattened epidermis due to a nodular infiltrate located in the papillary and reticular dermis. At a higher magnification, the cluster of cells appeared monotonous with an epithelioid/lymphomyeloid appearance with abundant mitosis. Most cells had a loss of the nucleus-to-cytoplasm ratio, but they still retained an abundant cytoplasm with a prominent nucleus. Immunohistochemistry stained positive for AE1/AE3, CK20 (Fig. 2), and synaptophysin. Negative immunohistochemistry included CK7, SOX-10, S100, HMB45, CD45, TTF-1, vimentin. The clinical, pathological and immunohistochemical findings were consistent with Merkel cell carcinoma. Merkel cell carcinoma

has been associated with exposure to ultraviolet radiation, immunosuppression, and polyomavirus infection.² Diagnosis is made with immunohistochemistry which also helps make a distinction from histologically similar tumors. Dermatopathology shows a nodular or diffuse infiltrate composed of small blue cells with hyperchromatic nuclei and scarce cytoplasm. Mitoses are frequently abundant, and apoptosis is often widespread. 2 AE1/AE3, CK20, synaptophysin chromogranin, neuron-specific enolase and neurofilament stains are positive; CK7, TTF1, CDX2, S100, CD45, and vimentin are negative.² The main differential diagnoses before immunohistochemistry include metastatic neuroendocrine carcinoma (TTF1+, CK7+, CK20–), small cell melanoma (S100+, Melan-A/MART1+, HMB45*, SOX10*, vimentin+, CK20–) and lymphoma (CD45+, CD43+, CD3+, CD20+, CK20–, chromogranin–, synaptophysin–).² Exposure to high rates of arsenic in the environment or from contaminated water has been associated with an increased incidence of malignancies. Very few MCC cases (a total of 14) have been associated with arsenic.^{3–5} The treatment of choice in the early stages is surgical excision accompanied by radiotherapy. In advanced stages, there is no established curative therapy, relying on palliative chemotherapy.² It has a low survival rate even when tumors are localized or treated with new therapies such as immunotherapy targeting Programmed cell Death-1 (PD-1) or its Ligand (PD-L1).¹ Our patient refused to receive any therapies. He developed cutaneous metastasis and involvement of internal organs in one month and died two months later. The patient's family and personal history of malignancies made us rethink the relationship between the environment in his native region and the development of Merkel carcinoma. They were native to Torreon, Coahuila, Mexico, a geographic zone with high arsenic levels. More objective evidence is required regarding this possible association. We intend to awaken an interest on Merkel pathogenesis and environmental factors.

Financial support

None declared.

* Study conducted at the Dermatology Department, Universidad Autonoma de Nuevo Leon, Facultad de Medicina y Hospital Universitario "Dr. José E. Gonzalez", Monterrey, Mexico.