

## Conflicts of interest

None declared.

## References

1. Park SW, Lee DY, Mun GH. Longitudinal melanonychia on the lateral side of the nail: a sign of Bowen disease associated with human papillomavirus. *Ann Dermatol*. 2013;25:378–9.
2. Khan K, Mavanur AA. Longitudinal melanonychia. *BMJ Case Rep*. 2015;10, bcr2015213459.
3. Sass U, André J, Stene JJ, Noel JC. Longitudinal melanonychia revealing an intraepidermal carcinoma of the nail apparatus: detection of integrated HPV-16 DNA. *J Am Acad Dermatol*. 1998;39:490–3.
4. Shimizu A, Tamura A, Abe M, Amano H, Motegi S, Nakatani Y, et al. Human papillomavirus type 56-associated Bowen disease. *Br J Dermatol*. 2012;167:1161–4.
5. Stewart TJ, Farrell J, Crainic O, Rosen RH. A large series of pigmented Bowen's disease. *Int J Dermatol*. 2020;59:e316–7.
6. Benati E, Ribero S, Longo C, Piana S, Puig S, Carrera C, et al. Clinical and dermoscopic clues to differentiate pigmented nail bands: an International Dermoscopy Society study. *J Eur Acad Dermatol Venereol*. 2017;31:732–6.
7. Kurita R, Togawa Y, Suehiro K, Matsue H. A case of pigmented Bowen disease on the finger mimicking melanoma showing a chaos pattern on dermoscopy. *Dermatol Pract Concept*. 2020;10, e2020079.
8. Hirata SH, Yamada S, Enokihara MY, Di Chiacchio N, de Almeida FA, Enokihara MM, et al. Patterns of nail matrix and bed of lon-

gitudinal melanonychia by intraoperative dermoscopy. *J Am Acad Dermatol*. 2011;65:297–303.

9. Göktay F, Güneş P, Yaşar Ş, Güder H, Aytakin S. New observations of intraoperative dermoscopic features of the nail matrix and bed in longitudinal melanonychia. *Int J Dermatol*. 2015;54:1157–62.
10. Teyssie S, Dalle S, Duru G, Phan A, Debarbieux S, Poulhalon N, et al. Dermoscopic features of subungual squamous cell carcinoma: a study of 44 cases. *Dermatology*. 2017;233:184–91.

Guilherme de Medeiros Holanda <sup>a</sup>,  
Guilherme Raya Ravelli <sup>b,\*</sup>,  
Bruno de Carvalho Fantini <sup>a</sup>, Cacilda da Silva Souza <sup>a</sup>

<sup>a</sup> *Division of Dermatology, Department of Internal Medicine, Ribeirão Preto Faculty of Medicine, Universidade de São Paulo, Ribeirão Preto, SP, Brazil*

<sup>b</sup> *Department of Pathology and Forensic Medicine, Ribeirão Preto Faculty of Medicine, Universidade de São Paulo, Ribeirão Preto, SP, Brazil*

\* Corresponding author.

E-mail: [guiholanda@hotmail.com](mailto:guiholanda@hotmail.com) (G.R. Ravelli).

Received 4 November 2021; accepted 10 January 2022

Available online 16 May 2023

<https://doi.org/10.1016/j.abd.2022.01.018>

0365-0596/ © 2023 Published by Elsevier España, S.L.U. on behalf of Sociedade Brasileira de Dermatologia. This is an open access article under the CC BY license (<http://creativecommons.org/licenses/by/4.0/>).

## Meyerson nevus triggered by COVID-19<sup>☆</sup>



Dear Editor,

Meyerson's nevus is an eczematous reaction on a melanocytic nevus. This reaction can also affect other types of lesions such as congenital nevi, dysplastic nevi, melanoma, and non-melanocytic lesions, in which case it is called Meyerson's phenomenon. It may be restricted to a single melanocytic nevus or affect several melanocytic nevi. In a small percentage of cases, it is accompanied by eczematous lesions in other locations. It usually resolves spontaneously or after treatment with topical corticosteroids. Its pathogenesis is not clear, and no triggers have been identified in most cases, although cases have been reported after sunburn or treatment with interferon-alpha alone or combined with ribavirin.<sup>1</sup>

Multiple cutaneous manifestations caused by COVID-19 have been described. However, its pathogenesis remains unclear. They have been attributed to an inflammatory mechanism, due to an immune response against viral nucleotides, and to a vascular mechanism, secondary to vasculitis or thrombosis.<sup>2</sup> After a rigorous search of the lit-

erature, the authors did not find any case of Meyerson's nevus associated with COVID-19 infection or vaccination.

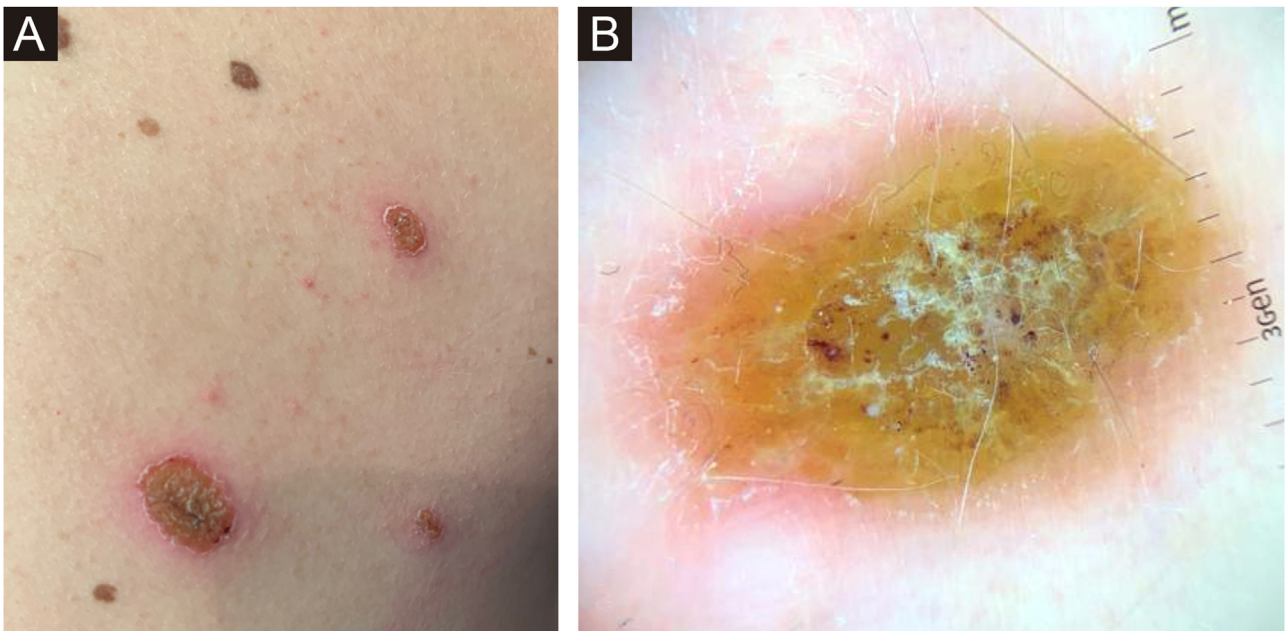
The authors present the case of a 34-year-old man with no medical history of interest who presented to the dermatology department with erythematous-squamous lesions and crusting over approximately half of his melanocytic nevi on the trunk (Fig. 1A). Visualization of dermoscopic structures was difficult due to the presence of serous crusting, slight whitish scaling, and an erythematous halo (Fig. 1B). The previous ten days he had suffered an uncomplicated upper respiratory tract infection due to COVID-19. The patient had not experienced similar lesions after SARS-CoV-2 vaccination or after previous infectious processes. Nor had he introduced any new drugs.

A biopsy of one of the lesions revealed nevus cells arranged in small thecae with adequate maturation without signs of dysplasia, surrounded by lymphocyte-predominant inflammatory infiltrate (55% CD4+, 45% CD8+) and marked spongiosis (Fig. 2).

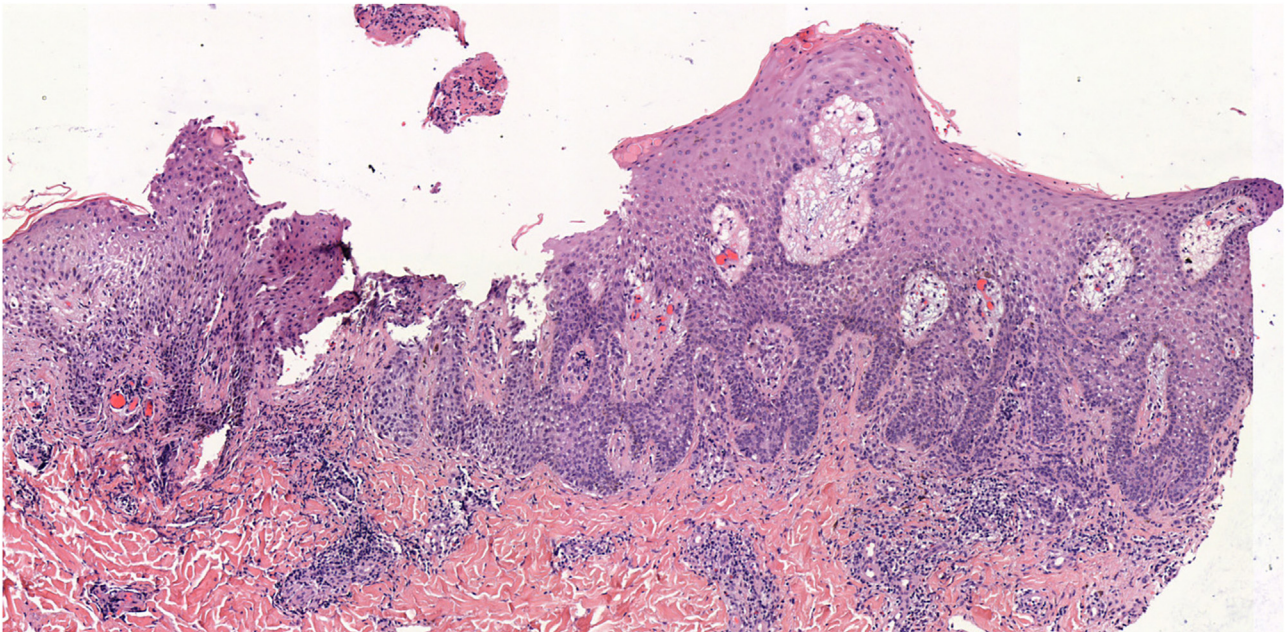
It was diagnosed as Meyerson nevus triggered by COVID-19 infection. The lesions resolved after topical corticosteroid treatment (methylprednisolone acetate once daily for two weeks) and have not recurred to date. The affected nevi show a typical pigmented reticular pattern at present.

As for nevocentric dermatoses in relation to SARS-CoV-2, a case of nevocentric erythema multiforme three days

<sup>☆</sup> Study conducted at the Department of Dermatology, University Hospital of León, León, Spain.



**Fig. 1** (A) Erythematous-squamous lesions and crusting over approximately half of his melanocytic nevi on the trunk. (B) Visualization of dermoscopic structures was difficult due to the presence of serous crusting, slight whitish scaling, and an erythematous halo



**Fig. 2** Biopsy of one of the lesions revealed nevus cells arranged in small thecae with adequate maturation without signs of dysplasia, surrounded by lymphocyte-predominant inflammatory infiltrate and marked spongiosis (Hematoxylin & eosin,  $\times 50$ )

after COVID-19 vaccination (Comirnaty™ – BioNTech/Pfizer – Mainz, Germany/New York, NY, USA) has recently been reported.<sup>3</sup> This is a different entity than Meyerson's phenomenon, but the pathogenesis of both could involve an interaction between Intercellular Cell Adhesion Molecule 1 (ICAM-1) and CD4 T-cells. ICAM-1 expression would be stimulated by certain interferons.<sup>4</sup> SARS-COV-2 has proved to induce a type I interferon response in a subgroup of patients with mild disease,<sup>5</sup> as in the case of our patient.

This mechanism has been associated with the development of different autoimmune processes triggered by viruses and could explain the development of a Meyerson nevus coinciding with COVID-19 infection.

In conclusion, COVID-19 infection, through a mechanism mediated by ICAM-1 and interferon, could trigger Meyerson's nevus. The authors encourage the reporting of this type of skin reaction in order to consider their inclusion among the possible cutaneous manifestations related to COVID-19.



## Financial support

None declared.

## Authors' contributions

Rubén Linares-Navarro: Approval of the final version of the manuscript; critical literature review; data collection, analysis, and interpretation; effective participation in research orientation; intellectual participation in propaedeutic and/or therapeutic; management of studied cases; manuscript critical review; preparation and writing of the manuscript; study conception and planning.

Pedro Sánchez-Sambucety: Approval of the final version of the manuscript; critical literature review; data collection, analysis, and interpretation; effective participation in research orientation; intellectual participation in propaedeutic and/or therapeutic; management of studied cases; manuscript critical review; preparation and writing of the manuscript; study conception and planning.

Manuel Ángel Rodríguez-Prieto: Approval of the final version of the manuscript; critical literature review; data collection, analysis, and interpretation; effective participation in research orientation; intellectual participation in propaedeutic and/or therapeutic; management of studied cases; manuscript critical review; preparation and writing of the manuscript; study conception and planning.

## Conflicts of interest

None declared.

## References

1. Pižem J, Stojanović L, Luzar B. Melanocytic lesions with eczematous reaction (Meyerson's phenomenon) - a histopathologic analysis of 64 cases: melanocytic lesions with eczematous reaction. *J Cutan Pathol.* 2012;39:901–10.
2. Seque CA, Enokihara MMSS, Porro AM, Tomimori J. Skin manifestations associated with COVID-19. *An Bras Dermatol.* 2022;97:75–88.
3. Scharf C, Di Brizzi EV, Pellerone S, Liguori M, Giorgio CMR, Argenziano G. Nevocentric erythema multiforme after SARS-CoV-2 vaccine. *J Eur Acad Dermatol Venereol.* 2022;36:e30–2.
4. Loh J, Kenny P. Meyerson phenomenon. *J Cutan Med Surg.* 2010;14:30–2.
5. Knight JS, Caricchio R, Casanova JL, Combes AJ, Diamond B, Fox SE, et al. The intersection of COVID-19 and autoimmunity. *J Clin Invest.* 2021;131:e154886.

Rubén Linares-Navarro \*, Pedro Sánchez-Sambucety , Manuel Ángel Rodríguez-Prieto 

*Department of Dermatology, University Hospital of León, León, Spain*

\*Corresponding author.

E-mail: [rlinares@saludcastillayleon.es](mailto:rlinares@saludcastillayleon.es) (R. Linares-Navarro).

Received 19 September 2022; accepted 8 November 2022  
Available online 27 April 2023

<https://doi.org/10.1016/j.abd.2022.11.002>

0365-0596/ © 2023 Sociedade Brasileira de Dermatologia.

Published by Elsevier España, S.L.U. This is an open access article under the CC BY license (<http://creativecommons.org/licenses/by/4.0/>).

## Multinucleate cell angiohistiocytoma: a diagnostic challenge<sup>☆</sup>



Dear Editor,

A 33-year-old male patient presented with multiple erythematous-brown papules measuring 1 to 5 mm, disseminated on the upper limbs, trunk and thighs (Fig. 1). Dermoscopy disclosed the presence of a peripheral network and a central homogeneous pink area (Fig. 2). The condition had started two years before when he sought another Service and received a diagnosis of secondary syphilis, confirmed by non-treponemal (VDRL 1:64) and treponemal tests (positive FTA-ABS). He was treated on two occasions with three doses of benzathine penicillin, with no improvement of the skin condition (VDRL after treatments - 1:16). Diagnostic hypotheses were made of generalized multinucleate cell angiohistiocytoma (MCA) and eruptive dermatofibromas.

Histopathology showed proliferated capillary vessels with dilated lumen (Fig. 3A) and multinucleate giant

cells with ample cytoplasm interspersed with fibroblasts, lymphocytes, and histiocytes (Figs. 3B and 3C). Immunohistochemical analysis showed: immunoexpression of CD138 in the cytoplasmic membrane of the interstitial plasmocytes that permeated the lymphoid aggregates (Fig. 4A); cytoplasmic immunoexpression of Factor XIIIa in spiky multinucleate giant cells (Fig. 4B); positive expression of CD68 and CD163 in dermal histiocytes and negative in endothelial cells; CD31 positivity in the vascular component and negative immunoexpression of S100, establishing the diagnosis of MCA.

After he was instructed about the condition, the patient chose not to undergo treatment for aesthetic purposes and returned after one year with spontaneous significant improvement in the number, pigmentation, and size of the lesions (Fig. 5).

## Discussion

Multinucleate cell angiohistiocytoma is a rare benign fibrous histiocytic proliferation, described in 1985.<sup>1</sup> It often presents as well-circumscribed, dome-shaped erythematous-brown papules clustered on the hands, wrists, face, or legs. Localized, multifocal and generalized variants have been described, with the localized variant being the most common. Approximately 150 reported cases were

<sup>☆</sup> Study conducted at the Universidade Federal de São Paulo, São Paulo, SP, Brazil.