

## Financial support

None declared.

## Authors' contributions

Hiram Larangeira de Almeida Jr: Approval of the final version of the manuscript; design and planning of the study; drafting and editing of the manuscript; collection, analysis and interpretation of data; effective participation in research orientation; intellectual participation in the propaedeutic and/or therapeutic conduct of the studied cases; critical review of the literature; critical review of the manuscript.

Vitor Dias Furtado: Approval of the final version of the manuscript; design and planning of the study; drafting and editing of the manuscript; collection, analysis and interpretation of data; intellectual participation in the propaedeutic and/or therapeutic conduct of the studied cases; critical review of the literature; critical review of the manuscript.

Viviane Siena Issaacson: Approval of the final version of the manuscript; design and planning of the study; drafting and editing of the manuscript; collection, analysis and interpretation of data; intellectual participation in the propaedeutic and/or therapeutic conduct of the studied cases; critical review of the literature; critical review of the manuscript.

Ana Leticia Boff: Approval of the final version of the manuscript; design and planning of the study; drafting and editing of the manuscript; collection, analysis and interpretation of data; intellectual participation in the propaedeutic and/or therapeutic conduct of the studied cases; critical review of the literature; critical review of the manuscript.



## Conflicts of interest

None declared.

## References

1. Klein B, Treudler R, Simon JC. JAK-inhibitors in dermatology - small molecules, big impact? Overview of the mechanism of action, previous study results and potential adverse effects. *J Dtsch Dermatol Ges.* 2022;20:19–24.

2. Xin P, Xu X, Deng C, Liu S, Wang Y, Zhou X, et al. The role of JAK/STAT signaling pathway and its inhibitors in diseases. *Int Immunopharmacol.* 2020;80:106210.
3. Dhillon S. Tofacitinib: a review in rheumatoid arthritis. *Drugs.* 2017;77:1987–2001.
4. Fragoulis GE, McInnes IB, Siebert S, JAK-inhibitors. New players in the field of immune-mediated diseases, beyond rheumatoid arthritis. *Rheumatology (Oxford).* 2019;58 Suppl 1:i43–54.
5. Shindo H, Hide M. Neutrophilic lobular panniculitis with non-rheumatoid arthritis. *Acta Derm Venereol.* 2005;85:262–3.
6. Chan MP. Neutrophilic panniculitis: algorithmic approach to a heterogeneous group of disorders. *Arch Pathol Lab Med.* 2014;138:1337–43.
7. Magro CM, Crowson AN. The spectrum of cutaneous lesions in rheumatoid arthritis: a clinical and pathological study of 43 patients. *J Cutan Pathol.* 2003;30:1–10.
8. Sampaio AL, Bressan AL, Vasconcelos BN, Gripp AC. Skin manifestations associated with systemic diseases - Part I. *An Bras Dermatol.* 2021;96:655–71.
9. Kochar B, Herfarth N, Mamie C, Navarini AA, Scharl M, Herfarth HH. Tofacitinib for the treatment of Pyoderma Gangrenosum. *Clin Gastroenterol Hepatol.* 2019;17:991–3.

Hiram Larangeira de Almeida Junior  a,b,\*  
Vitor Dias Furtado  c, Viviane Siena Issaacson  d,  
Ana Leticia Boff  e

<sup>a</sup> Postgraduate Degree in Health and Behavior,  
Universidade Católica de Pelotas, Pelotas, RS, Brazil

<sup>b</sup> Department of Dermatology, Universidade Federal de Pelotas, Pelotas, RS, Brazil

<sup>c</sup> Faculty of Medicine, Universidade Federal de Pelotas, Pelotas, RS, Brazil

<sup>d</sup> Private Practice, Pelotas, RS, Brazil

<sup>e</sup> Santa Casa de Misericórdia de Porto Alegre, Porto Alegre, RS, Brazil

\* Corresponding author.

E-mail: [hiramalmeidajr@hotmail.com](mailto:hiramalmeidajr@hotmail.com)  
(H.L. Almeida Junior).

Received 1 April 2023; accepted 11 May 2023

<https://doi.org/10.1016/j.abd.2023.05.010>  
0365-0596/ © 2024 Sociedade Brasileira de Dermatologia.  
Published by Elsevier España, S.L.U. This is an open access article under the CC BY license (<http://creativecommons.org/licenses/by/4.0/>).

## Terbinafine as a successful treatment in primary cutaneous aspergillosis\*



Dear Editor,

Aspergillus is a ubiquitous saprophytic mold in nature and is commonly found in soil water and decaying vegetation. The

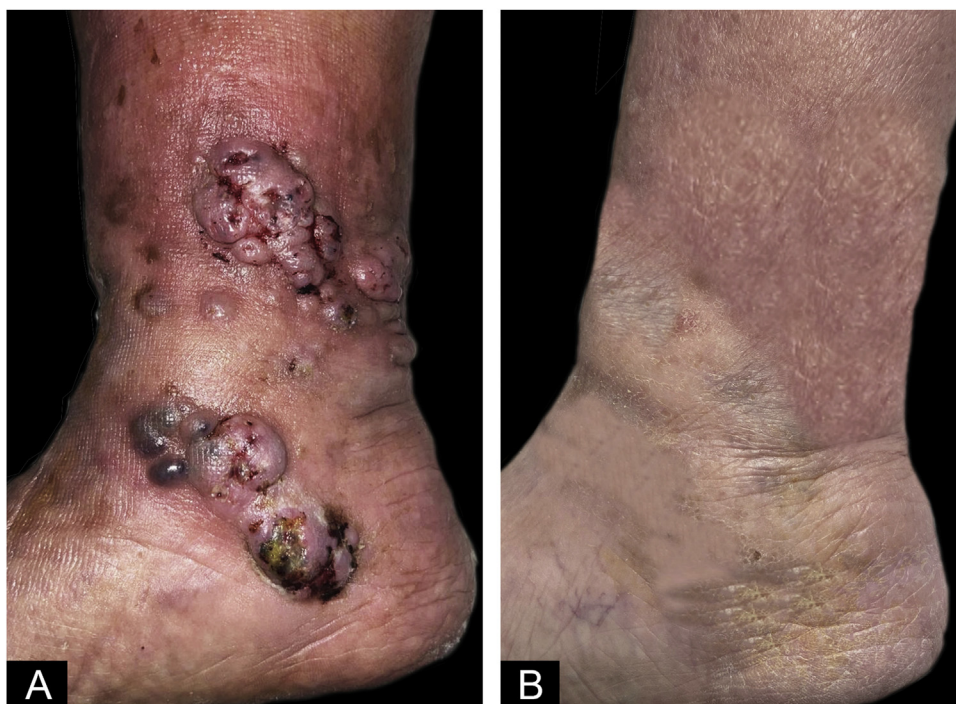most common human pathogens include *A. fumigatus* (85%), *A. flavus* (5%–10%) and *A. niger* (2%–3%).<sup>1</sup>

Aspergillosis usually occurs in immunocompromised hosts. Primary cutaneous aspergillosis (PCA) is a rare but life-threatening invasive fungal infection of the skin caused by *Aspergillus*. Due to its clinical heterogeneity, clinical suspicion should be high in immunosuppressed patients.<sup>1</sup>

The literature is replete with reports of PCA, however there is not a single reported case treated with terbinafine in monotherapy.

A 74-year-old man presented for evaluation of a mass in his right leg for a year. He had been under tacrolimus, prednisone, and mycophenolate mofetil treatment since 2012 because of a renal transplant. The patient denied any pre-

\* Study conducted at the Department of Dermatology, Hospital Universitario Virgen de Valme, Sevilla, Spain.



**Figure 1** Physical exploration: (A) Initial physical exploration. Nodules with superficial exulceration in the lower third of the right leg of 0.5–1 cm, coalescing with each other, forming 4–5 cm plaques. (B) Physical exploration after 3-months of terbinafine. Residual hyperpigmentation on right left.

vious trauma, but he had presented a torpid venous ulcer in the area. Physical examination revealed violaceous and skin-colored subcutaneous nodules with superficial exulceration in the lower third of the right leg (Fig. 1). A skin biopsy was performed, and samples were sent to the pathology and microbiology labs.

The skin biopsy showed septate hyphae with right angulation and vesiculation (Fig. 2A). These structures corresponded to the growth of colonies composed of *Aspergillus fumigatus* (Fig. 2B–C). Blood cultures, galactomannan antigen test, and a chest-abdominal CT scan were performed. The results of all tests were negative. After rejecting systemic involvement, the patient was definitively diagnosed with PCA.

Oral isavuconazole was started but it was suspended because of an important elevation of tacrolimus plasma levels. After that, the patient started terbinafine 250 mg/24h. The lesions disappeared leaving only residual hyperpigmentation after 3 months of treatment (Fig. 1). The presence of two negative cultures separated from each other by 3 months confirmed the resolution of the infection.

Currently, there are four classes of antifungal agents with activity against *Aspergillus*: 1) The polyenes, such as amphotericin B deoxycholate and nystatin, 2) The triazoles, including itraconazole, voriconazole, isavuconazole; 3) The echinocandins, such as caspofungin and micafungin and 4) The allylamines such as terbinafine.<sup>2</sup>

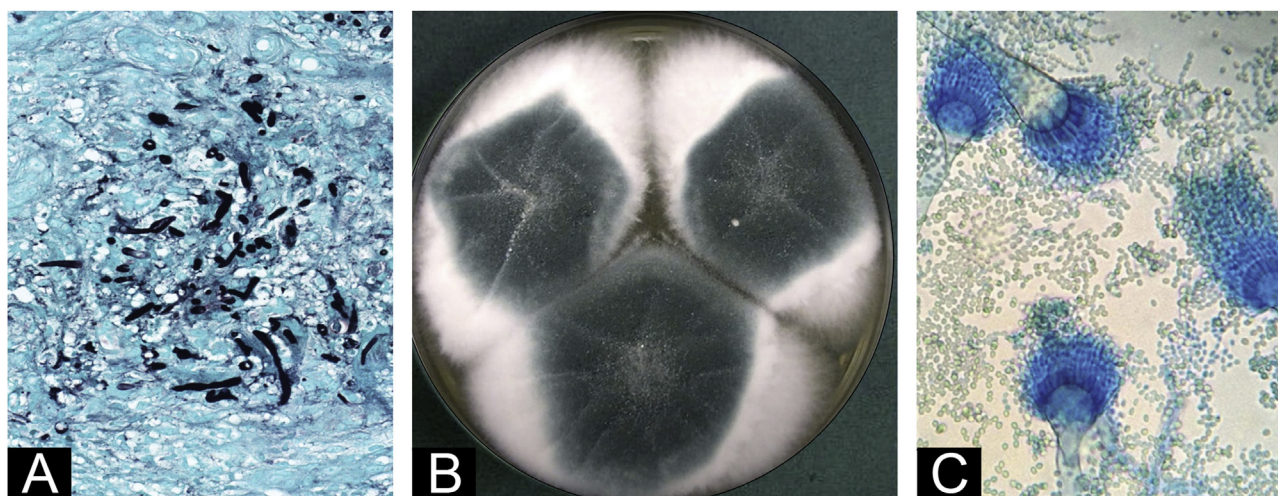
Until the early 1990s, amphotericin B deoxycholate was the only agent that was available for the management of this infection. However, the significant toxicities associated with this agent made it less attractive with the introduction

of newer agents such as the triazoles and the echinocandins, which are much better tolerated.<sup>2</sup>

Among these, isavuconazole proved to be superior in terms of response, toxicity and overall survival.<sup>2</sup> However, triazoles have been found to have inhibitory effects on hepatic cytochrome P450.<sup>3</sup> The inhibition of the cytochrome P450 can produce an important elevation of plasmatic levels of drugs that are metabolized by this route and can cause significant toxicities, as has happened with the tacrolimus that our patient was taking.

The other antifungals classically effective against *A. fumigatus* could also have had side effects on our patient. Amphotericin B deoxycholate is highly nephrotoxic and could have increased the nephrotoxicity in a kidney recipient transplant.<sup>2</sup> On the other hand, using caspofungin together with tacrolimus may have decreased the plasma levels of tacrolimus,<sup>4</sup> increasing the risk of kidney transplant loss.

Although it has been well-known for years that terbinafine is effective in vitro in aspergillosis, there are no published cases that have clinically demonstrated its efficacy in vivo. Importantly, because of its poor penetration in deep tissues, terbinafine is almost exclusively indicated for skin and nail infections.<sup>2</sup> Schmitt et al. demonstrated that concentrations between 0.8–1.6 µg/mL of terbinafine are sufficient to reach the Minimum Inhibitory and Fungicide Concentration (MIC and MFC) against *A. fumigatus* in a vitro study.<sup>5</sup> As claimed by its fact sheet, a 250mg single dose of terbinafine (standard dose marketed) is able to reach a serum concentration from 0.8 to 1.5 µg/mL two hours later after ingesting the pill.<sup>6</sup> Terbinafine can also penetrate excellently from blood to skin according to its pharmacokinetics.<sup>2</sup> As the concentration of terbinafine



**Figure 2** Supplementary tests: (A) Skin biopsy, (Grocot, 40×). Septate hyphae, with right angulation, vesiculation and pseudo-hyphae. (B) Microbiological culture of skin biopsy on dextrose agar. Colonies composed of a bluish-green central portion surrounded by a whitish foamy edge. (C) Lactophenol blue stained microscopy of microbiological culture. Septate hyaline hyphae were found with typical reproduction forms of *Aspergillus fumigatus*: aspergillate heads, with smooth and regular conidiophores, club-shaped vesicles covered in their upper third by uniseriate phialides that gave rise to smooth and globose conidia.

that is reached in plasma is very similar to the MIC of *Aspergillus*, terbinafine in monotherapy demonstrates good activity against *Aspergillus spp.* in the skin.<sup>6</sup>

Although further investigation is required, this unique case evidence that PCA could successfully be treated by terbinafine.

### Financial support

None declared.

### Authors' contributions

Juan Manuel Morón Ocaña: Preparation and writing of the manuscript; critical literature review.

Isabel María Coronel Pérez: Approval of the final version of the manuscript; manuscript critical review.

Elena-Margarita Rodríguez Rey: Approval of the final version of the manuscript; manuscript critical review.



### Conflicts of interest

None declared.

### References

1. Segal BH. Aspergillosis. *N Engl J Med.* 2009;360:1870–84.
2. Chamilos G, Kontoyiannis DP. Update on antifungal drug resistance mechanisms of *Aspergillus fumigatus*. *Drug Resist Updat.* 2005;8:344–58.

3. Niwa T, Imagawa Y, Yamazaki H. Drug interactions between nine antifungal agents and drugs metabolized by human cytochromes P450. *Curr Drug Metab.* 2014;15:651–79.
4. Drug Interactions Between Caspofungin and Tacrolimus. *Aspergillus and Aspergillosis.* [Cited 29 de marzo de 2023]. Available from: <https://www.aspergillus.org.uk/conference-abstracts/drug-interactions-between-caspofungin-and-tacrolimus/>.
5. Schmitt HJ, Bernard EM, Andrade J, Edwards F, Schmitt B, Armstrong D. MIC and fungicidal activity of terbinafine against clinical isolates of *Aspergillus spp.* *Antimicrob Agents Chemother.* 1988;32:780–1.
6. Krishnan-Natesan S. Terbinafine: a pharmacological and clinical review. *Expert Opin Pharmacother.* 2009;10:2723–33.

Juan-Manuel Morón-Ocaña \*,  
Isabel-María Coronel-Pérez ,  
Elena-Margarita Rodríguez-Rey 

Department of Dermatology, Virgen de Valme Hospital, Sevilla, Spain

\* Corresponding author.

E-mail: [juanm.moron.sspa@juntadeandalucia.es](mailto:juanm.moron.sspa@juntadeandalucia.es)  
(J. Morón-Ocaña).

Received 15 June 2023; accepted 10 July 2023

<https://doi.org/10.1016/j.abd.2023.07.011>

0365-0596/ Published by Elsevier España, S.L.U. on behalf of Sociedade Brasileira de Dermatologia. This is an open access article under the CC BY license (<http://creativecommons.org/licenses/by/4.0/>).