

# Martorell's hypertensive ulcer: case report\*

## *Úlcera hipertensiva de Martorell: relato de caso\**

Bruna Malburg Freire<sup>1</sup>Nurimar Conceição Fernandes<sup>2</sup>Juan Piñero-Maceira<sup>3</sup>

**Abstract:** *Martorell's hypertensive ulcer is a painful lower extremity ischemic ulcer, with female-to-male predominance and associated to severe systemic arterial hypertension. We describe a case of a 56 years-old black man with long standing and poorly controlled arterial hypertension who presented a large ulcer on the right calf, whose pain was improved with morphine, peridural blockages and lumbar sympathectomy. The diagnosis was based on systemic arterial hypertension, palpable arterial pulses of lower extremities, absence of venous insufficiency and presence of intense pain. Cutaneous histopathology revealed characteristic lesions in the arterioles, such as thickening of intimal layer and narrowing of the lumen.*

**Keywords:** *Hypertension; Leg ulcer; Skin ulcer*

**Resumo:** A úlcera hipertensiva de Martorell é úlcera isquêmica dolorosa de membro inferior, mais comum em mulheres, com dor desproporcional a seu tamanho e associada à hipertensão arterial sistêmica grave. É descrito um caso de homem negro, 56 anos, com hipertensão mal controlada de longa duração e lesão ulcerada extensa na panturrilha direita, cuja dor só foi aliviada com morfina, bloqueios peridurais e simpatectomia lombar. O diagnóstico baseou-se em hipertensão arterial, pulsos arteriais palpáveis, ausência de distúrbios venosos e dor intensa. O exame histopatológico de pele revelou alterações características, como espessamento da camada íntima da arteríola e estreitamento da luz.

**Palavras-chave:** Hipertensão; Úlcera cutânea; Úlcera da perna

### INTRODUCTION

Lower limb chronic ulcer may have various causes: traumatic, vascular, infectious, metabolic, hematologic, neurologic and neoplastic.<sup>1,2</sup> It is a condition of hard handling, for it involves several differential diagnoses, and many times response to treatment is slow.

Hypertensive ulcer was described in 1945 by Martorell as a complication of severe systemic arterial hypertension (SAH).<sup>3,4</sup> It is a round-shaped ulcer,

from 2 to 4 cm of diameter, with either granulous or necrotic bed, located in the inferior limb, generally in the outer inferior third of the leg. It is also extremely painful – disproportionately to the size of the lesion – with predominance among females between 50 and 60 years of age, with severe, long-lasting and badly controlled SAH.<sup>3,4</sup>

Given the scarcity of publications on issue in Brazil, a case is described, giving emphasis to diag-

Received on January 23, 2003.

Approved by the Consultive Council and accepted for publication on June 13, 2006.

\* Work done at the Department of Dermatology, Hospital Universitário Clementino Fraga Filho – HUCFF - Universidade Federal do Rio de Janeiro - UFRJ - Rio de Janeiro (RJ), Brazil.

Conflict of interest: None

<sup>1</sup> Medical Doctor, Graduate Student of Dermatology, Universidade Federal do Rio de Janeiro - UFRJ – Hospital Universitário Clementino Fraga Filho - HUCFF - Rio de Janeiro (RJ), Brazil.

<sup>2</sup> Associate Professor of Dermatology, Medical School, Universidade Federal do Rio de Janeiro - UFRJ – Hospital Universitário Clementino Fraga Filho - HUCFF - Rio de Janeiro (RJ), Brazil.

<sup>3</sup> Associate Professor of Pathology, Medical School, Universidade Federal do Rio de Janeiro - UFRJ – Hospital Universitário Clementino Fraga Filho - HUCFF - Rio de Janeiro (RJ), Brazil.

nostic and therapeutical difficulties of lower limb chronic ulcers.

### CASE REPORT

Fifty six-year-old black male patient, nursing assistant, born in the state of Paraíba, who had had severe hypertension since 15 years of age, also with poliomyelitis sequel in the right lower limb (RLL), which did not stop him from walking. He had also had acute myocardial infarction in 2000; denied to be a smoking, sickle cell anemia or *diabetes mellitus*, and was not obese. He was hospitalized in March 2002 with a very painful chronic ulcer in the RLL with one year and three months of evolution (with worsening over the previous three months). Initially it was round-shaped, perimaleolar, and extend to the entire calf, with necrotic areas, exposition of the tendon and secondary infection. He had a history of a previous similar lesion, four years before, in the left lower limb (LLL), which had healed with local care alone.

Upon examination he presented an extensive ulcerated lesion, measuring 10 x 25 cm, occupying the entire posterior portion of the right calf, exposing tendons and muscles in the two upper thirds; there was also necrosis and foul-smelling purulent secretion; and granulation tissue in the lower third (Figure 1). Peripheral pulses were palpable and wide. Presence of hyperchromic perimaleolar scar in LLL. Absence of signs of venous insufficiency. Arterial pressure (AP) of 190x120mmHg.

### Laboratorial tests

He exhibited norchromic and normocytic anemia, leukocytosis with left shift, HSV – 12 mm; normal blood glucose, creatinin clearance of 61ml/min; RLL

radiograph showing osteopeny, with no signs of osteomyelitis or tumoral bone affection; echocardiogram showing moderate hypertensive cardiopathy.

Biopsy 1 (three fragments) showed chronic ulcerated inflammatory process, with intense necrosis and predominantly mononuclear inflammatory reaction, along with pseudo-epitheliomatous hyperplasia and vascular alterations suggesting arteriosclerosis – an intense thickening of the intimal layer of the arterioles in the deep dermis (Figure 2). Biopsy 2 (progression area) presented chronic ulcerated inflammatory process, associated to vascular alterations suggesting arteriosclerosis and fat tissue necrosis.

### Treatment

Intravenous amoxicilin and clavulanate, besides paracetamol with codein as analgesic, propranolol, nifedipin and isosorbide dinitrate for AP control, and captopril and hydrochlorothiazide, which he already used, were initiated.

### Evolution

After 20 days of hospitalization, infection was controlled, and then surgical debridement, biopsy and partial skin graft were carried out. There was a graft integration of approximately 50% (Figure 3). Patient evolved with improvement of the lesion; pain, however, was still intense. He presented scaring areas surrounding grafted areas and a lot of granulation tissue, despite the progression of around 4 cm from the upper border of the lesion, which once more underwent biopsy. The Pain Clinic associated regular morphine with weekly peridural blocks.

After 70 days of hospitalization, with his AP

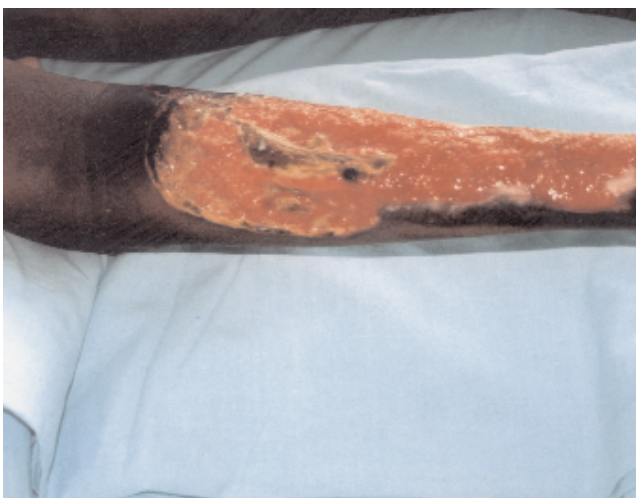

FIGURE 1: Extensive ulcer with yellowish bed, with necrotic areas and tendon exposure, affecting the entire right calf; mid third with granulation tissue

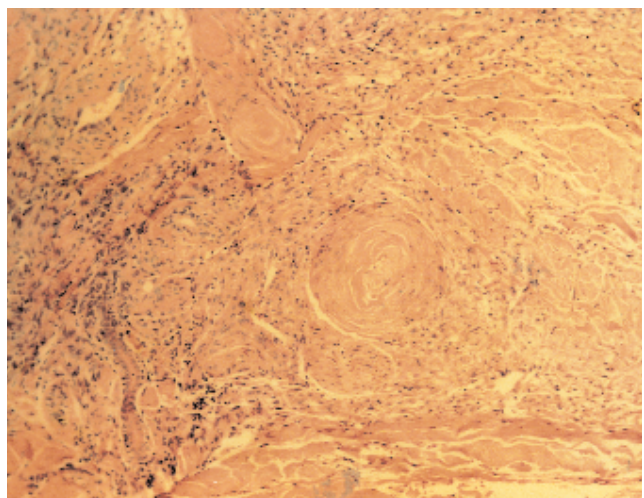


FIGURE 2: Detail of the intense thickening of the intimal layer of the arteriole in the deep dermis (HE, 10x)

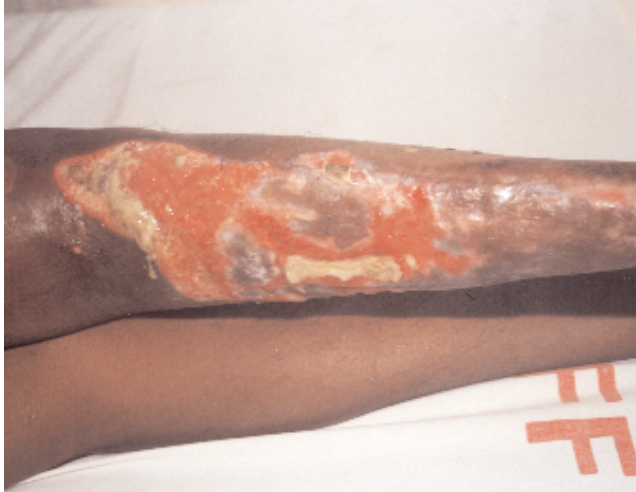

FIGURE 3: Still extensive ulcerated lesion, with clear bed and 50% integration of skin graft

controlled and less intense pain, he presented four round-shaped ulcerated lesions with yellow bed, in the anterior tibial region of the LLL, which were extremely painful, ranging from 0.5 to 2cm of diameter (Figure 4). Pentoxiphilin was then begun twice daily at the dose of 400 mg, and left lumbar sympathectomy was carried out, improving LLL pain and stabilizing lesion growth.

In the 84th day of hospitalization he was discharged after important improvement of the RLL ulcerated lesion, healing of the two lower thirds of the lesion, maintaining the upper third ulcerated, with no infection, and with granulation tissue – and discrete improvement in the LLL. He was then using morphin 30 mg 4/4h, propranolol 320mg/d, captopril 150mg/d, nifedipin 40mg/d, acetylsalicylic acid

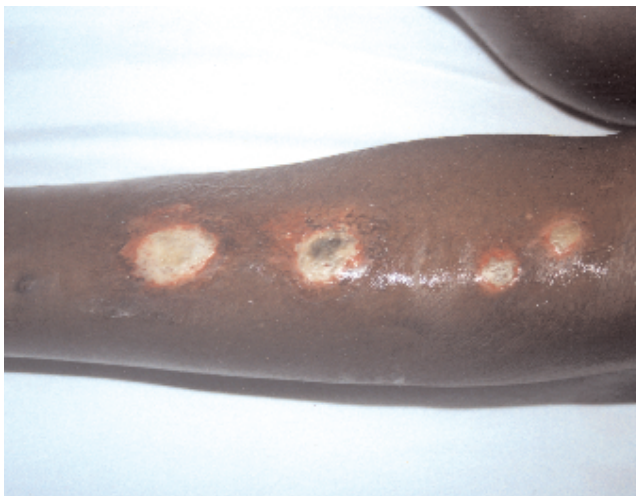

FIGURE 4: Round-shaped ulcerated lesions with fibrinous bed and erythematous halo in the tibial region of the left lower limb

200mg/day, isosorbide dinitrate 30mg/d and pentoxiphilin 800mg/d, besides bandaging of the lesions twice daily with silver sulfadiazine at 1%. After two weeks, he returned walking, with controlled pain and lesions healing. He evolved with total healing of the lesions after five months.

## DISCUSSION

The first diagnostic hypotheses for the case besides ulcer of vascular origin where lower limb ulcer associated to either metabolic or hematological disease, such as *diabetes mellitus* and sickle cell anemia, both excluded with laboratorial tests. Given the extension and persistent growth of the lesion, other hypotheses were gangrenous pyoderma and squamous cell carcinoma, excluded by hystopathological examination. Purulent secretion associated to foul smell was interpreted as a sign of secondary bacterial infection, probably caused by gram-negative and/or anaerobial germs, being thus treated by the combination of amoxicilin and clavulanate, which covers both *Staphylococcus* sp. and *Streptococcus* sp. And anaerobial germs and some gram-negative, therefore being well indicated in infectious of the extremities that are associated to vascular alterations, which is why no bacteriological examinations were carried out.<sup>2</sup>

One hundred and forty-seven cases of the world literature were reviewed (Table 1),<sup>3-14</sup> 112 (76,2%) of the happening in women, 25 (17%) in men, and 10 (6,8%) of non-specified cases. Average age was 63 years, with extremes of 43 and 86. Lesion sized ranged from less than 1 cm to 13x27cm, but most cases were within 3-4cm. Description of the ulcer bed varied between necrotic, granulous and fibrine exsudate. Most frequent location was posterior-lateral lower limb; and the least frequent, anterolateral, which differs from Martorell's classical description. Proposed treatment varied, including local cares, uniquely or associated with control of AP, surgical debridement, grafting sympathectomy, sympathectomy associated to grafting, hyperbaric chamber, continuous epidural electrical stimulation and even amputation in two cases with associated vascular disease. Almost every case evolved with lesion healing, with timeframe ranging from a few days after sympathectomy to several months.

Diagnostic criteria proposed by Martorell in 1945 are:

1. arm arterial hypertension;
2. leg arterial hypertension;
3. absence of occlusion of great arteries in the lower limbs and palpable pulses in all lower limb arteries;
4. absence of venous circulation disorder;

CHART 1: Martorell's hypertensive ulcer: world casuistry

Author/year	N° cases	Gender		Average age	Location in lower limb	Treatment	Healing
		M	F				
Hines EA et al, 1946 <sup>5</sup>	11	0	11	57	PM (5); P (2); L (4)	L (3); (8)	–
Orbach EJ, 1955 <sup>6</sup>	4	0	4	57	Mid third/inferior	LS (3); E (1)	Y (3 cases 60 days)
Palou J, 1955 <sup>7</sup>	2	0	2	57	AL ; L	LS	Y (45 and 55 days)
Monserrat J, 1958 <sup>8</sup>	1	0	1	59	PM	AH and LS	Y (10 days)
Alonso T, 1961 <sup>9</sup>	1	0	1	53	PM	LS	Y (90 days)
Mozes M et al, 1962 <sup>10</sup>	4	2	2	64	PL (2); PM (1); AL (1)	LS (3); LC (1)	Y (3 cases in 90 days)
Schnier BR et al, 1966 <sup>11</sup>	40	13	27	60-70	PL	VD + D + rest (19); LS (7); G (8); G + LS (3); A (2); 1 death (uremia)	Y (29 cases in 120 days)
Sampère CT et al, 1986 <sup>12</sup>	1	1	0	65	–	PEES	Y (45 days)
Levene 1991	10	?	?	66	SM (8); AL (1); PL (1)	LC (1); D (2); G (2); AI (2); N (2); HC (1)	Y (60 to 180 days)
Henderson 1995	16 – (22 ulcers)	3	13	70	Mid third/inferior L	Conservative ttm (6); LS (2); G (8); G+LS (6)	Y (20 ulcers in 120 to 270 days)
Hermida FL et al, 1996 <sup>14</sup>	56	6	50	73	–	ZO, neomicin benzocaine	Y (73.8% in 180 days)
Graves JW et al, 2001 <sup>3</sup>	1	0	1	67	PL	LC; AH	Y (50 days)

–: not referred

A: amputation

AL: anterolateral

AH: anti-hypertensive

LC: local care

HC: hyperbaric chamber

D: debridement

G: grafting

PEES: permanent epidural electrical stimulation

AI: anesthetic infiltration

L: lateral

N: neurectomy of the sensitive branch of the musculocutaneous nerve

ZO: zinc oxide

P: posterior

PL: postero-lateral

PM: perimaleolar

Y: yes

SM: supramaleolar

LS: lumbar sympathectomy

VD: vasodilator

ttm: treatment

5. superficial ulcer in the anterolateral surface of the lower limb, in the border of mid and lower thirds;

6. symmetry of the lesions (ulcers in both sides or ulcers in one side and hypertrophic scars in the opposite side);

7. higher prevalence in women;

8. absence of arterial calcification.<sup>8,9</sup>

The amount of criteria necessary for diagnostic confirmation was not defined. Various authors have questioned these criteria, especially as to absence of related diseases and most frequent location, as the posterior lateral region has been verified to be the more prevalent.<sup>6,11,13</sup> There are no reports on the necessity of more elaborate exams, such as Doppler

or lower limb arteriography, for the diagnosis is basically clinical.

Lesion seems to occur as a result of a decrease in cutaneous perfusion pressure, owing to a localized increase of vascular resistance. Incapacity of vasodilation, in response to arteriolar lumen narrowing caused by arterial hypertension can lead to decreased tissue perfusion to the point of resulting in the formation of an ischemic ulcer.<sup>3,13</sup> An arteriolosclerosis of dermal arteries occurs like it does in other organs, such as brain and kidneys. Most common histopathological alterations are hyperplasia and hyaline deposits in the middle layer, and thickening of the elastic lamina, besides proliferation of the intimal layer, with consequent vessel lumen reduction.<sup>3,4,10</sup>

Final diagnosis was Martorell's hypertensive ulcer, once it fulfilled criteria number 1, 3, 4, 5 and 6 of Martorell. Besides that, great intensity of pain, responding only to morphin and peridural blocks, hystopathological examination and the fact that response to treatment came only after adequate arterial pressure control also point towards this diagnosis.

The best treatment for ischemic hypertensive ulcers is still controversial. Some authors advocate lumbar sympathectomy,<sup>8,9</sup> whereas others defend a conservative treatment, with AP control and local cares with the lesion, only using sympathectomy or grafting in resistant cases.<sup>3,7,13,14</sup> In the present case, both AP control and local care, and debridement and grafting for the bigger lesion were used, as was lumbar

sympathectomy for the new lesions that appeared in the other limb. The use of pentoxiphilin can be justified by its fibrinolytic properties, its capacity to reduce leukocyte adhesion to vascular endothelium and its antithrombotic effects, which would all improve local perfusion. As to the best hypertension treatment scheme, a study has shown the efficacy of nifedipin for the treatment of hypertensive ulcer, which is compatible to the physiopathologic hypothesis of local arteriosclerosis associated to vasoconstriction.<sup>15</sup> This finding suggests that drugs that reduce peripheral vasoconstriction, such as calcium channel blockers and inhibitors of angiotensin converting enzyme, are the best anti-hypertension drugs for these patients, while beta-blockers should be avoided.<sup>3,13,15</sup> □

## REFERENCES

1. Fernandes NC. Úlceras de membros inferiores de causa vascular. *Atualidades Dermatológicas*. 1996;2:8-10.
2. Choucair MM, Fivenson DP. Leg ulcer diagnosis and management. *Dermatol Clin*. 2001;19:659-78.
3. Graves JW, Morris JC, Sheps SG. Martorell's hypertensive leg ulcer: case report and concise review of the literature. *J Hum Hypertens*. 2001;15:279-83.
4. Deluchi Levene NA. Úlcera hipertensiva de Martorell. *Rev Argent Cirug*. 1991;61:209-10.
5. Hines EA, Farber EM. Ulcer of the leg due to arteriosclerosis and ischaemia occurring in the presence of hypertensive disease (hypertensive ischaemic ulcers): a preliminary report. *Proc Staff Meet Mayo Clin*. 1946;21:337-46.
6. Orbach EJ. Hypertensive ischaemic leg ulcer. *Angiology*. 1955;3:153-61.
7. Palou J. Lumbar sympathectomy in the treatment of hypertensive ischaemic ulcers of the leg (Martorell's syndrome). *Circulation*. 1955;12:239-41.
8. Monserrat J. Diastolic arterial hypertension and ulcer of the leg - Martorell's syndrome. *Angiology*. 1958;9:226-7.
9. Alonso T. diastolic hypertension and cutaneous gangrene of the legs (Martorell's syndrome). *J Cardiovasc Surg (Torino)*. 1961;2:252-5.
10. Mozes M, Salomy M, Jahr J, Adar R. Hypertensive ischaemic ulcer of the leg. *J Cardiovasc Surg (Torino)*. 1962;3:201-6.
11. Schnier BR, Sheps SG, Juergens JL. Hypertensive ischaemic ulcer: a review of 40 cases. *Am J Cardiol*. 1966;17:560-5.
12. Sampère CT, Guasch JÁ, Paladino CM, Casalongue MS, Amato CP. Úlcera isquêmica hipertensiva un nuevo enfoque terapéutico. *Rev Argent Cirug*. 1986;51:207-12.
13. Henderson CA, Highet AS, Lane AS, Hall R. Arterial hypertension causing leg ulcers. *Clin Exp Dermatol*. 1995;20:107-14.
14. Hermida FL, Aramayo AR, Bertranou EG. Tratamiento ambulatorio de la úlcera arteriolar hipertensiva de Martorell. *Rev Argent Cir*. 1996;71:65-7.
15. Nikolova K. Treatment of hypertensive venous leg ulcers with nifedipine. *Methods Find Exp Clin Pharmacol*. 1995;17:545-9.

---

### MAILING ADDRESS:

*Bruna Malburg Freire*

*Rua Eng. Prudente Meireles de Moraes 706 -*

*apto. 1202 - Vila Adyana*

*12243-705 - São José dos Campos - SP - Brazil*

*Tels.: +55 12 3913-3041 / +55 21 9116-3821*

*Fax: +55 12 3913-3041*

*E-mail: bmalburg@superig.com.br*