




References

- Kirkpatrick CH. Chronic mucocutaneous candidiasis. *J Am Acad Dermatol.* 1994;3:PS14–S7.
- Van de Veerdonk FL, Plantinga TS, Hoischen A, Smeekens SP, Joosten LAB, Gilissen C, et al. STAT1 mutations in autosomal dominant chronic mucocutaneous candidiasis. *N Engl J Med.* 2011;365:54–61.
- Eyerich K, Foerster S, Rombold S, Seidl H, Behrendt H, Hofmann H, et al. Patients with chronic mucocutaneous candidiasis exhibit reduced production of Th17-associated cytokines IL-17 and IL-22. *J Invest Dermatol.* 2008;128:2640–5.
- Van der Graaf CAA, Netea MG, Drenth IPH, te Morsche RH, van der Meer JWM, Kullberg BJ. Candida-specific interferon-gamma deficiency and toll-like receptor polymorphisms in patients with chronic mucocutaneous candidiasis. *Neth J Med.* 2003;61:365–9.
- Toubiana J, Okada S, Hiller J, Oleastro M, Gomez ML, Becerra JCA, et al. Heterozygous STAT1 gain-of-function mutations underlie an unexpectedly broad clinical phenotype. *Blood.* 2016;127:3154–64.
- Kirkpatrick CH. Chronic mucocutaneous candidiasis. *Pediatr Infect Dis J.* 2001;20:197–206.
- Egri N, Esteve-Solé A, Deyà-Martínez A, de Landazuri IO, Vlagea A, García AP, et al. Primary immunodeficiency and chronic mucocutaneous candidiasis: pathophysiological, diagnostic, and therapeutic approaches. *Allergol Immunopathol (Madr).* 2021;49:118–27.
- Van de Veerdonk FL, Netea MG. Treatment options for chronic mucocutaneous candidiasis. *J Infect.* 2016;5:56–60.
- Higgins E, Shehri TA, McAleer MA, Conlon N, Feighery C, Lilic D, et al. Use of ruxolitinib to successfully treat chronic mucocutaneous candidiasis caused by gain-of-function signal transducer and activator of transcription 1 (STAT1) mutation. *J Allergy Clin Immunol.* 2015;135:551–3.
- Meesilpavikkai K, Dik WA, Schrijver B, Nagtzaam NMA, Sluijs SJP, van Hagen PM, et al. Baricitinib treatment in a patient with a gain-of-function mutation in signal transducer and activator of transcription-1 (STAT1). *J Allergy Clin Immunol.* 2018;142:328–30.

Nathalia Chebli de Abreu ^{a,b,*},
 Samuel Duarte Timponi Franca ^{a,b},
 Hyllo Baeta Marcelo Júnior ^c, Amanda Neto Ladeira ^a

^a Department of Dermatology, Hospital Infantil João Paulo II, Fundação Hospitalar do Estado de Minas Gerais, Belo Horizonte, MG, Brazil

^b Department of Dermatology, Hospital Eduardo de Menezes, Fundação Hospitalar do Estado de Minas Gerais, Belo Horizonte, MG, Brazil

^c Department of Mycology, Fundação Ezequiel Dias, Belo Horizonte, MG, Brazil

* Corresponding author.

E-mail: nathaliachebli@gmail.com (N.C. Abreu).

Received 5 July 2022; accepted 10 August 2022

Available online 16 May 2023

<https://doi.org/10.1016/j.abd.2022.08.013>

0365-0596/ © 2023 Sociedade Brasileira de Dermatologia.

Published by Elsevier España, S.L.U. This is an open access article under the CC BY license (<http://creativecommons.org/licenses/by/4.0/>).

Case for diagnosis. Unusual involvement of asymptomatic facial papular eruption: eruptive vellus hair cysts[☆]



Dear Editor,

A 44-year-old female patient presented with a medical history of asymptomatic skin lesions covering her face and ears. The lesions had started in puberty with an increasing number since then. She had been treated for acne with topical retinoids, antibiotics, and oral isotretinoin with no improvement. Physical examination showed numerous distinct (1–3 mm) smooth skin-colored papules concentrated on the cheeks and the ears (Fig. 1 A–C). There was no family history of similar lesions. A punch biopsy of a papule on the left cheek was performed. The specimen was submitted for histopathological examination (Fig. 2).

What's your diagnosis?

a. Acneiform eruption

- b. Steatocystoma multiplex
- c. Epidermal cysts
- d. Eruptive vellus hair cysts

Discussion

After correlating the clinical and histological findings, the diagnosis of eruptive vellus hair cysts (EVHC) with facial involvement was established.

EVHC are a rare benign follicular developmental abnormality of the vellus hair follicles that Esterly and Cols first described in 1977.¹ They are most commonly seen in children, adolescents, or young adults, affecting different genders and ethnicities equally. They could be sporadic or inherited (autosomal dominant). Furthermore, mutations in the gene that encodes keratin 17 have been described.^{1,2}

Clinically, EVHC typically are seen as asymptomatic smooth skin-colored to slightly hyperpigmented follicular papules of 1–4 mm in diameter with a centrally umbilicated surface usually involving the chest, abdomen, and limbs.^{3,4}

The facial involvement is uncommon. EVHC has been described as macular, papular, skin-colored, pink, slate hyperpigmented, nevus of Ota-like, and even unilateral. Sites of involvement include the forehead, cheeks, and peri-orbital areas.² The clinical presentation is often not enough

[☆] Study conducted at the Italian Hospital of Buenos Aires, Caba, Argentina.

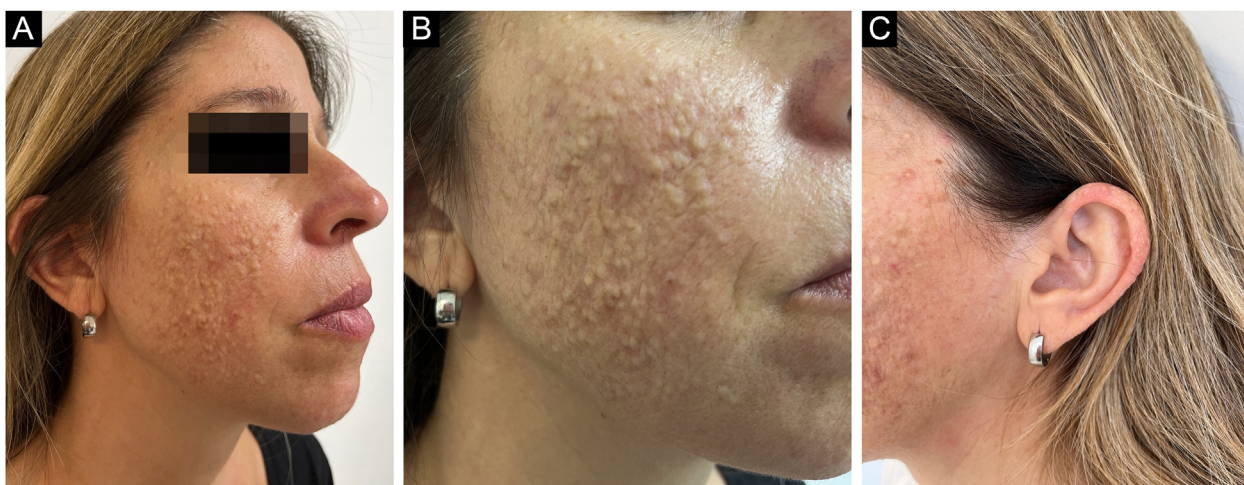


Figure 1 (A–C) Numerous distinct (1–3 mm) smooth skin-colored papules concentrated on the cheeks and the ears

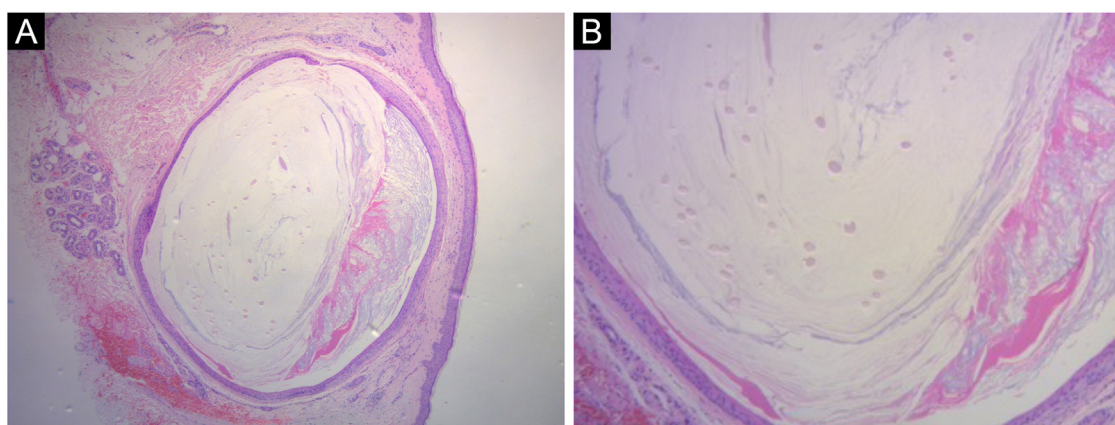


Figure 2 Microscopic Findings. Biopsy specimen from the cheek showing a mid-dermal cyst with abundant lamellated keratin and several vellus hair shafts are present inside the cyst, (A) Hematoxylin & eosin, $\times 10$. (B) Hematoxylin & eosin, $\times 40$

for a definitive diagnosis, which requires a histopathological examination.^{2–4}

Histologically, they are well-circumscribed cystic lesions in the mid-dermis and/or superficial dermis. The lining epithelium of the cyst wall resembles the infundibular or isthmic portion of the hair follicle and contains two to three layers of stratified squamous epithelium with focal areas of the granular layer. The cyst cavity contains a variable amount of laminated keratin and numerous transversally and obliquely cut vellus hairs. The cyst wall may be in continuity with an atrophied hair follicle or arrector pili muscle. Usually, no sebaceous glands are present within the cyst wall.^{3,4}

The most relevant differential diagnosis for this atypical presentation of EVHC is steatocystoma multiplex, which shows a very marked clinical overlap and can be distinguished only by histopathological examination.^{4,5} Other differential diagnoses are acneiform eruptions, milia, and folliculitis.

Although the spontaneous resolution of eruptive vellus hair cysts has been reported, treatment of this condition is often challenging. Therapeutic options include destructive methods such as dermabrasion, excision, and ablative lasers. Topical lactic acid, topical and oral retinoids, and

urea creams have also been tried with varying degrees of success.^{2,5}

Financial support

None declared.

Authors' contributions

Denys Elizabeth Peñaloza Daguer: Preparation and writing of the manuscript; intellectual participation in propaedeutic and/or therapeutic management of studied case and Study conception and planning.

Alicia Kowalczuk: Intellectual participation in propaedeutic and/or therapeutic management of studied cases.

Mariana Paula Caviedes: Intellectual participation in propaedeutic and/or therapeutic management of studied cases.

Luis Daniel Mazzuocolo: Critical literature review and approval of the final version of the manuscript.

Conflicts of interest

None declared.

References

1. Anand P, Sarin N, Misri R, Khurana VK. Eruptive vellus hair cyst: an uncommon and underdiagnosed entity. *Int J Trichology*. 2018;10:31.
2. Bhushan P, Singh A. Facial variant of eruptive vellus hair cyst. *Indian J Dermatol Venereol Leprol*. 2014;80:96.
3. Panchaprateep R, Tanus A, Tosti A. Clinical, dermoscopic, and histopathologic features of body hair disorders. *J Am Acad Dermatol*. 2015;72:890–900.
4. Rao R, Balachandran C. Asymptomatic papular lesions on the trunk. *Indian J Dermatol Venereol Leprol*. 2009;75:217–9.
5. Patokar AS, Holani AR, Khandait GH, Khatu SS. Eruptive vellus hair cysts: an underdiagnosed entity. *Int J Trichology*. 2022;14:31–3.

Denys Elizabeth Peñaloza Daguer *, Alicia Kowalczyk , Mariana Paula Caviedes , Luis Daniel Mazzuocolo 

Department of Dermatology, Italian Hospital of Buenos Aires, CABA, Argentina

* Corresponding author.

E-mail: denys.penaloza@hospitalitaliano.org.ar (D.E. Peñaloza Daguer).

Received 21 June 2022; accepted 7 August 2022
Available online 8 May 2023

<https://doi.org/10.1016/j.abd.2022.08.011>
0365-0596/ © 2023 Published by Elsevier España, S.L.U. on behalf of Sociedade Brasileira de Dermatologia. This is an open access article under the CC BY license (<http://creativecommons.org/licenses/by/4.0/>).

Dermatologists might be the first to suspect hereditary leiomyomatosis and renal cell carcinoma syndrome[☆]



Dear Editor,

Multiple cutaneous and uterine leiomyomatosis (OMIM 150800) is a rare, dominant autosomal hereditary disease in which patients develop multiple cutaneous and uterine leiomyomas. Around 14%–30% of patients also develop unilateral, solitary, and aggressive renal cell carcinomas (usually type-2 papillary). Consequently, some authors refer to this disease as Hereditary Leiomyomatosis and Renal Cell Carcinoma syndrome (HLRCC).¹ It is caused by a germline heterozygous mutation of the gene coding for fumarase (1q42-q44), also known as Fumarate Hydratase (FH).¹ Patients commonly die within 5 years of diagnosis,² so early detection is vital. Since cutaneous leiomyomas are one of the most constant manifestations of this disease, dermatologists might be the first to suspect it; when they do, they should facilitate genetic analysis.

The authors recently examined a 35-year-old woman (with a history of eating disorder (anorexia nervosa) since she was 13, suicide attempts, convulsive crises, irritable bowel syndrome, pollen allergy, and bronchial asthma) who presented with over 20 subcutaneous nodules around her body, some of which were painful, which she had had from adolescence with gradual onset.

Exploration revealed the presence of small, elastic nodules and papules with poorly defined borders, covered by slightly hyperpigmented skin and fibroelastic in consistency (Fig. 1). Some were painful when palpated. Ultrasound examination of the nodules in her left arm and thigh revealed highly vascularised hypoechoic lesions (Fig. 2).

Excisional biopsy revealed lesions with a poorly defined border, composed of fascicles of entwined fusiform cells irregularly distributed within the dermis, sparing the superficial dermis (Fig. 3). HLRCC was suspected, and genetic analysis confirmed the patient to carry a p.Arg233Cys mutation in the FH gene.

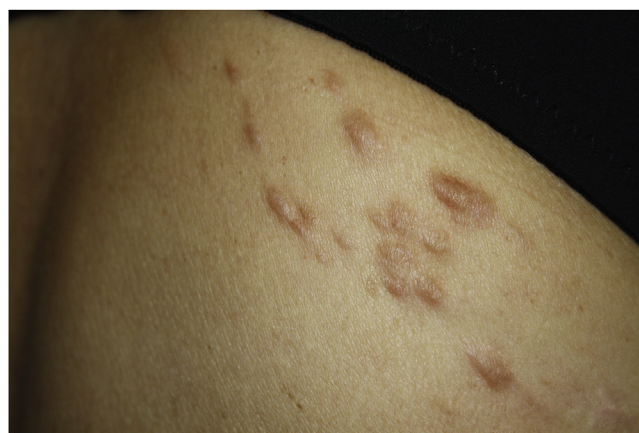

Figure 1 Small and elastic nodules/papules with poorly defined borders, covered by normal skin located on the shoulder

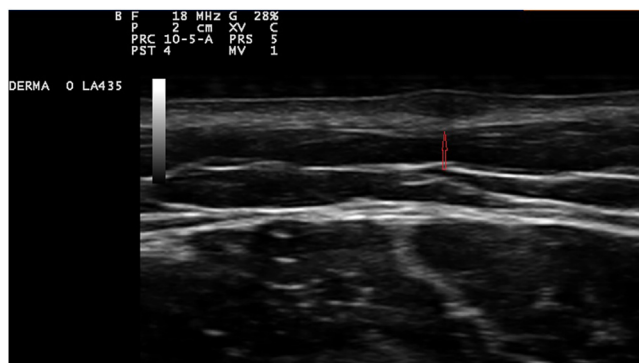


Figure 2 Ultrasonography shows a hypoechoic lesion located in deep dermis (arrow)

[☆] Study conducted at the Hospital Clinico Universitario San Carlos, Madrid, Spain.