

Using 80% trichloroacetic acid in the treatment of ingrown toenails*

Ácido Tricloroacético a 80% no tratamento da onicocriptose

Hugo Barreiros¹

Pedro Serrano¹

Diogo Matos¹

Alexandre João¹

João Goulão¹

Francisco Menezes Brandão¹

DOI: <http://dx.doi.org/10.1590/abd1806-4841.20132296>

Abstract: BACKGROUND: Ingrown nails are a very common problem. There are different stages of disease and diverse therapeutic options. Phenol and sodium hydroxide are commonly used agents for chemical matricectomy but both frequently entail excessive healing times. OBJECTIVE: This prospective study aimed mainly to evaluate the efficacy of partial nail avulsion and selective chemical cauterization of the matrix using 80% TCA in the treatment of the ingrowing nail. METHODS: One-hundred-and-thirty-three patients with 197 ingrown toenails were included in this study. Preoperatively, we tried to find predisposing factors to the disease. In the postoperative period, patients were evaluated for potential complications at days 3, 30, 180, 270 and 360. Pain was measured before surgery, as well as 24 hours and 72 hours after surgery. RESULTS: There were only 3 cases (out of 197) of ingrown nail recurrence. Preoperatively, we found the presence of drainage in 82% of patients, which, following the first visit after surgery, was reduced to 19%. Persistent granulation tissue was found in 3% of the patients (versus 75% prior to surgery). The most frequent predisposing factors for the ingrown nail were excessive trimming of the lateral nail plate (63%), plantar hyperhidrosis (58%) and heavy nail folds (39%). Pain was substantially reduced after surgery. CONCLUSION: It is assumed that chemical procedures for the ingrown toenail are associated with delayed healing times but our results demonstrated quick recovery. Using 80% TCA for selective matricectomy in the ingrown toenail is an effective, quick and easy method.

Keywords: Nail diseases; Nails; Nails, ingrown; Surgical procedures, minor

Resumo: FUNDAMENTO: A unha encravada é uma patologia muito frequente. A doença engloba diferentes estádios existindo diferentes soluções terapêuticas. O fenol e o hidróxido de sódio são largamente utilizados na matricetomia química porém ambos cursam com longos tempos de cura. OBJETIVO: O principal objectivo deste estudo prospectivo foi avaliar a eficácia da matricetomia com ácido tricloroacético a 80% no tratamento da unha encravada. MÉTODOS: Foram incluídos no estudo 133 doentes com 197 unhas encravadas. Factores predisponentes foram avaliados pré-operatoriamente. No período pós-operatório os doentes foram avaliados para potenciais complicações ao dia 3, 30, 180, 270 e 360. A dor foi avaliada antes da cirurgia, 24 horas e 72 horas depois da cirurgia. RESULTADOS: Ocorreram apenas 3 (em 197) casos de recorrência da unha encravada. Antes da cirurgia registou-se exsudação em 82% dos doentes sendo que na primeira visita após a cirurgia este número foi reduzido para 19%. Observou-se ainda tecido de granulação persistente em 3% dos doentes (versus 75% antes da cirurgia). Os factores predisponentes mais frequentemente encontrados para unha encravada foram o corte excessivo da porção lateral da placa ungueal (63%), hiperhidrose plantar (58%) e pregas ungueais espessadas (39%). A dor teve uma redução dramática após a cirurgia. CONCLUSÃO: É assumido que os procedimentos químicos para a unha encravada estão associados com longos tempos de cura mas os nossos resultados mostraram uma rápida recuperação. No tratamento da unha encravada a matricetomia parcial com ácido tricloroacético a 80% é um método rápido, eficaz e de fácil execução.

Palavras-chave: Doenças da unha; Procedimentos cirúrgicos menores; Unhas; Unhas encravadas

Received on 19.11.2012

Approved by the Advisory Board and accepted for publication on 14.01.2013

* Work performed at the Hospital Garcia de Orta - Almada, Portugal.

Financial Support: None.

Conflict of Interest: None.

¹ PhD - Doctor - Hospital Garcia de Orta - Almada, Portugal

©2013 by Anais Brasileiros de Dermatologia

INTRODUCTION

Ingrown toenails, onychocryptosis or unguis incarnatus are among the most common diseases of the nail unit. It mainly affects the great toes of men.^{1,2} Approximately 20 percent of patients consulting family physicians with a foot problem have an ingrown toenail.³ It leads to economic losses, affecting daily life, sporting and work activities.⁴ Nail plate piercing of the lateral nail fold results in a cascade of foreign body, inflammatory, infectious and reparative processes.⁵ The great toe is often the most affected site.⁶ Predisposing factors include: abnormal anatomic features such as disproportionate nail plate width compared with the nail bed, excessive nail plate thickness and curvature, rotation of the distal phalange and heavy nail folds.⁷ Moreover, the anatomic causes, behavioural mechanisms such as trauma and improper trimming of the lateral nail plate, are commonly known as the main affecting issues.

Several surgical and non-surgical methods have been described for treating ingrown nails. Partial nail plate avulsion with chemical selective destruction of the lateral horns is currently a widely accepted procedure. Phenol and sodium hydroxide are commonly used agents but both are frequently linked to excessive healing times.

Trichloroacetic acid (TCA) is an analogue of acetic acid. It is a well-known caustic agent extensively used in dermatology, mainly in cosmetic peelings. It causes coagulative necrosis of cells through wide protein denaturation and resultant structural cell death.⁸

Objectives

This study was mainly designed to evaluate the efficacy of partial nail avulsion and selective chemical cauterization of the matrix using 80% TCA in the treatment of the ingrowing nail. Preoperatively, we tried to find predisposing factors to the disease and also evaluated pain before and after surgery.

MATERIAL AND METHODS

A prospective study in patients with indication for surgical treatment of ingrowing nail was conducted. One-hundred-and-thirty-three patients with 197 ingrowing nail sides were treated with segmental chemical matrix cauterization by 80% TCA. Predisposing factors were evaluated at the first visit: excessive curvature of the nail plate, toe rotation, thin nails, heavy nail folds, hyperhidrosis, bad nail clipping and the regular use of constricting footwear. Suitable antibiotic therapy was used in cases of infection.

Surgical procedures included: proximal digital nerve block, hemostasis with tourniquet, granulation tissue curettage, lateral toenail plate and matrix lateral horn removal; and trichloroacetic acid (TCA) (80%)

application on exposed nail bed and matrix for 5 seconds (twice, 10 seconds in total) (Figures 1-4). The two-time 5 second rule was established after finding that this led to clinical necrosis (whitening / graying of tissue). The instruments used were generally the same as those used in any cutaneous surgery, with the addition of nail elevators. Dressings with topical antibiotics were used in all patients. Extremity elevation for at least 12 hours was recommended. Dressings were changed every second postoperative day. No analgesics were given. Oral antibiotics were only prescribed if there were clinical signs of infection.

After their operations, all patients were examined at the 72-hour mark to evaluate drainage or potential complications of the surgical technique (such as hemorrhage, infection, pain or necrosis). At that point, patients measured pre-operative and post-operative (24 and 72 hours) pain using a visual analogic scale (from 1 to 10). Patients were then examined on day 30 (1 month), day 180 (6 months), day 270 (9 months) and day 360 (1 year), after surgery. During each visit, the wounded area was checked and any complication or sign of recurrence was noted.

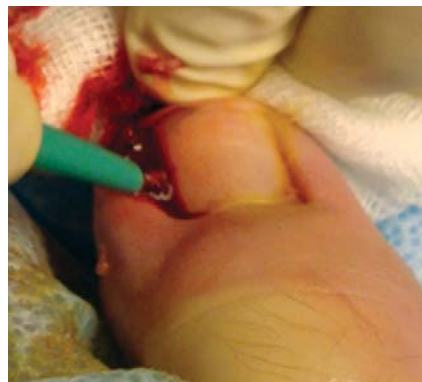

FIGURE 1: Granulation tissue curettage

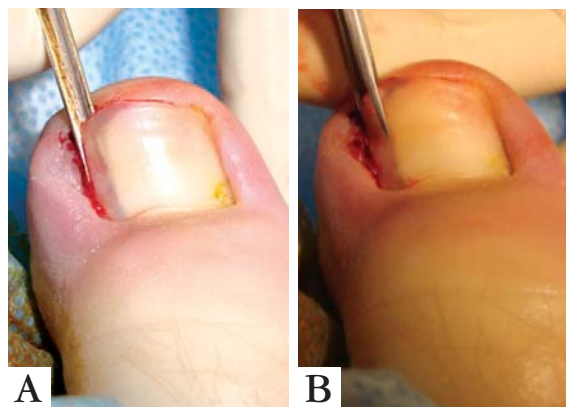


FIGURE 2: A. Separation of the nail plate from the nail bed using a nail elevator; B. Lateral nail plate clipping

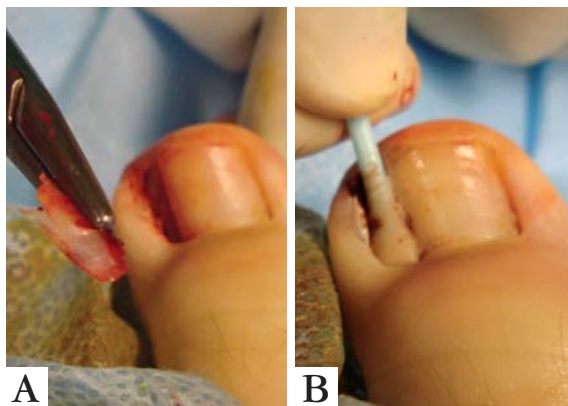


FIGURE 3: A. Separation of the nail plate from the nail bed using a nail elevator; B. Lateral nail plate clipping

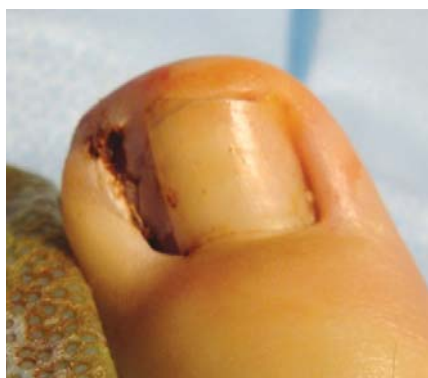

FIGURE 4: Final result after surgery

RESULTS

There were 133 patients (86 male, 47 female) with 197 ingrowing nail slides. The mean age of patients was 27 years (range, 11-80 years). 73% of the patients were aged below 27.

From the potential contributing factors for the disease that were assessed, we found that 63% had an excessive trimming of the lateral nail plate, 58% suffered from plantar hyperhidrosis and 39% showed heavy lateral nail folds. 25% regularly used constricting footwear, 24% had thin nails, 14% an excessive curvature of the nail plate and 11% a rotation of the toe (Table 1).

In 50 patients (38%), surgery was performed on both lateral sides of the nail. The external side of the right great toenail (23 patients) was the most affected. Next was the external side of the left great toenail (14 patients), the internal side of the left toenail (13 patients) and finally, the internal side of the right toenail (12 patients).

Preoperatively, we found the presence of drainage in 82% and granulation tissue in 75% of the patients. At the first visit after surgery (day 3), drainage decreased to 19% of the patients. Hemorrhage was found in 3% and the persistence of granulation tissue in 4% of the patients. At the second evaluation (day 30 after surgery) 4% had persistent minor erosion with no drainage. 5% showed mild drainage and another 5% exhibited persistent granuloma (Table 2). Oozing and granulation decreased greatly at the day-3 post-op. At day-30, patients were asked about the total healing time. Almost everyone (> 80%) reported that 10 days after surgery, there was complete healing of the surgical site and that they returned to normal activity within a maximum of 15 days.

At the 6-month follow-up, only two nail sides of one patient and one nail side of two other patients showed signs of recurrence (this was defined as occurrence of any clinical sign of regrowth of the treated nail side). These three patients were re-treated using the same technique. At the 9-month and 1-year follow-up, there were no additional recurrences. In eight patients, there was a regrowth of a not ingrown nail spicule (regarded merely as an esthetical problem) (Table 3). The overall success rate in TCA matricectomy was 94% (Figures 5-6).

TABLE 1: Predisposing factors for the ingrowing nail

Excessive trimming of the lateral nail plate	63%
Plantar hyperhidrosis	58%
Heavy lateral nail folds	39%
Use of constricting footwear	25%
Thin nails	24%
Excessive curvature of the nail plate	14%
Rotation of the toe	11%

TABLE 2: Pre-operative evaluation and post-operative complications

	Pre-operative	Day 3	Day 30
Drainage	82%	19%	5%
Granulation tissue	75%	4%	5%
Hemorrhage	3%		
Erythema	2%		
Erosion (no drainage)			4%

TABLE 3: Six-months follow-up

Success	94%
Spicule (not ingrown)	4%
Recurrence	2%

Pain was reduced from an average value of 6 before surgery to 2 in the following 24 hours and 1 after 72 hours (Figure 7). In the post-operative procedure, none of the patients experienced severe pain (defined as pain higher or equal to 6). Pain was significantly reduced after surgery in 83% of the patients.

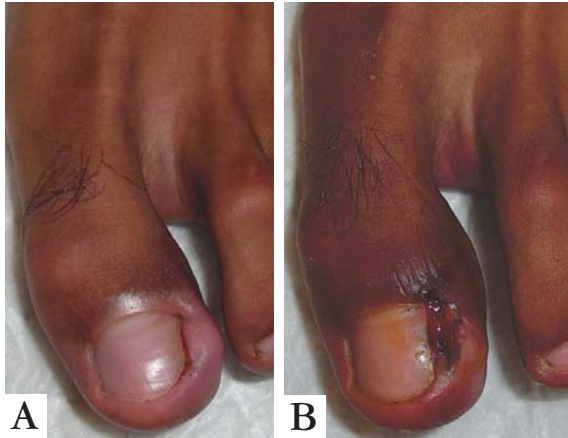


FIGURE 5: A. Pre-op; B. Day 3 after surgery

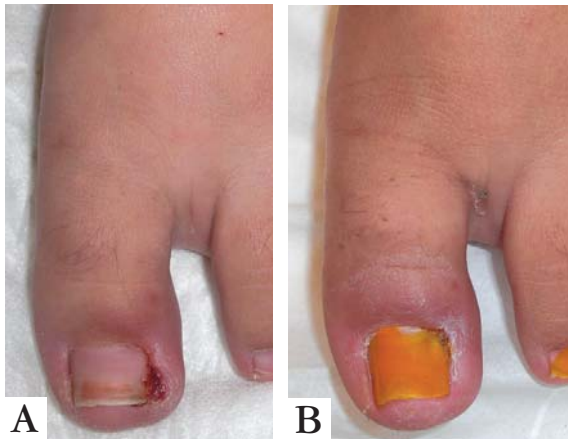


FIGURE 6: A. Pre-op; B. Day 30 after surgery

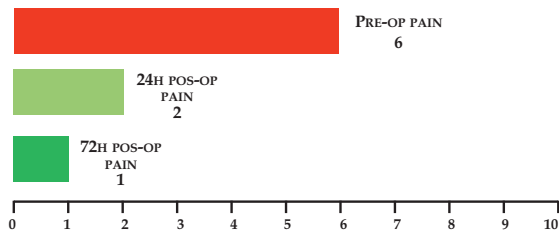


FIGURE 7: A. Pain evaluation scale: patients reported a remarkable reduction in pain after surgery

DISCUSSION

The ingrown nail is classically known as a condition that is frequent among adolescents and young adults, with a male predominance. Our results were in total agreement with the literature, as 73% of the patients were aged under 30. Predisposing risk factors to development of ingrown toenails include anatomic and behavioral mechanisms. In adolescence, feet perspire more often and the nail plate becomes softer, causing nail splitting and consequently piercing of the lateral nail fold. We found that 58% of the patients suffered from plantar hyperhidrosis. 39% of the patients had heavy nail folds and 63% showed signs of bad trimming of the nail plate.

Heifitz and Mogensen classified the severity of ingrown toenails into three stages: **A)** mild – nail fold swelling, erythema, edema and pain with pressure; **B)** moderate – increased swelling, seropurulent exudate, infection and ulceration of the nail fold; **C)** severe – chronic inflammation, granulation and marked nail-fold hypertrophy.^{9,10} Conservative and surgical treatment options exist and the latter should be offered in moderate and severe cases. There is no consensus as to the best surgical technique for treatment of ingrown toenails.¹¹

Initially, an ingrown toenail should be treated as a foreign-body reaction with simple disembedding of the spicule to avoid further trauma. It is often a recurring disease and numerous conservative and surgical treatments have been tried.² Partial nail plate avulsion and chemical cauterization of the matrix edge is an effective method for the treatment of ingrowing nails. The main objective is the destruction of the lateral horns of the matrix, preventing future growth of the nail plate into the nail fold. The method was first described by Boll in 1945.¹²⁻¹³ The two chemical agents used in this procedure are phenol and sodium hydroxide. Phenol was the first agent to be described with success rates of over 95%.¹² Comparable rates are mentioned by authors using sodium hydroxide, with shorter postoperative healing times.¹⁴ Animal studies have shown that many signs of acute poisoning result from phenol entry into the systemic circulation but there is still no evidence of systemic complications in patients who have undergone phenol nail matricectomies.

There are other options, in addition to exclusively surgical or chemical matricectomy. Partial matricectomy via carbon dioxide laser, electrocautery and radiofrequency have been successfully used but they are time-consuming and expensive techniques, often associated with long reepithelization times. There are often serious complications for the nail matrix due to overaggressive therapy.¹⁵ Arai *et al* described another technique, consisting of using a

gutter splint with formable acrylic resin.¹⁶ This has proven to be very effective but it is a complex and time-consuming technique.

It is also commonly said that chemical procedures for the ingrown toenail are associated with prolonged healing and a high rate of wound infection (versus surgical excision only).^{1,17} Most of our patients were completely healed when examined at the second appointment (30 days after surgery). There were only a few cases with mild complications (such as mild oozing, erosion or persistent granulation tissue). Moreover, there were only four cases of local infection. These results are similar to other chemical procedures as with phenol and sodium hydroxide.

Phenol and sodium hydroxide require much longer cauterizations, ranging between 1 to 3 minutes.¹⁸ With 80% TCA, using the technique previously described, we can obtain the same result in 10 seconds. A recent study compared post-operative morbidity rates of chemical matricectomy with those for phenol and sodium hydroxide. The two groups of patients, especially the sodium hydroxide group, complained of mild or moderate pain (there is no numerical classification) in the first two days following surgery.¹⁸ Pain reduction using 80% TCA is extremely effective, as shown in our results: signifi-

cant pain reduction in 83% of the patients immediately after surgery. Interestingly, Tassara *et al* recently showed that there is no difference between the nail matrix phenolization and phenolization associated with nail matrix curettage.¹⁹ We do not perform curettage of the nail matrix in our department.

Our results can be compared with those obtained by Kim *et al*.²⁰ In that particular study, the efficacy and safety of TCA matricectomy in ingrowing toenails are also evaluated. They used TCA in a higher concentration (100%) and longer application times (30 to 60 seconds). Forty ingrown toenail edges in 25 patients were included in the study. Results are similar, with a recurrence rate of 5% (follow-up period of 22.9 months) and good cosmetic results.

CONCLUSION

We conclude that 80% TCA can be safely used in selective matricectomy with high success rates and fast recovery times. The technique is cheap, simple and quick to perform. TCA also offers extra advantages, including coagulation and potent local anesthetic effects. A study comparing only surgery and surgery plus 80% TCA and other chemical cauterization methods could be performed to consolidate the results of this paper. □

REFERENCES

1. Rounding C, Bloomfield S. Surgical treatments for ingrowing toenails. *Cochrane Database Syst Rev*. 2005;18:CD001541.
2. van der Ham AC, Hackeng CA, Yo TI. The treatment of ingrowing toenails - A randomized comparison of wedge excision and phenol cauterisation. *J Bone Joint Surg Br*. 1990;72:507-9.
3. Reyzelman AM, Trombello KA, Vayser DJ, Armstrong DG, Harkless LB. Are antibiotics necessary in the treatment of locally infected ingrown toenails? *Arch Fam Med*. 2000;9:930-2.
4. Gerritsma-Bleeker CL, Klaase JM, Geelkerken RH, Hermans J, van Det RJ. Partial matrix excision or segmental phenolization for ingrowing toenails. *Arch Surg*. 2002;137:320-5.
5. DeLauro NM, DeLauro TM. Onychocryptosis. *Clin Podiatr Med Surg*. 2004;21:617-30, vii.
6. Baran R, Dawber R, Tosti A, Haneke E. *A Text Atlas of Nail Disorders: Techniques in Investigation and Diagnosis*. London: Martin Dunitz; 1996. p.169-98.
7. Langford DT, Burke C, Robertson K. Risk factor in onychocryptosis. *Br J Surg*. 1989;76:45-8.
8. Obagi ZE, Obagi S, Alaiti S, Stevens MB. TCA-based blue peel: a standardized procedure with depth control. *Dermatol Surg*. 1999;25:773-80.
9. Heifitz CJ. Ingrown toenail - a clinical study. *Am J Surg*. 1937;38:298-315.
10. Mogensen P. Ingrown toenail: follow-up on 64 patients treated by labiomatricectomy. *Acta Orthop Scand*. 1971;42:94-101.
11. Noël B. Surgical treatment of ingrown toenail without matricectomy. *Dermatol Surg*. 2008;34:79-83.
12. Byrne DS, Caldwell D. Phenol cauterization for ingrowing toenails: a review of five years of experience. *Br J Surg*. 1989;76:598-9.
13. Bool OF. Surgical correction of ingrowing toenails. *J Natl Assc Chiropr*. 1945;35:8-9.
14. Travers GR, Ammon RG. The sodium hydroxide chemical matricectomy procedure. *J Am Podiatry Assoc*. 1980;70:476-8.
15. Daniel CR 3rd, Iorizzo M, Tosti A, Piraccini BM. Ingrown toenails. *Cutis*. 2006;78:407-8.
16. Arai H, Arai T, Nakajima H, Haneke E. Formable acrylic treatment for ingrowing nail with gutter splint and sculptured nail. *Int J Dermatol*. 2004;43:759-65.
17. Sugden P, Levy M, Rao GS. Onychocryptosis-phenol burn fiasco. *Burns*. 2001;27:289-92.
18. Bostanci S, Kocycigit P, Gürgeç E. Comparison of phenol and sodium hydroxide chemical matricectomies of the treatment of ingrowing toenails. *Dermatol Surg*. 2007;33:680-5.
19. Tassara G, Machado MA, Gouthier MA. Treatment of ingrown nail: comparison of recurrence rates between the nail matrix phenolization classical technique and phenolization associated with nail matrix curettage - is the association necessary? *An Bras Dermatol*. 2011;86:1046-8.
20. Kim SH, Ko HC, Oh CK, Kwon KS, Kim MB. Trichloroacetic acid matricectomy in the treatment of ingrowing toenails. *Dermatol Surg*. 2009;35:973-9.

MAILING ADDRESS:

Hugo Barreiros
Avo. Torrado da Silva, Pragal
2801-951 Almada
Portugal.
E-mail: hbarreiros@gmail.com

How to cite this article: Barreiros H, Matos D, Goulão J, Serrano P, João A, Brandão FM. Using 80% Trichloroacetic acid in the treatment of the Ingrown Toenail. *An Bras Dermatol*. 2013;88(6):889-93.