

perforation, conjunctival herpetic infection and milium-associated features.

Financial support

This study was partially supported by FAPESP (Fundação de Amparo à Pesquisa do Estado de São Paulo), process number 2010/51729-2, and by FAEPA (Fundação de Apoio ao Ensino, Pesquisa e Assistência). SV received a PhD scholarship from CAPES (Coordenação de Aperfeiçoamento de Pessoal de Nível Superior).

Authors' contributions

Sebastian Vernal: Has contributed with collection and interpretation of data, writing the manuscript, effective participation, literature review, final approval of the final version of the manuscript.

Roberto Bueno-Filho: Has contributed with collection and interpretation of data, effective participation, participation of therapeutic conduct of the studied cases, final approval of the final version of the manuscript.

Takashi Hashimoto: Has contributed with collection and interpretation of data, effective participation, writing the manuscript, final approval of the final version of the manuscript.

Ana Maria Roselino: Has contributed with the study concept and design, collection, and interpretation of data, writing the manuscript, effective participation, literature review, participation of therapeutic conduct of the studied cases, final approval of the final version of the manuscript.

Conflicts of interest

None declared.





Acknowledgments

We thank the medical staff, especially Dr. Daiane Pess, of the autoimmune dermatoses' outpatient clinics at the University Hospital of Ribeirão Preto Medical School, University of São Paulo. We are grateful to Dr. Norito Ishii, Department of Dermatology, Kurume University School of Medicine, and Kurume University Institute of Cutaneous Cell Biology for various serological studies for autoantibodies and autoanti-

gens. We also thank Aline Turatti, PhD, University Hospital of Ribeirão Preto Medical School, University of São Paulo, for technical assistance for direct and indirect immunofluorescence.

References

- Ohki M, Kikuchi S. Nasal, oral, and pharyngolaryngeal manifestations of pemphigus vulgaris: Endoscopic ororhinolaryngologic examination. *Ear Nose Throat J.* 2017;96:120-7.
- Sardana K, Goel K. Nasal septal ulceration. *Clin Dermatol.* 2014;32:817-26.
- Machado ARDSR, La Serra L, Turatti A, Machado AM, Roselino AM. Herpes simplex virus 1 and cytomegalovirus are associated with pemphigus vulgaris but not with pemphigus foliaceus disease. *Exp Dermatol.* 2017;26:966-8.
- Vernal S, Oliveira EV, Bueno Filho R, Julio TA, Donadi EA, Turatti A, et al. Bullous pemphigoid and milia: prevalence and clinical laboratory findings in a Brazilian sample. *An Bras Dermatol.* 2022;97:435-42.
- Celere BS, Vernal S, La Serra L, Franco Brochado MJ, Moschini LE, Roselino AM, et al. Spatial Distribution of Pemphigus Occurrence over Five Decades in Southeastern Brazil. *Am J Trop Med Hyg.* 2017;97:1737-45.

Sebastian Vernal ^a, Roberto Bueno-Filho ^a, Takashi Hashimoto ^b, Ana Maria Roselino ^{a,*}

^a Dermatology Division, Department of Clinical Medicine, Faculdade de Medicina de Ribeirão Preto, Universidade de São Paulo, Ribeirão Preto, SP, Brazil

^b Department of Dermatology, Kurume University School of Medicine, and Kurume University Institute of Cutaneous Cell Biology, Fukuoka, Japan

* Corresponding author.

E-mail: amfrosel@fmrp.usp.br (A.M. Roselino).

Received 15 August 2021; accepted 20 September 2021; Available online 21 March 2023

<https://doi.org/10.1016/j.abd.2021.09.019>

0365-0596/ © 2023 Sociedade Brasileira de Dermatologia.

Published by Elsevier España, S.L.U. This is an open access article under the CC BY license (<http://creativecommons.org/licenses/by/4.0/>).

Perniosis-like erythema after SARS-CoV2 infection reactivated by vaccination with inactivated virus[☆]



Dear Editor,

Chilblain-like or perniosis-like erythema (PLE) has been frequently reported in association with SARS-CoV2 infection.¹

With the advancement of vaccination against this virus, there have also been reports of these lesions after the use of messenger RNA (mRNA) vaccines.² This report describes a case in which such lesions manifested after the infection and recurred with the patient receiving a vaccine against COVID-19 containing inactivated virus.

A 71-year-old female patient presented with acrocyanosis and erythematous infiltrated papules on the fingers in June 2020. One week before, she had presented with asymptomatic SARS-CoV2 infection, confirmed by RT-PCR (real time – polymerase chain reaction) testing. The condition was treated with dapsone 50 mg/day, with improvement after two months of use. The patient had a previous history of central nervous system vasculitis, diagnosed seven years before, based on neurological manifestations – with-

[☆] Study conducted at the Dermatology Outpatient Clinic, Hospital das Clínicas, Universidade Federal de Minas Gerais, Belo Horizonte, MG, Brazil.

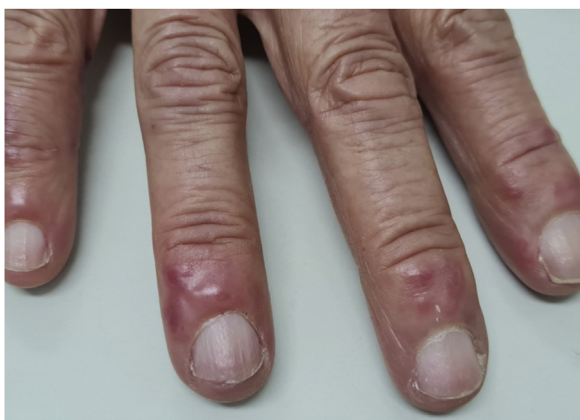

Figure 1 Mild acrocyanosis and erythematous-infiltrated papules on the distal region of the fingers.

out cutaneous symptoms, under remission for six years using azathioprine 2 mg/kg/day.

In May 2021, the lesions recurred one week after the first dose of the CoronaVac vaccine and persisted for two months, when dermatological care was introduced (Fig. 1). She had no systemic symptoms. Histopathology of a skin biopsy showed vacuolar degeneration of the basal layer, apoptotic keratinocytes, superficial and deep perivascular and periadnexal lymphohistiocytic inflammatory infiltrate, in addition to endothelial edema of small vessels (Fig. 2), findings that can be observed in drug reactions and viral infections. Laboratory tests for collagenosis were negative. SARS-CoV2 reinfection was ruled out by RT-PCR.

Hence, the diagnosis of PLE after SARS-CoV2 infection, which was reactivated by the vaccine with the inactivated virus was raised. Due to the absence of systemic symptoms

and criteria for vasculitis, the hypothesis of central nervous system vasculitis reactivation was refuted. Dapsone 100 mg/day and amlodipine 5 mg/day were prescribed, the latter to manage the acrocyanosis. After one month of drug use, there was improvement in the inflammatory reaction, and persistence of acrocyanosis (Fig. 3).

Classic erythema pernio usually occurs after exposure to cold, damp weather. It may be associated with acrocyanosis and autoimmune diseases, such as systemic lupus erythematosus. However, the frequency of this association is still controversial.³

SARS-CoV2-associated PLE usually occurs after the second week of infection and is associated with mild or asymptomatic disease in young, healthy patients.¹ There have also been reports of occurrence after immunization against COVID-19, mostly with mRNA vaccines.² To the best of the authors' knowledge, only two cases of PLE have been previously reported following vaccination with the inactivated SARS-CoV2 virus vaccine, i.e., the CoronaVac.⁴ However, the present case is the first in which post-infection PLE (confirmed by RT-PCR) recurred after the administration of the vaccine with the inactivated virus.

The authors believe that their observation supports the hypothesis that vaccines induce an infection-like immune reaction driven by type I interferon.⁵ The recurrence of PLE lesions after an inactivated virus vaccine also suggests these manifestations are related to the immune reaction to the virus, and not directly to the virus.

Given the importance of immunization advances to limit the current pandemic, the authors' objective with this report is to provide information for the future understanding of adverse reactions and post-vaccination advice.

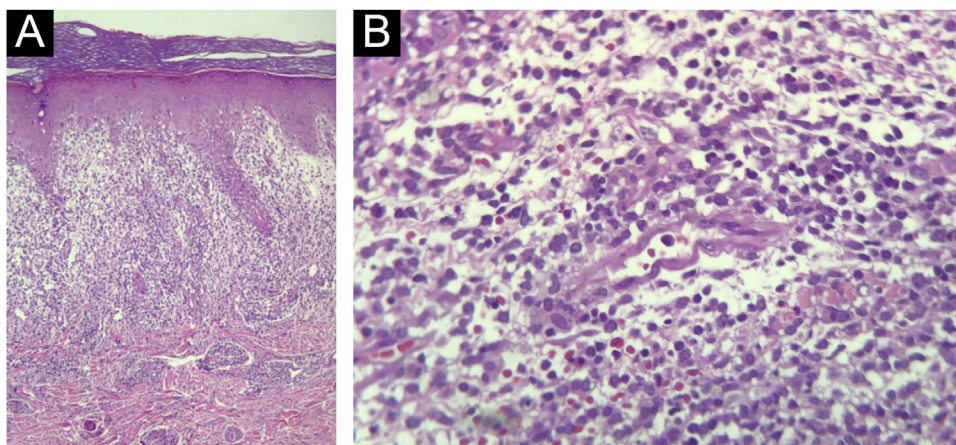


Figure 2 (A) Elongation of epidermal rete pegs and lymphocytic inflammatory infiltrate in the dermoepidermal interface and upper papillary/reticular dermis. Vacuolar degeneration of the basal layer and apoptotic keratinocytes can be observed, in addition to extravasated red blood cells (Hematoxylin & eosin, $\times 100$). (B) In the dermis, a small-caliber vessel with swollen endothelium, demonstrating vascular aggression. Surrounding it, lymphohistiocytic inflammatory infiltrate and extravasation of red blood cells can be observed (Hematoxylin & eosin, $\times 400$).

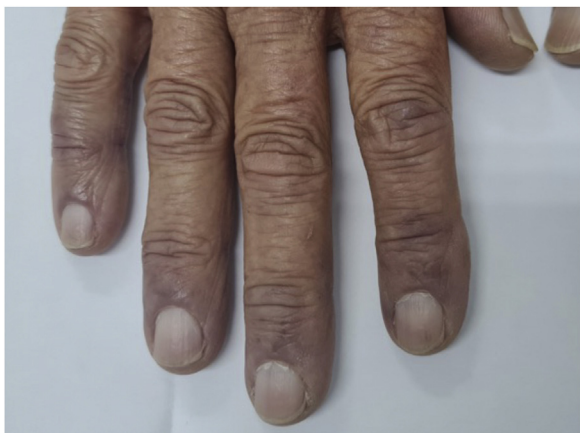

Figure 3 Persistence of acrocyanosis and full resolution of papules.

Financial support

None declared.

Authors' contributions

Lucas Campos Garcia: Approval of the final version of the manuscript; design and planning of the study; drafting and editing of the manuscript; intellectual participation in the propaedeutic and/or therapeutic conduct of the studied cases; critical review of the literature; critical review of the manuscript.

Vanessa Martins Barcelos: Drafting and editing of the manuscript; critical review of the literature; critical review of the manuscript.

Myrciara Macedo de Alcântara: Drafting and editing of the manuscript; critical review of the literature; critical review of the manuscript.

Priscila Jordana Costa Valadares: Drafting and editing of the manuscript; critical review of the literature; critical review of the manuscript.

Conflicts of interest

None declared.

References

1. Le Cleach L. Dermatology and COVID-19: much knowledge to date but still a lot to discover. *Ann Dermatol Venereol.* 2021;148:69–70.
2. McMahon DE, Amerson E, Rosenbach M. Cutaneous reactions reported after Moderna and Pfizer COVID-19 vaccination: a registry-based study of 414 cases. *J Am Acad Dermatol.* 2021;85:46–55.
3. Cappel JA, Wetter DA. Clinical characteristics, etiologic associations, laboratory findings, treatment, and proposal of diagnostic criteria of pernio (chilblains) in a series of 104 patients at Mayo Clinic, 2000 to 2011. *Mayo Clin Proc.* 2014;89:207–15.
4. Temiz SA, Abdelmaksoud A, Dursun R, Vestita M. Acral chilblain-like lesions following inactivated SARS-CoV-2 vaccination. *Int J Dermatol.* 2021;60:1152–3.
5. Aschoff R, Zimmermann N, Beissert S, Günther C. Type I interferon signature in chilblain-like lesions associated with the COVID-19 pandemic. *Dermatopathology (Basel).* 2020;7:57–63.

Lucas Campos Garcia ^a, Vanessa Martins Barcelos ^{a,*}, Myrciara Macedo de Alcântara ^b, Priscila Jordana Costa Valadares ^a

^a *Department of Dermatology, Hospital das Clínicas, Universidade Federal de Minas Gerais, Belo Horizonte, MG, Brazil*

^b *Dermatology Private Practice, Curitiba, PR, Brazil*

* Corresponding author.

E-mail: barcelosmvanessa@gmail.com (V.M. Barcelos).

Received 4 October 2021; accepted 12 January 2022;
Available online 30 March 2023

<https://doi.org/10.1016/j.abd.2022.01.015>

0365-0596/ © 2023 Sociedade Brasileira de Dermatologia.

Published by Elsevier España, S.L.U. This is an open access article under the CC BY license (<http://creativecommons.org/licenses/by/4.0/>).

Radiation recall dermatitis induced by ibuprofen[☆]



Dear Editor,

A 31-year-old female presented with a 1-week history of burning, painful and pruritic skin eruptions affecting the left chest and axillary region. She had previously undergone a modified radical mastectomy and lymph node dissection for ductal breast carcinoma 1 year ago. Then, the patient has prescribed 24 weeks of chemotherapy with doxorubicin, cyclophosphamide, and paclitaxel. Two months ago, she

was treated with 3-dimensional conformal radiation therapy (50 Gy: 25 fractions for five weeks). Mild erythema and scales with pruritus were observed at the end of radiotherapy and subsided with 0.05% desonide cream within several days. Six days before the eruptions appeared, she had taken ibuprofen orally for arthralgia. The inflammatory eruptions involved the areas previously treated with radiation and initially manifested well-demarcated rectangular erythema, edema, and tiny papules, followed by blisters and erosions (Fig. 1). The dermoscopy showed multiple brown circles along with the hair follicles as well as scales (Fig. 2). The histopathology revealed intraepidermal vesiculation, papillary dermal edema, and perivascular inflammatory infiltrate in the upper dermis (Fig. 3).

A diagnosis of radiation recall dermatitis (RRD) induced by ibuprofen was made. The patient was relieved after 1

[☆] Study conducted at the Chengdu Second People's Hospital, Chengdu, Sichuan, China.