

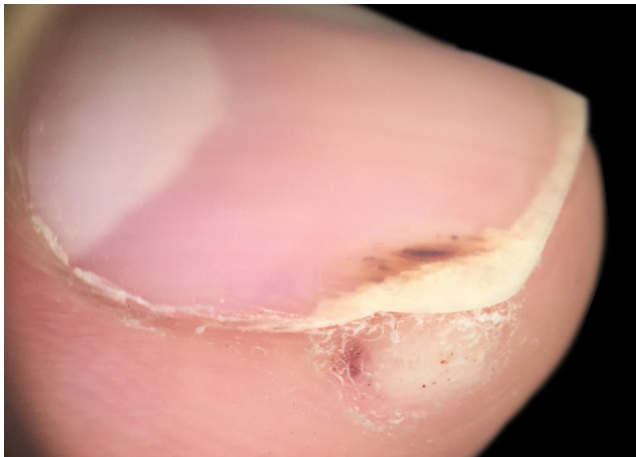FIGURE 1: Periungual wart. Verrucous lesion on the left thumb with subungual impairment and black dots

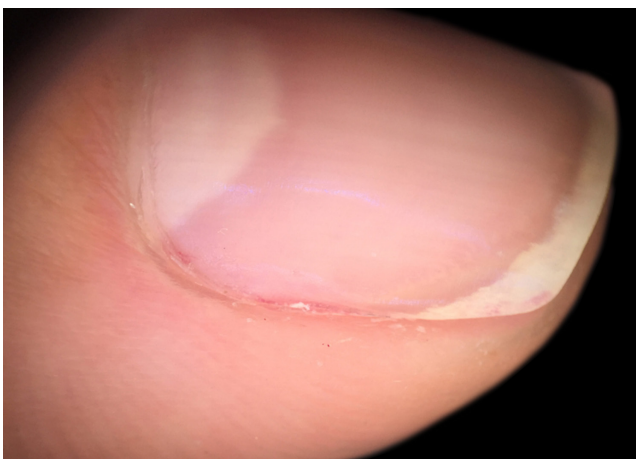

FIGURE 2: Clinical clearance of the lesions 15 days after the third procedure

REFERENCES

- Herschthal J, McLeod MP, Zaiac M. Management of unguinal warts. *Dermatol Ther*. 2012;25:545-50.
- Schopf RE. Ingenol mebutate gel is effective against anogenital warts - a case series in 17 patients. *J Eur Acad Dermatol Venereol*. 2016;30:1041-3.
- Braun SA, Gerber PA. Ingenol mebutate for the management of genital warts in sensitive anatomic locations. *J Am Acad Dermatol*. 2017;77:e9-e10.

AUTHORS' CONTRIBUTIONS

Gerson Dellatorre

ORCID 0000-0002-9657-0002

Approval of the final version of the manuscript, Design and planning of the study, Preparation and writing of the manuscript, Intellectual participation in propaedeutic and/or therapeutic conduct of studied cases, Critical review of the literature

Anarosa Barbosa Sprenger

ORCID 0000-0002-2282-0195

Approval of the final version of the manuscript, Collecting, analysis and interpretation of data, Effective participation in research orientation, Intellectual participation in propaedeutic and/or therapeutic conduct of studied cases, Critical review of the literature, Critical review of the manuscript

How to cite this article: Dellatorre G, Sprenger AB. Multipuncture technique with ingenol mebutate for the management of periungual wart. *An Bras Dermatol*. 2018;93(5):768-9.

Acral persistent papular mucinosis with pruritic skin lesions*

DOI: <http://dx.doi.org/10.1590/abd1806-4841.20187878>

Ana Iglesias-Plaza¹
Gemma Melé-Ninot¹
Noelia Pérez-Muñoz²
Montse Salleras-Redonnet¹

Dear Editor,

Cutaneous mucinoses are a group of diseases in which there is an abnormal deposit of mucin in the skin. It can be classified into primary and secondary forms. An uncommon subtype of primary mucinosis, acral persistent papular mucinosis (APPM) is currently considered as a clinicopathological variant of lichen myxedematosus.

A 31-year-old woman presented a 10-year history of persistent pruritic lesions on her arms. She had no relevant medical history. Physical examination revealed multiple, non-follicular and small (2-5 mm) skin-colored papules, some of them translucent, on the dorsum of both forearms (Figure 1). There were no other similar lesions on the rest of the body. The patient reported that topical corticosteroids were ineffective and sun exposure increased the number of lesions. Laboratory studies were within normal range, including blood cell count, liver, kidney and thyroid function. Antinuclear antibodies were negative. Skin punch biopsy of a papule was performed and histopathological examination showed no alteration in the epidermis. There was a focal area in the upper and mid reticular dermis due to a separation of collagen fibers. Deposit of mucin in the papillary dermis that stained positively with alcian blue was observed. There was no deposit of mucin in the reticular dermis. Fibroblast proliferation was not evident (Figure 2). APPM was then diagnosed.

APPM was first described by Rongioletti *et al.* in 1986¹ and the etiology is unknown, although both genetic and environmental factors are thought to play a role. Rongioletti and Rebora in 2001 proposed several diagnostic criteria for APPM and, to date, there have been more than 30 reported cases of this entity that met the criteria (Table 1).² Three cases showed family history.³ Clinically,

Received 18 November 2017.

Accepted 01 February 2018.

* Work conducted at the Hospital Universitari Sagrat Cor, Barcelona, Spain.

Financial support: None.

Conflict of interest: None.

¹ Department of Dermatology. Hospital Universitari Sagrat Cor, Barcelona, Spain.

² Department of Pathology, Hospital Universitari Sagrat Cor, Barcelona, Spain.

MAILING ADDRESS:

Ana Iglesias-Plaza

E-mail: anaiglesiasplaza@gmail.com

©2018 by Anais Brasileiros de Dermatologia

BY-NC

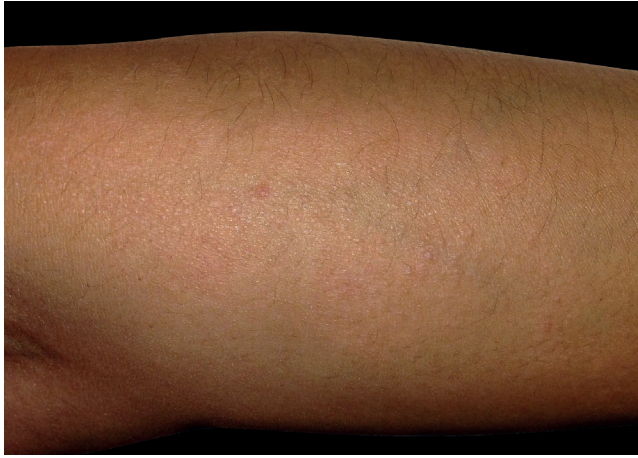

FIGURE 1: Small skin-colored papules, some of them translucent, symmetrically located on the dorsum of both forearms

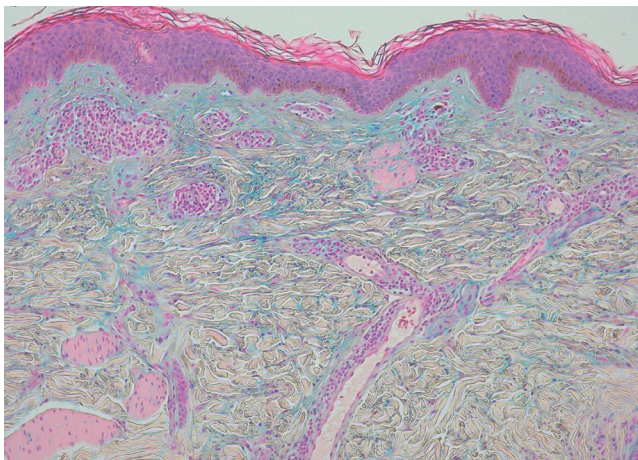


FIGURE 2: Epidermis shows no alterations. Note the focal area in the upper and mid reticular dermis due to a separation of collagen fibers. The area is positively stained with alcian blue, indicating deposit of mucin (Alcian blue, x40)

it is characterized by small flesh-colored, papules that most often are symmetrically localized on the back of the hands, wrists and extensor aspects of distal forearms. Differential diagnosis includes lichen nitidus, common warts and other forms of mucinosis. The lesions are usually asymptomatic, although in our case they were very pruritic. They tend to persist and may increase slowly. There is a female predominance. Neither systemic disease nor monoclonal gammopathy in peripheral blood are observed in this entity. The possible association with malignancies has not been clarified yet.⁴ The typical histopathology of APPM is a focal, well-circumscribed deposit of mucin in the papillary and mid-dermis. The deposit never extends to the deep reticular dermis. Fibroblastic proliferation is variable, although normally they are not increased in number. Due to the absence of symptoms, treatment is rarely necessary. APPM has been treated with topical corticosteroids, tacrolimus, pimecrolimus, liquid nitrogen, electrocoagulation and Erbium-YAG laser with some success.⁵ In our case, the patient reported pruritus, so we

TABLE 1: Diagnostic criteria for APPM

| Clinical Criteria | Histopathological Criteria |
|--|---|
| Multiple, small (2-5 mm) papules | Focal, well-circumscribed amount of mucin in the upper reticular dermis |
| Located exclusively on hands, wrists or forearms | No deposit of mucin in the deep reticular dermis |
| Persistent and may increase in number | Mucin spares a subepidermal zone |
| Predominates in women | Fibroblast proliferation is usually absent |
| No evidence of systemic disease | |
| No associated with gammopathy | |

Modified from: Pérez-Mies, *et al*, 2006.²

treated with topical 0.1% tacrolimus ointment for five weeks, but it was ineffective. We prescribed a fluid emulsion 12% sodium lactate for two months and the symptoms disappeared. We herein present a new case of this rare mucinosis. It is important to know that most cases are asymptomatic, but in our case, the patient presented pruritic lesions. □

REFERENCES

- Rongioletti F, Rebora A, Crovato F. Acral persistent papular mucinosis: a new entity. *Arch Dermatol*. 1986;122:1237-9.
- Pérez-Mies B, Hernández-Martín A, Barahona-Cordero E, Echevarría-Iturbe C. Mucinosis Papular Acral Persistente. *Actas Dermosifiliogr*. 2006;97:522-4.
- Jun JY, Oh SH, Shim JH, Kim JH, Park JH, Lee DY. Acral Persistent Papular Mucinosis with Partial Response to Tacrolimus Ointment. *Ann Dermatol*. 2016;28:517-9.
- Gómez Sánchez ME, Manueles Marcos F, Martínez Martínez ML, Vera Berón R, Azaña Défaz JM. Acral papular mucinosis. A new case of this rare entity. *An Bras Dermatol*. 2016;91:111-3.
- Graves MS, Lloyd AA, Ross EV. Treatment of acral persistent papular mucinosis using an Erbium-YAG laser. *Lasers Surg Med*. 2015;47:467-8.

AUTHORS' CONTRIBUTIONS

Ana Iglesias-Plaza ORCID 0000-0001-6628-274X
 Approval of the final version of the manuscript, Design and planning of the study, Preparation and writing of the manuscript, Collecting, analysis and interpretation of data, Effective participation in research orientation, Intellectual participation in propaedeutic and/or therapeutic conduct of studied cases, Critical review of the literature, Critical review of the manuscript

Gemma Melé-Ninot ORCID 0000-0003-0365-0634
 Approval of the final version of the manuscript, Design and planning of the study, Preparation and writing of the manuscript, Collecting, analysis and interpretation of data, Effective participation in research orientation, Intellectual participation in propaedeutic and/or therapeutic conduct of studied cases, Critical review of the literature, Critical review of the manuscript

Noelia Pérez-Muñoz ORCID 0000-0002-5144-1784
 Approval of the final version of the manuscript, Collecting, analysis and interpretation of data, Effective participation in research orientation, Critical review of the literature

Montse Salleras-Redonnet ORCID 0000-0003-1004-2493
 Approval of the final version of the manuscript, Critical review of the literature

How to cite this article: Iglesias-Plaza A, Melé-Ninot G, Pérez-Muñoz N, Salleras-Redonnet M. Acral persistent papular mucinosis with pruritic skin lesions. *An Bras Dermatol*. 2018;93(5):769-70.