

Lower facial remodeling with botulinum toxin type A for the treatment of masseter hypertrophy

Fernanda Homem de Mello de Souza Klein¹
Maurício Shigeru Sato²
Karin Adriane Helmer²

Fabiane Mulinari Brenner²
Fernanda Manfron Batista Rosas Robert²

DOI: <http://dx.doi.org/10.1590/abd1806-4841.20143200>

Abstract: BACKGROUND: Masseter hypertrophy has been treated with botulinum toxin injections because of esthetic complaints especially in Asians.

OBJECTIVES: The goal of the present study was to evaluate the efficacy of abobotulin toxin use in masseter hypertrophy treatment in Brazilians.

METHODS: Ten Brazilian female patients with masseter hypertrophy were subjected to injections of 90U of abobotulinum toxin A applied on each side respecting the safety zone established in literature and were followed up for 24 weeks.

RESULTS: When analyzing the coefficients between measures of middle and lower third of the face obtained from standardized photographs, an increase was observed, with statistical significance at 2 weeks ($p=0.005$) and 12 weeks ($p=0.001$). The progression of lower third reduction was 3.94%, 5.26%, 11.99%, and 5.47% (2, 4, 12, and 24 weeks respectively). All patients showed improvement in bruxism after treatment. Observed adverse effects were masticatory fatigue, smile limitation, and smile asymmetry.

CONCLUSION: The use of abobotulinum toxin A for masseter hypertrophy is effective in Brazilians and reached its maximum effect of facial thinning at 12 weeks. Smile limitation had a higher incidence compared to that reported in the literature and may result from risorius muscle blockage caused by toxin dissemination. Despite its side effects, 80% of the patients would like to repeat the treatment.

Keywords: Botulinum toxins, type A; Face; Masseter muscle

INTRODUCTION

Men and women are influenced by culturally determined standards of beauty. Triangular and heart-shaped faces are considered delicate, while faces with increased lower volume are seen as "rude" in many cultures.^{1,2} Lower facial contour is determined by the mandibular bone and by soft tissues, such as skin, subcutaneous tissue, and masseter muscle. The main causes of wide lower third of the face (square face) are prominent mandibular angle and muscle hypertrophy.

In clinical terms, masseter hypertrophy presents as a symmetrical or asymmetrical increase in the masseter muscle. It occurs more frequently between 20 and 40 years old, is not gender-specific, and is more common in the Asian population.³ This condition was firstly described by Legg in 1880 and still have an unknown origin. Some of its possible causes include masticatory hyperactivity and stomatognathic system dysfunctions, but these conditions are not present in all cases.^{3,4}

Masseter hypertrophy has been clinically treated because of esthetic complaints. Available treatments go from combined muscle and bone resection to injections of botulinum toxin on the masseter muscle. The use of this toxin was first described in 1994, and since then several studies on this technique have been published, many of them conducted in Asia.^{1,2,4-22}

The efficacy of injections of botulinum toxin in reducing the volume of the masseter muscle has been proven by ultrasound, computed tomography, electromyography, and three-dimensional scanning, as well as by photographs and assessment of patients' satisfaction.^{2,7,9,11,12,15} Although this technique has shown good results, the dosage of the toxin and the injection site have not been well established yet, and its use in the non-Asian population has been little investigated in the literature.

Five botulinum toxin type A preparations are commercially available: onabotulinum toxin A (BOTOX, Allergan Inc., Irvine, CA, USA), abobotuli-

Received on 05.10.2013.

Approved by the Advisory Board and accepted for publication on 07.12.2013.

* Work conducted at the Dermatology Service of Hospital de Clínicas da Universidade Federal do Paraná (UFPR) - Curitiba (PR), Brazil.

Financial Support: The botulinum toxin type A used in this study was donated by Galderma Laboratories.

Conflict of Interest: None.

¹ Private practice particular - Criciúma (SC), Brazil.

² Universidade Federal do Paraná (UFPR) - Curitiba (PR), Brazil.

num toxin A (Dysport, Ipsen Limited, Wrexham, UK), BOTOX (Allergan, Irvine, CA, USA), BTXA (Prosigne, Lanzhou Institute, Lanzhou, China), incobotulinum toxin A (Xeomin, Mers Pharmaceutics, Frankfurt AM Main, Germany), and Neuronox (Medytox Inc., Cheonwon-gun, South Korea).²³ Previous studies on the use of botulinum toxin type A for the treatment of masseter hypertrophy have used different preparations and different dosages. This lack of standardization hampers the comparison between studies. Two studies compared different dosages: in 2005, Choe et al. compared the efficacy of doses of 10, 20 and 30U of onabotulinum toxin A and concluded that satisfactory results are achieved with doses above 20U on each side.¹⁰ In 2007, Kim et al. compared the effects of 25 and 35U of onabotulinum toxin A without observing a statistically significant difference between the groups.¹⁴ Some authors make use of ultrasound to determine the dose depending on the measured volume of each muscle, but this method is difficult to implement in the reality of the clinical practice.^{7,11}

The ultimate objective of the several authors who studied the topic is also different. Some of them aim to achieve muscle atrophy by reapplying the toxin based on patient's complaint, but other authors recommend performing monthly applications of the toxin until there is no muscle activity, with frequent booster doses to prevent muscle strength to recover by more than 30%.^{2,11} With regard to the injection site, there is a trend to work on a safe area established after careful anatomical observation and perception of adverse effects.^{9,13,19} This area is limited to an area from the lower implantation of the ear to the mouth angle. The anterior edge of the masseter muscle was determined by palpation after the patients are asked to grind their teeth (Figure 1).

The aim of the present study was to evaluate the efficacy of and patient satisfaction with the treatment of masseter hypertrophy for lower facial remodeling using 90U of abobotulinum toxin A given on each side on the face within the safe area determined by the literature, in a sample of 10 Brazilian patients followed up for 6 months.

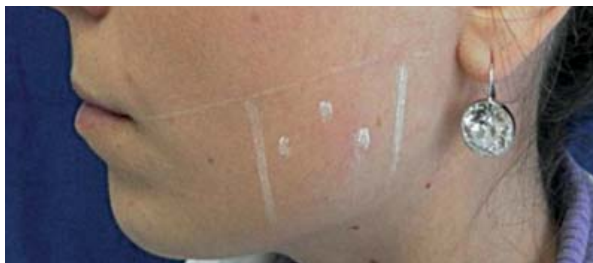

FIGURE 1: Delimitation of the safe area - a line from around the lower portion of the ear to the angle of the mouth - and delimitation of the anterior and posterior portions of the muscle through muscle palpation with patients grinding their teeth. Sites of toxin application marked within the safe area.

MATERIALS AND METHODS

Ten female patients with masseter hypertrophy detected on physical examination were followed up for 6 months after receiving injections of botulinum toxin type A. We used abobotulinum toxin A (Dysport, distributed in Brazil by Galderma Laboratories) diluted in 1.66ml of 0.9% saline solution and applied with a ultra-fine BD syringe at a dose of 90U on each side of the face (assuming an equivalence of 1:3 - in units of onabotulinum toxin A: 30U). First, a safe area for the application of the injection was established by delimiting a line between the mouth angle and the lower implantation of the ear, with patients strongly grinding their teeth. Anterior and posterior edges of the muscles were also outlined, with the ramus of the mandible being the lower border of the area that was considered safe for the procedure. Three 30U injections were applied on each side of the face, one at an upper central point and another two at lateral points 1 cm away from the initial point, totaling 90U (Figure 1).

Standardized photographs with the muscles relaxed and with patients grinding their teeth were taken before treatment and 2 weeks, 4 weeks, 12 weeks, and 24 weeks after treatment. Measurements for the width of middle and lower face were obtained using the photographs, and a coefficient between middle and lower thirds of the face was determined to represent the proportion between measures of the zygoma and of the commissure of the lips. (Figure 2) This coefficient was compared at the different follow-up times, with the purpose of quantifying the probable increase in the proportion between middle and lower thirds resulting from the thinning of the lower face caused by masseter atrophy. Questionnaires for the assessment of pain, adverse effects, and satisfaction were applied, and the standardized images were evaluated by three dermatologists with regard to the perception of facial thinning. The discomfort during the application of the toxin was assessed by a numerical scale from 0 to 10 (0=no pain and 10=the more severe pain ever experienced).

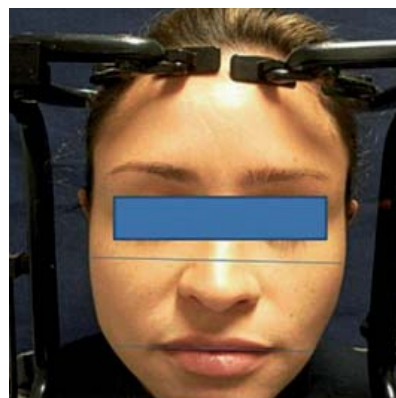


FIGURE 2: Figure showing how to measure middle and lower thirds of the face - at the level of the zygoma and of the commissure of the lips, respectively

Questions on the improvement in terms of patient's expectations about the treatment included five possible choices: 0 (none or worsening), 1-24% (discrete improvement), 25-49% (mild improvement), 50-74% (moderate improvement), and 75-100% (considerable improvement).

RESULTS

The sample consisted of 10 female patients aged between 25 and 40 years old (mean=28.8, median=27), 7 of which were of Caucasian descent and 3 of Asian descent. Eight of the 10 patients had bruxism. Fifty percent of the patients classified discomfort as grade 3,

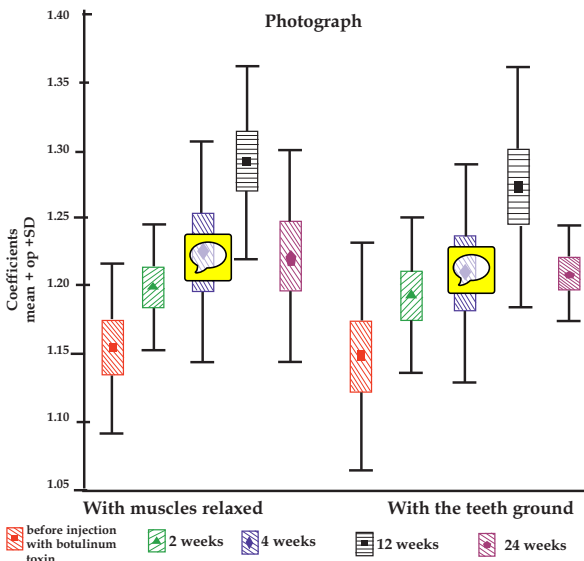
90% of them classified it as grade 1 to 3, and only one patient classified it as grade 5. There were follow-up failures for some patients, meaning that only 9 patients were photographed at 2 and 12 weeks, which justifies the use of non-decimal percentages.

The coefficients between middle and lower thirds of the face at the different time points showed an increase compatible with thinning of the lower face at all time points, with statistical significance at 2 and 12 weeks as assessed by the Student's t test (Table 1). The same trend was observed for the photographs in which patients ground their teeth. Graph 1 shows the pattern of facial thinning.

TABLE 1: Comparison of mean coefficients before injection with botulinum toxin vs. 2, 4, 12, and 24 weeks after botulinum toxin (picture with masseter relaxed and with the teeth ground). Pre-treatment coefficients used in the different comparisons are different because of lack of follow-up, as mentioned in the text

At the moment of evaluation	Coefficient with the teeth ground		Coefficient with muscles relaxed	
	Mean	p*	Mean	p*
Before injection	1.155		1.148	
2 weeks after injection	1.200	0.001	1.193	0.005
Difference (2 weeks - before treatment)	0.044		0.045	
Before injection	1.165		1.162	
4 weeks after injection	1.225	0.059	1.209	0.133
Difference (4 weeks - before injection)	0.060		0.048	
Before injection	1.155		1.148	
12 weeks after injection	1.291	0.000	1.273	0.001
Difference (12 weeks - before injection)	0.136		0.125	
Before weeks after injection	1.155		1.152	
24 weeks after weeks after injection	1.215	0.099	1.205	0.120
Difference (24 weeks - before injection)	0.060		0.053	

* Student's t test for paired samples, p<0.05.



GRAPH 1: Graphic presentation of mean coefficients with the muscle relaxed (left) and with the teeth ground (right) showing progressive facial thinning that reached its peak at 12 weeks and reduced at 24 weeks.

There was a clear reduction in the volume of the lower face, as evidenced by the increase in the coefficient between zygoma and commissure of the lips, which occurred in a progressive scale that reached its peak at 12 weeks and decreased at 24 weeks. In the photographs with the muscles relaxed, mean percentage of coefficient increase was 3.94% at 2 weeks, 5.26% at 4 weeks, 11.99% at 12 weeks, and 5.47% at 24 weeks. In the photographs with the teeth ground, the progression of coefficient increase was the following: 4.11%, 4.38%, 11.14%, 5.07% at 2, 4, 12, and 24 weeks respectively.(Table 2)

At 2 weeks, 44.4% of the patients classified improvement in facial appearance as discrete (1-24%), the same percentage as mild (25-49%), and 11.1% as moderate (50-74%). At 4 weeks, in turn, 20% of the patients classified improvement as discrete (1-24%), 40% as mild (25-49%), and 40% as moderate (50-74%). At 12 weeks, one patient reported worsening, 33.3% reported that there was mild improvement (25-49%), 44.4% that there was moderate improvement (50-74%), and 11.1% that there was considerable improve-

ment (75-100%). At 24 weeks, one patient reported worsening (the same one that reported it at 12 weeks), 50% reported discrete improvement (1-24%), 20% reported mild improvement (25-49%), and 20% reported moderate improvement (50-74%) (Table 3).

For the assessment of the degree of facial thinning, patients and dermatologists answered a question that also had five possible answers: 0 (worsening); 1-24% (discrete thinning); 25-49% (mild thinning); 50-74% (moderate thinning); and 75-100% (considerable thinning, with 100% meaning that thinning reached a point in which the length was similar to the one composed by only bone structures). At 2 weeks, 55.6% of patients classified facial thinning as discrete (1-24%), 33.3% as mild (25-49%), and 11.1% as moderate (50-

74%). At 4 weeks, 20% of patients reported discrete thinning (1-24%), 40% reported mild thinning (25-49%), and 40% reported moderate thinning (50-74%). At 12 weeks, one patient reported worsening, 22.2% reported mild thinning (25-49%), 55.6% reported moderate thinning (50-74%), and 11.1% reported considerable thinning (75-100%). At 24 weeks, one patient still reported worsening, 50% reported discrete thinning (1-24%), 10% reported mild thinning (25-49%), and 30% reported moderate thinning (50-74%) (Table 3).

According to dermatologists' evaluation (considering mean percentages for the three dermatologists), at 2 weeks, 70% of the patients showed mild thinning (25-74%) and 30% showed discrete thinning (1-24%). After 4 weeks, dermatologists believed that

TABLE 2: Mean difference in coefficients between coefficients measured before injection with botulinum toxin and coefficients obtained 2, 4, 12 and 24 weeks after injection, expressed in percentages

	Mean Difference (%) with muscles relaxed	Mean Difference (%) with teeth ground
2 weeks after injection – before injection	3.94	4.11
4 weeks after injection – before injection	5.26	4.38
12 weeks after injection – before injection	11.99	11.14
24 weeks after injection – before injection	5.47	5.07

TABLE 3: Percentages of answers from patients and dermatologists with regard to improvement in facial appearance and to facial thinning

Time	Possible answers	Percentage of improvement according to patients' evaluation	Percentage of facial thinning according to patients' evaluation	Percentage of facial thinning according to dermatologists' evaluation
2 weeks	Worsening			
	1-24%	44.4	55.6	30
	25-49%	44.4	33.3	70
	50-74%	11.1	11.1	
4 weeks	Worsening			
	1-24%	20.0	20.0	11.1
	25-49%	40.0	40.0	77.8
	50-74%	40.0	40.0	11.1
12 weeks	Worsening	11.1	11.1	
	1-24%		10	
	25-49%	33.3	22.2	50
	50-74%	44.4	55.6	40
24 weeks	Worsening	11.1	10	
	1-24%	44.4	50	40
	25-49%	22.2	10	60
	50-74%	22.2	30	

11.1% of patients showed discrete thinning (1-24%), 77.8% showed mild thinning (25-49%), and 11.1% showed moderate thinning (50-75%). At 12 weeks, 10% of the patients showed discrete thinning (1-24%), 50% showed mild thinning (25-49%), and 40% showed moderate thinning (50-74%). At 24 weeks, 40% of the patients showed discrete thinning (1-24%), and 60% showed moderate thinning (25-49%) (Table 3).

With regard to adverse effects, at 2 weeks, 4 patients had masticatory fatigue and 2 had smile limitation. At 4 weeks, 5 patients had masticatory fatigue, 6 had smile limitation, and 2 had smile asymmetry. At 12 weeks, 3 patients still had smile limitations, and none of them showed masticatory fatigue. At 24 weeks, none of the patients had any changes in mastication or smile. Two of the 3 patients (66.6%) of Asian descent and 4 of the 7 patients (57.1%) of Caucasian descent reported smile limitation.

All patients that had bruxism showed improvement after treatment. This improvement remained in 7 of the 8 patients for more than 3 months, and only 1 patient reported recurrence of the disease. At 24 weeks, only 1 patient still had improvement from bruxism, and it relapsed in all of the remaining patients.

When questioned, at the end of the follow-up period, whether they intended to repeat the application of botulinum toxin for facial contour remodeling, 80% of the patients decided to repeat the treatment, despite its adverse effects.

DISCUSSION

The efficacy of the use to botulinum toxin type A in reducing lower facial volume has been proven by several imaging methods and by photographic analyses.^{2,7,9,11,12,15,20,24} Data obtained in the present study are in agreement with those of the literature. According to the analysis of the coefficient between measures for middle and lower thirds of the face, which were taken using photographs obtained at standardized distance and positioning, this technique showed to be effective in thickening the face at 2 weeks (p=0.000) and at 12 weeks (p=0.000) in photographs with the muscles relaxed and at the same time points in photographs with the teeth ground (p=0.005 and p=0.001 respectively) (Figure 3).

Previous studies quantified the percentage of reduction in masseter volume using imaging methods. In 2003, Kim et al. observed a 22% reduction in muscle volume by means of computed tomography, and, in 2007, Yu et al. quantified the reduction in masseter volume in 30% by means of three-dimensional tomography.^{9,13} The maximum percentage of reduction obtained in our study was 11.9%, but it is worth emphasizing that this reduction represents a comparison between pre- and post-treatment coefficients and not

between muscle volume; thus, numerical comparisons with previous studies are out of the scope of the present paper.

The evolution of the reduction in lower facial volume was in agreement with that described by previous studies that adopted similar follow-up periods.^{9,12-14} At 2 weeks, a discrete reduction in volume was observed, and it reached its maximum effect at 12 weeks. The effect of botulinum toxin on the masseter muscle for facial remodeling differs from that expected in the treatment of facial wrinkles, because, with the latter, a reduction in muscle movement is expected, which is thus obtained more promptly.⁴ In the case of masseter hypertrophy, it involves hyperactivity and atrophy due to lack of use. Excessive muscle workout leads to muscle hypertrophy and increased muscle volume, and muscle paralysis caused by the toxin leads to atrophy and gradual reduction in muscle volume, which requires a longer time to be perceived.¹¹

Four of the 10 patients reported masticatory fatigue 2 weeks after the application of the toxin. The same complaint was reported by 5 patients after 4 weeks and remained for at least 2 months. Bite strength is reduced, as shown by the studies of Yu & Kim and Ahn et al., both from 2007, and of Kim et al., from 2009.^{4,13,16} This reduction starts in the first week of

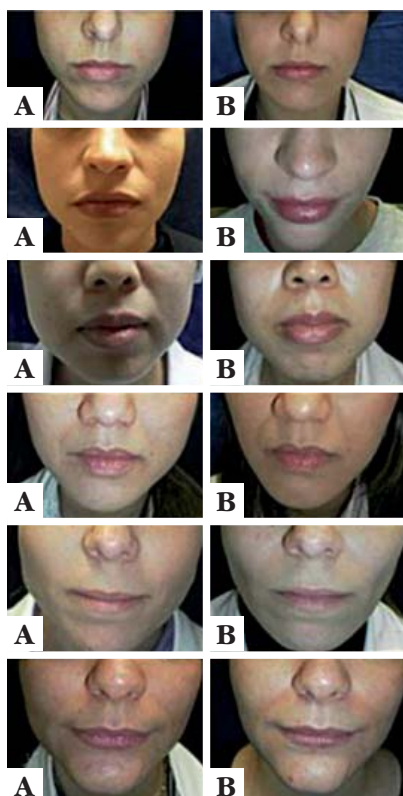


FIGURE 3: Examples of results - images obtained before treatment on the left (A) and after 3 months on the right (B)

treatment, in parallel to muscle denervation, which remains for 3-4 months and culminates in muscle atrophy. However, strength is recovered after nearly 3 weeks, probably because of the compensatory action of the other muscles of mastication, such as the temporalis muscle.¹⁵

Other reported adverse effects were smile limitation in 6 of the 10 patients, and smile asymmetry in 2 patients (Figure 4). Similar percentages were observed among patients with Caucasian and Asian descent, which, despite the small sample, indicates that there is no association between these conditions and ancestry. The incidence of smile limitation was higher than what could be expected from previous studies.^{2,9,11,13,17,25} In 2003, Kim et al. found an incidence of 3 out of 11 patients presenting with change in facial expression and inability to raise the corner of the mouth when smiling.⁹ Such occurrence was attributed to the paralysis of the zygomaticus major muscle caused by diffusion of the toxin injected on the upper portion of the masseter muscle. Of the 1021 patients treated by Kim et al. in a study published in 2005, only 2% reported changes in smile, with inability to raise the corners of the mouth to the extent they could prior to the initial injection, and complained of changes in social life. This study respected the safe area that spares the upper region of the masseter. The main causes for this condition may be paralysis of the risorius muscle and lower tension in the aponeurotic system due to a drastic reduction in muscle volume.¹¹ In 2008, Liew and Dart reported a limitation in smile amplitude in 2 out of 34 white patients and attributed this finding to the paralysis of risorius and buccinator muscles, bearing in mind the need of respecting the safe area.²⁵ In 2010, Wu reported an experience with more than 600 patients and pointed out the loss of full smile as a possible adverse effect due to migration of the toxin to risorius and levator anguli oris muscles.²

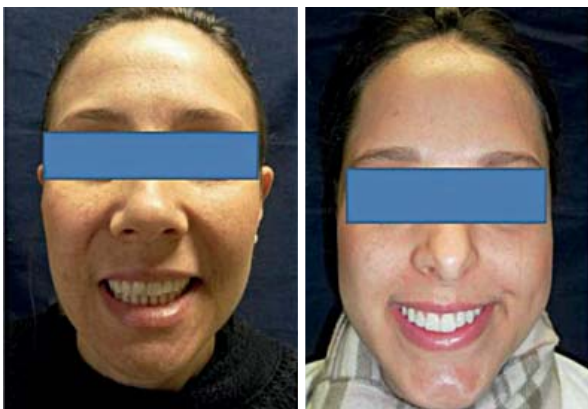

FIGURE 4: Smile asymmetry associated with smile limitation in 2 patients

Patients complained of reduced smile amplitude only in cases of smile asymmetry; the other patients presenting with this condition reported it only after being questioned. The incidence of smile limitation seems to be underdiagnosed in other studies.

Other possible adverse effects reported in the literature are: sunken cheeks, local edema, ecchymosis, pain on the injection site, headache, and dry mouth, all of them localized and transient, not exceeding 2 months.^{2,9,11,13,14,17,25} These effects did not occur in the patients followed-up in the present study. Aggravation of a venous malformation not diagnosed prior to treatment was reported by Choi et al. in 2010.¹⁸ Respecting the safe area minimizes adverse effects, especially sunken cheeks, which results from the action of the zygomaticus major muscle due to the injection of the toxin on the upper portion of the muscle leading to prominent zygoma and cadaveric facies.⁹

Eight of the 10 patients repeated the treatment. The main reason why other patients refused to repeat the injection of botulinum toxin was smile asymmetry, observed in 2 patients.

The presence of bruxism was subjectively evaluated in our study by simply asking the patients about its presence and possible improvement with treatment. In 2008, Liew et al. pointed to this improvement, which was confirmed in our study.²⁵ Eight of the ten patients studied presented with the disorder, and all of them reported that the treatment lead to an improvement that lasted for 3 months, on average. The lack of objectiveness in the assessment of this condition and our small sample size makes it impossible to draw grounded conclusion on the topic.

Facial volume remained reduced after 6 months, which has also been described in previous studies.^{11,12,25} This may result from the fact that muscle volume recovered to baseline levels but there was no muscle hypertrophy anymore, which results from hyperactivity. This is the reason why recovery was so slow. This finding underlines the need of pondering which is the best dosage to be used in a booster treatment, since the muscle will require a smaller number of units, and an excessive number of units will magnify adverse effects, especially the reduction in bite strength.

This study evaluated only one application of botulinum toxin per patient. Studies based on authors' experiences recommend giving booster doses one to four times a year.^{2,11} Therefore, like in the treatment for facial wrinkles, recurrent treatments lead to a longer interval for volume recovery and to the need of a smaller number of units.²

CONCLUSION

It is concluded that the use of abobotulinum toxin A for the treatment of masseter hypertrophy at a

dosage of 90U is effective in lower facial remodeling. Patients want to have triangular or heart-shaped faces because these facial shapes are culturally considered as more delicate. Additionally, current therapeutic approaches tend to reestablish the triangular-shaped face predominant in youth. Treatment for muscle hypertrophy is a simple technique that may be successful in indicated cases and shows a high degree of

satisfaction. Improvement in bruxism occurred in 100% of the patients affected by this condition, but this finding should be confirmed by objective data. Smile limitation even when injection were applied only within the safe area is a limiting factor that should be pointed out to candidates for botulinum toxin therapy before they undergo the procedure. □

REFERENCES

- Chang CS, Bergeron L, Yu CC, Chen PK, Chen YR. Mandible changes evaluated by computed tomography following Botulinum Toxin A injections in square-faced patients. *Aesthetic Plast Surg.* 2011;35:452-5.
- Wu WT. Botox facial slimming/facial sculpting: the role of botulinum toxin-A in the treatment of hypertrophic masseteric muscle and parotid enlargement to narrow the lower facial width. *Facial Plast Surg Clin North Am.* 2010;18:133-40.
- von Lindern JJ, Niederhagen B, Appel T, Bergé S, Reich RH. Type A botulinum toxin for the treatment of hypertrophy of the masseter and temporal muscles: an alternative treatment. *Plast Reconstr Surg.* 2001;107:327-32.
- Ahn KY, Kim ST. The change of maximum bite force after botulinum toxin type A injection for treating masseteric hypertrophy. *Plast Reconstr Surg.* 2007;120:1662-6.
- Moore AP, Wood GD. The medical management of masseteric hypertrophy with botulinum toxin type A. *Br J Oral Maxillofac Surg.* 1994;32:26-8.
- Smyth AG. Botulinum toxin treatment of bilateral masseteric hypertrophy. *Br J Oral Maxillofac Surg.* 1994;32:29-33.
- To EW, Ahuja AT, Ho WS, King WW, Wong WK, Pang PC, Hui AC, et al. A prospective study of the effect of botulinum toxin A on masseteric muscle hypertrophy with ultrasonographic and electromyographic measurement. *Br J Plast Surg.* 2001;54:197-200.
- Hui AC. Botulinum toxin for treatment of masseteric hypertrophy. *J Neurol.* 2002;249:345.
- Kim HJ, Yum KW, Lee SS, Heo MS, Seo K. Effects of botulinum toxin type A on bilateral masseteric hypertrophy evaluated with computed tomographic measurement. *Dermatol Surg.* 2003;29:484-9.
- Choe SW, Cho WI, Lee CK, Seo SJ. Effects of botulinum toxin type A on contouring of the lower face. *Dermatol Surg.* 2005;31:502-7.
- Kim NH, Chung JH, Park RH, Park JB. The use of botulinum toxin type A in aesthetic mandibular contouring. *Plast Reconstr Surg.* 2005;115:919-30.
- Lee CJ, Kim SG, Kim YJ, Han JY, Choi SH, Lee SI. Electrophysiologic change and facial contour following botulinum toxin A injection in square faces. *Plast Reconstr Surg.* 2007;120:769-78.
- Yu CC, Chen PK, Chen YR. Botulinum toxin a for lower facial contouring: a prospective study. *Aesthetic Plast Surg.* 2007;31:445-51.
- Kim JH1, Shin JH, Kim ST, Kim CY. Effects of two different units of botulinum toxin type a evaluated by computed tomography and electromyographic measurements of human masseter muscle. *Plast Reconstr Surg.* 2007;119:711-7.
- Gaofeng L, Jun T, Bo P, Bosheng Z, Qian Z, Dongping L. Evaluation and selecting indications for the treatment of improving facial morphology by masseteric injection of botulinum toxin type A. *J Plast Reconstr Aesthet Surg.* 2010;63:2026-31.
- Kim KS1, Byun YS, Kim YJ, Kim ST. Muscle weakness after repeated injection of botulinum toxin type A evaluated according to bite force measurement of human masseter muscle. *Dermatol Surg.* 2009;35:1902-6.
- Kwon JS, Kim ST, Jeon YM, Choi JH. Effect of botulinum toxin type A injection into human masseter muscle on stimulated parotid saliva flow rate. *Int J Oral Maxillofac Surg.* 2009;38:316-20.
- Choi JH, Park SW, Chung HY, Choi KY, Chang HW, Kim JH, et al. Incidental aggravation of venous malformation after botulinum toxin type a injection for reducing benign masseteric hypertrophy. *Dermatol Surg.* 2010;36:2188-92.
- Hu KS, Kim ST, Hur MS, Park JH, Song WC, Koh KS., Topography of the masseter muscle in relation to treatment with botulinum toxin type A. *Oral Surg Oral Med Oral Pathol Oral Radiol Endod.* 2010;110:167-71.
- Shim WH, Yoon SH, Park JH, Choi YC, Kim ST. Effect of botulinum toxin type A injection on lower facial contouring evaluated using a three-dimensional laser scan. *Dermatol Surg.* 2010;36:2161-6.
- Andrade NN, Deshpande GS. Use of botulinum toxin (botox) in the management of masseter muscle hypertrophy: a simplified technique. *Plast Reconstr Surg.* 2011;128:24e-6e.
- Thomas MK, D'Silva JA, Borole AJ. Facial sculpting: Comprehensive approach for aesthetic correction of round face. *Indian J Plast Surg.* 2012;45:122-7.
- Kim SB, Ban B, Jung KS, Yang GH. A pharmacodynamic comparison study of different botulinum toxin type a preparations. *Dermatol Surg.* 2013;39:150-4.
- Arikan OK, Tan FU, Kendi T, Koc C. Use of botulinum toxin type A for the treatment of masseteric muscle hypertrophy. *J Otolaryngol.* 2006;35:40-3.
- Liew S, Dart A. Nonsurgical reshaping of the lower face. *Aesthet Surg J.* 2008;28:251-7.

MAILING ADDRESS:

Fernanda Homem de Mello de Souza Klein
Rua Cel Pedro Benedet, 488 1 andar sala 4
88801-250 - Criciúma - SC
Brazil
E-mail: dra.fernandaklein@gmail.com

How to cite this article: Souza-Klein FHM, Mulinari-Brenner F, Sato MS, Rosas-Robert FMB, Helmer KA. Lower facial remodeling with botulinum toxin type A for the treatment of masseter hypertrophy. *An Bras Dermatol.* 2014;89(6):878-84.