

WHAT IS THE DIAGNOSIS?

Case for diagnosis Caso para diagnóstico

Luna Azulay-Abulafia¹

Clarissa de Souza Abreu³

Maria de Fátima Guimarães Scotelaro Alves⁵

Marcela Duarte Villela Benez²

Carolina Villela da Rocha Miranda⁴

CASE REPORT

A 15-month old baby boy presented with asymptomatic lesions on his face that had appeared three months prior to his first consultation. There was no change in his general state of health, no comorbidities were present and he appeared normal at physical examination. Symmetrical erythematous-brownish papules of approximately 12 mm in diameter were present in the malar region (Figure 1). There was no associated systemic disease. To confirm the clinical suspicion, histopathology was carried out on the facial lesion. Findings showed a regenerated epidermis and papillary dermis with an infiltrate rich in pleomorphic histiocytes showing eosinophilic, non-foamy cytoplasm with no exocytosis, associated with a lymphocytic and eosinophilic infiltrate (Figure 2). Immunohistochemistry was negative for S100 and CD1a and positive for CD68 (Figures 3 and 4). The patient has been followed-up as an outpatient for two years now; however, the lesions have so far failed to involute. Exams are repeated regularly to ensure that no systemic disease is present.

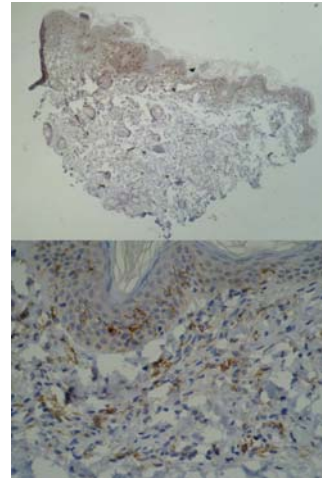


FIGURE 3: Negative immunohistochemistry for S100 and CD1a, respectively

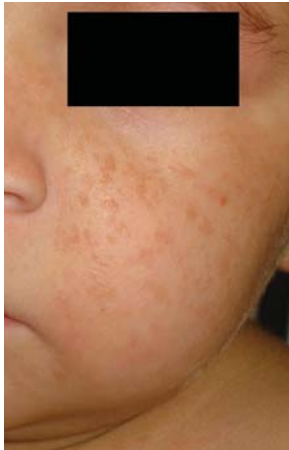

FIGURE 1: Papular, erythematous-brownish lesions in the malar region

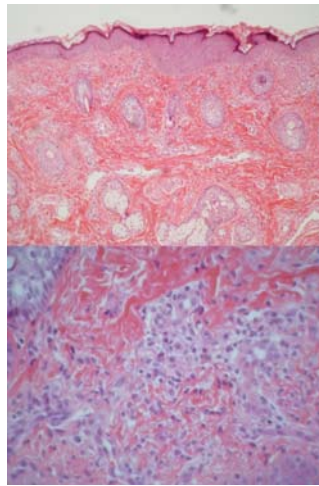


FIGURE 2: Histopathology showing the papillary dermal pattern of benign cephalic histiocytosis

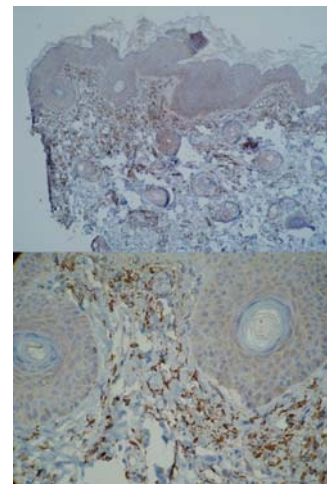


FIGURE 4: Positive immunohistochemistry for CD68

Received on 19.01.2011

Approved by the Advisory Board and accepted for publication on 29.01.2011.

* Study conducted at the Pedro Ernesto Teaching Hospital, State University of Rio de Janeiro, Rio de Janeiro, RJ, Brazil.

Conflict of interest: None / *Suporte Financeiro: Nenbum*

Financial funding: None / *Conflito de Interesses: Nenbum*

¹ PhD in Dermatology. Adjunct Professor of Dermatology, State University of Rio de Janeiro, Rio de Janeiro, RJ, Brazil.

² Postgraduate degree awarded by the Pedro Ernesto Teaching Hospital, State University of Rio de Janeiro, Rio de Janeiro, RJ, Brazil. Substitute Professor, Department of Dermatology, Pedro Ernesto Teaching Hospital, State University of Rio de Janeiro, Rio de Janeiro, RJ, Brazil.

³ Medical Residency. Pedro Ernesto Teaching Hospital, State University of Rio de Janeiro, Rio de Janeiro, RJ, Brazil.

⁴ Postgraduate degree awarded by the State University of Rio de Janeiro, Rio de Janeiro, RJ, Brazil.

⁵ PhD in Dermatology awarded by the Federal University of Rio de Janeiro. Adjunct Professor, Dermatology Department, Pedro Ernesto Teaching Hospital, State University of Rio de Janeiro, Rio de Janeiro, RJ, Brazil.

DISCUSSION

Histiocytoses constitute a group of diseases characterized by the proliferation of cells from the mononuclear phagocytic and dendritic cell systems, and are classified into Langerhans and non-Langerhans cell histiocytosis. Benign cephalic histiocytosis is a non-Langerhans cell histiocytosis. It is a rare proliferative disorder of which only 40 cases have been described. To the best of our knowledge, no cases have been reported in the literature in Brazil. This disease was first described by Gianotti in 1971 as an infantile histiocytosis with cytoplasmic worm-shaped bodies that affects the face of children during their first year of life. Its etiology is unknown. Some investigators believe that it is a variant of juvenile xanthogranuloma (JX) or generalized eruptive histiocytoma or perhaps they all belong within the spectrum of one single disease.^{1,4}

Benign cephalic histiocytosis (BCH) is characterized by red or reddish-brown macules or papules of 25 mm in diameter that initially appear on the face and go on to affect the ears and neck. They may occasionally appear on the trunk and arms; however, it is rare for them to affect the legs or gluteal region.^{1,3,4,5} Most of the affected children are healthy and have no mucosal or systemic involvement. Nevertheless, there has been a report of an association with diabetes insipidus (DI) and another with type 1 diabetes mellitus.^{6,7} Other histiocytoses such as JX may also be associated with DI.⁸ BCH lesions heal spontaneously after months or years; however, exacerbations may occur and the condition may relapse, presenting as JX.^{1,4}

Its diagnosis is clinical and can be confirmed by histopathology and immunohistochemistry. Histopathology pre-

sents three characteristic patterns: papillary dermal, diffuse and lichenoid. The first pattern is the most common and is characterized by the presence of a well-defined infiltrate close to the epidermis. This was the pattern presented by the patient in this report. The histiocytes present are pleomorphic and present hyperchromatic nuclei and large nucleoli. It is also associated with an infiltrate of lymphocytes and eosinophils, with no exocytosis of histiocytes. In the diffuse form, the infiltrate is diffuse in the dermis and the histiocytes are rare, pleomorphic, round, regular and with little cytoplasm. Finally, the lichenoid pattern consists of small, regular histiocytes and rare perivascular lymphocytes in the upper dermis. There are no Touton cells or foamy cells in any of the three forms.^{1,4} At immunohistochemistry, this type of histiocytosis is S100 and CD1a-negative and expresses positivity for CD11b, Cd14b, CD68, HAM56 and factor XIIIa. This patient presented the expected immunohistochemical patterns. Electronic microscopy shows cytoplasm with comma-shaped bodies, worm-shaped bodies and junctional structures resembling desmosomes among the histiocytes.^{1,4}

Differential diagnosis should be made with JX, generalized eruptive xanthoma, Spitz nevus and with Langerhans cell histiocytosis.^{1,4}

Benign cephalic histiocytosis does not require any specific treatment, since it is a self-limiting disease; however, the possibility of diabetes insipidus or diabetes mellitus should be evaluated and the patient should be followed up on an outpatient basis to monitor for any exacerbations.^{1,7} □

Abstract: The present paper reports a case of benign cephalic histiocytosis in a 15-month baby boy, who developed multiple papules bilaterally in the malar region with no other associated manifestations. Histopathology revealed a papillary dermal pattern, while immunohistochemistry was negative for S100 and CD1a and positive for CD68. Therefore, diagnosis was established as non-Langerhans cell histiocytosis, based on the clinical, histopathological and immunohistochemical features present.

Keywords: Histiocytosis; Histiocytosis, non-langerhans-cell; Xanthogranuloma, juvenile

Resumo: Relatamos um caso de histiocitose cefálica benigna em uma criança do sexo masculino, de um ano e três meses de idade que desenvolveu múltiplas pápulas na região malar bilateralmente, sem outros comemorativos associados. A histopatologia caracterizou-se pelo padrão derme papilar, com imuno-histoquímica negativa para S100 e CD1a, e positiva para CD68, ficando assim estabelecido o diagnóstico desta histiocitose não-Langerhans, baseado nos aspectos clínicos, histopatológicos e imuno-histoquímicos característicos.

Palavras-chave: Histiocitose; Histiocitose de células não Langerhans; Xantogranuloma juvenil

REFERENCES

1. Bologna JL, Jorizzo, Rapini RP. *Dermatology*. 2nd ed. v. 1. Nova York: Mosby Elsevier; 2008.
2. Hasegawa S, Deguchi M, Chiba-Okada S, Aiba S. Japanese case of benign cephalic histiocytosis. *J Dermatol*. 2009;36:69-71.
3. Jih DM, Salcedo SL, Jaworsky C. *J Am Acad Dermatol*. Benign cephalic histiocytosis: a case report and review. *J Am Acad Dermatol*. 2002;47:908-13.
4. Luz FB, Gaspar AP, Kalil-Gaspar N, Ramos-e-Silva. Os histiócitos e as histiocitoses não Langerhans em dermatologia. *An Bras Dermatol*. 2003;78:99-118.
5. Dadzie O, Hopster D, Cerio R, Wakeel R. Benign cephalic histiocytosis in a British-African child. *Pediatr Dermatol*. 2005;22:444-6.
6. Weston WL, Travers SH, Mierau GW, Heasley D, Fitzpatrick J. Benign cephalic histiocytosis with diabetes insipidus. *Pediatr Dermatol*. 2000;17:296-8.
7. Saez-De-Ocariz M, Lopez-Corella E, Duran-McKinster C, Orozco-Covarrubias L, Ruiz-Maldonado R. Benign cephalic histiocytosis preceding the development of insulin-independent diabetes mellitus. *Ped Dermatol*. 2006;23:1012.
8. Miranda PA, Miranda SM, Bittencourt FV, Machado LJ, Castro LP, Leite VH, et al. Cutaneous nonLangerhans cells histiocytoses as cause of central diabetes insipidus. *Arq Bras Endocrinol Metab*. 2007;51:1018-22.

MAILING ADDRESS / ENDEREÇO PARA CORRESPONDÊNCIA:
Luna Azulay-Abulafia
Boulevard 28 Setembro, 51 - Vila Isabel
CEP: 20551-030 - Rio de Janeiro - RJ, Brazil
E-mail: lunaazulay@gmail.com /
mabenez@botmail.com

How to cite this article/Como citar este artigo: Azulay-Abulafia L, Benez MDV, Abreu CS, Miranda CVR, Alves MFGS. What is the diagnosis? Non-Langerhans cell histiocytosis: a case report on benign cephalic histiocytosis. *An Bras Dermatol*. 2011;86(6):1222-32.