

Dermscopic features of clear cell acanthoma*

Daniela Gomes Cunha¹
Luisa Kelmer Côrtes de Barros Silveira¹

Luiza Erthal de Britto Pereira Kassuga-Roisman¹
Fabiane Carvalho de Macedo²

DOI: <http://dx.doi.org/10.1590/abd1806-4841.20186977>

Abstract: Clear cell acanthoma is an uncommon type of benign epithelial tumor. Typically, it is a solitary lesion found on the lower limbs. It presents as a nodule or small plaque with slow and well-defined growth. Diagnosis used to be clinical and histopathological, but the advent of dermoscopy has led to an increase in diagnostic accuracy. We describe a case in which dermoscopy proved highly useful for diagnosis of the lesion.

Keywords: Acanthoma; Dermoscopy; Diagnostic imaging; Diagnosis

Clear cell acanthoma is a rare benign epithelial tumor with unknown etiology. It manifests clinically as a papular-nodular lesion or a small rounded erythematous plaque on the lower limbs of middle-aged adults. Women and men are affected with equal frequency, and there is no racial predilection. It is typically a solitary tumor, but there are cases with multiple lesions.

Male patient, age 64 years, reported the appearance of a nodular and erythematous lesion on the left buttock, which had occurred approximately two years previously. Dermatologic examina-

tion revealed a solitary, well-defined purple-erythematous nodular lesion, covered with discreet exudate (Figure 1).

Dermoscopy showed glomerular and punctiform vessels with a "pearl necklace" distribution, an image highly characteristic of clear cell acanthoma (Figures 2 and 3).

Excisional biopsy of the lesion with histopathological examination showed dilated blood vessels in the dermal papillae and proliferation of clear keratinocytes, with sharp demarcation in relation to the normal epidermis, consistent with clear cell acanthoma (Figures 4 and 5).

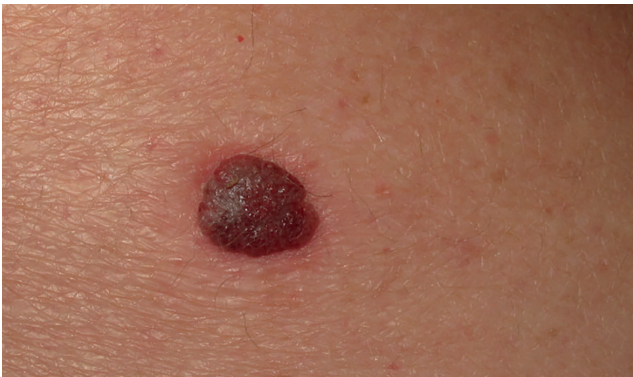

FIGURE 1: Clinical photograph of clear cell acanthoma. Nodular brown lesion with erythema located on the left buttock

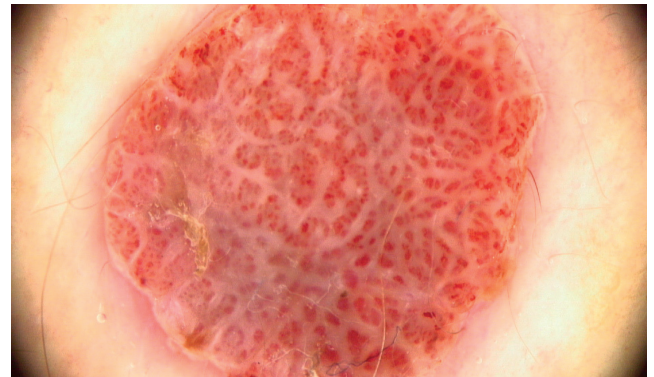


FIGURE 2: Dermoscopy with polarized light showing glomerular vessels with "pearl necklace" distribution (X20 magnification)

Received 31 January 2017.

Accepted 13 April 2017.

* Work conducted at the Oncologic Dermatology Service, Instituto Nacional do Câncer (Inca), Rio de Janeiro (RJ), Brazil.

Financial support: None.

Conflict of interest: None.

¹ Dermatology Service, Instituto Nacional do Câncer (Inca), Rio de Janeiro (RJ), Brazil.

² Pathology Division, Instituto Nacional do Câncer (Inca), Rio de Janeiro (RJ), Brazil.

MAILING ADDRESS:

Daniela Gomes Cunha D'Assumpção
E-mail: danielagcunha@gmail.com

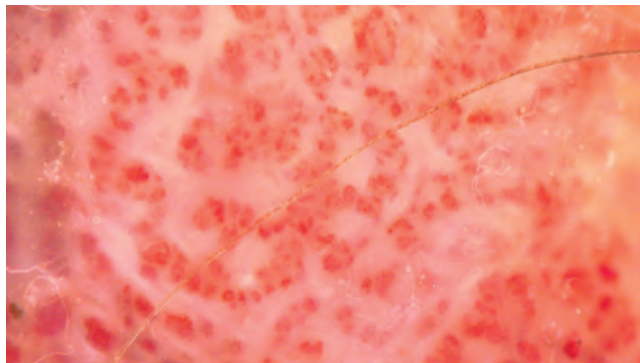


FIGURE 3: Detail of glomerular vessels, (X50)

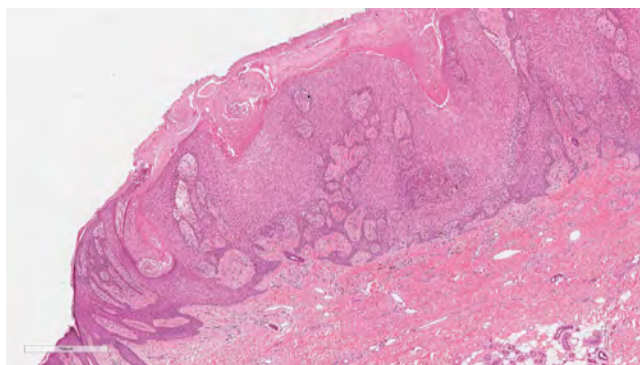


FIGURE 4: Histopathological examination showing irregular hyperplasia of the epidermis and keratinocytes with clear cytoplasm (Hematoxylin & eosin, X40)

Clear cell acanthoma is a rare tumor, first described by Degos in 1962.¹ It presents as a slow-growing papular-nodular lesion or erythematous plaque, frequently located on the legs. The tumor is usually asymptomatic and solitary, but occasionally patients present multiple lesions.² There may be a peripheral epidermal col-

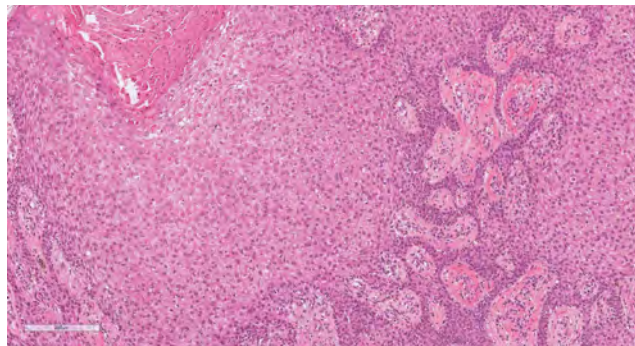


FIGURE 5: Histopathological examination with detail of keratinocytes with clear cytoplasm (Hematoxylin & eosin, X100)

llette or superimposed serous exudate. Clear cell acanthoma does not show an ethnic or gender predilection and shows a peak incidence between 50 and 60 years of age.³

Differential diagnoses include pyogenic granuloma, amelanotic melanoma, traumatized hemangioma, squamous cell carcinoma, Bowen's disease, basal cell carcinoma, irritated seborrheic keratosis, and psoriasis.³


Dermoscopy is an excellent diagnostic test, since it shows a highly characteristic pattern. The test shows glomerular or punctiform vessels arranged in linear patterns, with a pearl necklace appearance.⁴ The arrangement of the blood vessels differs from that of other lesions that present punctiform and glomerular vessels. In clear cell acanthoma, the vessels are organized in a reticular array, unlike other lesions such as psoriasis (punctiform vessels distributed homogeneously in the lesion) and Bowen's disease (glomerular vessels in clusters).⁵ When the lesion grows rapidly, dermoscopy may show a white peripheral Fillet, similar to that seen in pyogenic granuloma.⁶

Although dermoscopy is highly characteristic, histopathology is still necessary for the definitive diagnosis of clear cell acanthoma. □

REFERENCES

1. Degos R, Civatte J. Clear-cell acanthoma: experience of 8 years. *Br J Dermatol.* 1970;83:248-54.
2. Trau H, Fisher BK, Schewach-Millet M. Multiple clear cell acanthomas. *Arch Dermatol.* 1980;116:433-4.
3. Morrison LK, Duffey M, Janik M, Shamma HN. Clear cell acanthoma: a rare clinical diagnosis prior to biopsy. *Int J Dermatol.* 2010;49:1008-11.
4. Blum A, Metzler G, Bauer J, Rassner G, Garbe C. The dermoscopic pattern of clear-cell acanthoma resembles psoriasis vulgaris. *Dermatology.* 2001;203:50-2.
5. Lyons G, Chamberlain AJ, Kelly JW. Dermoscopic features of clear cell acanthoma: five new cases and a review of existing published cases. *Australas J Dermatol.* 2015;56:206-11.
6. Zalaudek I, Hofmann-Wellenhof R, Argenziano G. Dermoscopy of clear-cell acanthoma differs from dermoscopy of psoriasis. *Dermatology.* 2003;207:428.

Daniela Gomes Cunha  ORCID 0000-0003-3841-9811
Luiza Erthal de Britto Pereira Kassuga-Roisman  ORCID 0000-0001-8403-7764

Luisa Kelmer Côrtes de Barros Silveira  ORCID 0000-0002-9000-2362
Fabiane Carvalho de Macedo  ORCID 0000-0002-8359-7564

How to cite this article: Cunha DG, Kassuga-Roisman LEBP, Silveira LKCB, Macedo FC. Dermoscopic features of clear cell acanthoma. *An Bras Dermatol.* 2018;93(3):449-50.