

## Severe Darier's disease in a psychiatric patient\*

Jeane Jeong Hoon Yang<sup>1</sup>  
Medéia Carolina Fernandes Pereira<sup>3</sup>  
Mário Cezar Pires<sup>1</sup>

Roberta Simão Lopes<sup>2</sup>  
Antonio Jose Tebcherani<sup>1</sup>

DOI: <http://dx.doi.org/10.1590/abd1806-4841.20153620>

**Abstract:** Darier's disease is characterized by dense keratotic lesions in the seborrheic areas of the body such as scalp, forehead, nasolabial folds, trunk and inguinal region. It is a rare genodermatosis, an autosomal dominant inherited disease that may be associated with neuropsychiatric disorders. It is caused by ATPA2 gene mutation, presenting cutaneous and dermatologic expressions. Psychiatric symptoms are depression, suicidal attempts, and bipolar affective disorder. We report a case of Darier's disease in a 48-year-old female patient presenting severe cutaneous and psychiatric manifestations.

**Keywords:** Bipolar disorder; Darier's disease; Genetic pleiotropy; Mental disorders

### INTRODUCTION

Darier's disease (DD) is characterized by the presence of hyperkeratotic papules which coalesce forming plaques due to alterations in the keratinization of the epidermis.<sup>1</sup> Nails, mucosae and long bones may also be involved.<sup>2</sup> There is association of Darier's disease and neuropsychiatric diseases. Data are consistent with the possibility that mutations in gene ATP2A2 may have pleiotropic effects on the skin and brain.<sup>3</sup>

### CASE REPORT

Female patient, 48 years old, of Asian origin, presents skin thickening and pruritus since the end of infancy. She was diagnosed with DD at 30 years of age, when there was also the onset of psychiatric symptoms, defined as bipolar affective disorder 5 years ago. Regarding her family history, her mother, deceased, carried DD and non-specified mental disorders; her maternal uncle also had the same cutaneous disorders. The dermatological examination revealed ex-

uberant plaques of hyperkeratotic surface on the face, abdomen, upper and lower limbs associated with fetid odor (Figures 1 and 2). All 20 nails were dystrophic with hyperkeratosis (Figure 3). At the psychiatric examination the patient was quiet, approachable, without any psychomotor agitation or confusional state. There was no evidence of affective lability, insomnia, hallucination or delirium, although personality was altered by impoverishment.

Anatomopathological examination of skin (right leg) demonstrated epidermis with parakeratosis, acantholytic keratinocytes in the granular and spinosum layer and suprabasal acantholytic cleft, compatible with Darier's disease (Figure 4). Since starting follow-up at the dermatology service, she has been hospitalized several times for secondary skin infections, as well as suicide attempts and hallucinatory deliriums.

Received on 13.04.2014

Approved by the Advisory Board and accepted for publication on 21.05.2014

\* Work performed at Complexo Hospitalar Padre Bento de Guarulhos - Guarulhos (SP), Brazil.

Financial Support: None.

Conflict of Interest: None.

<sup>1</sup> Complexo Hospitalar Padre Bento de Guarulhos (CHPBG) - São Paulo (SP), Brazil.

<sup>2</sup> Complexo Hospitalar Heliópolis - Heliópolis (SP), Brazil.

<sup>3</sup> Hospital Stella Maris - Guarulhos (SP), Brazil.

©2015 by Anais Brasileiros de Dermatologia

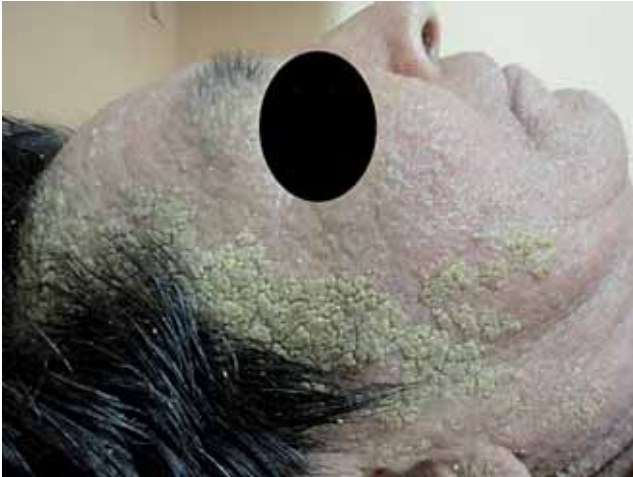

FIGURE 1: Darier's disease. Presence of keratotic and scaly lesions in the temporal and preauricular regions

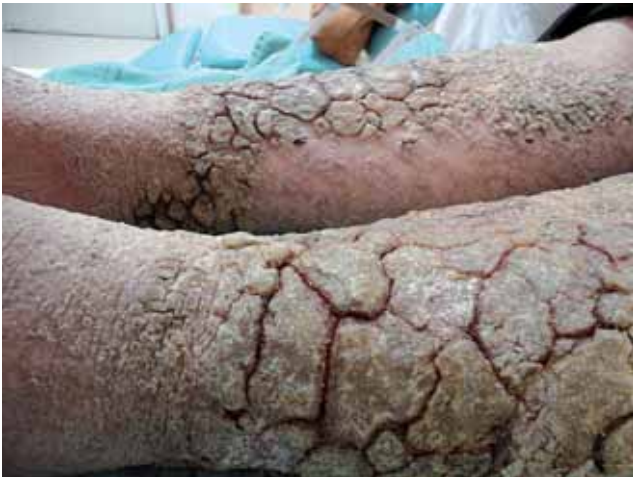

FIGURE 2: Darier's disease. Symmetric involvement of lower limbs with marked keratosis. There are fissures, which may lead to secondary infection

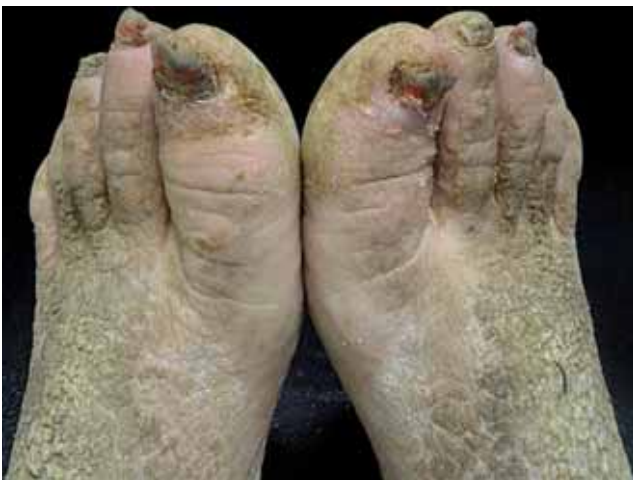

FIGURE 3: Darier's disease. Unguinal involvement with keratosis and dystrophy of nails in both feet

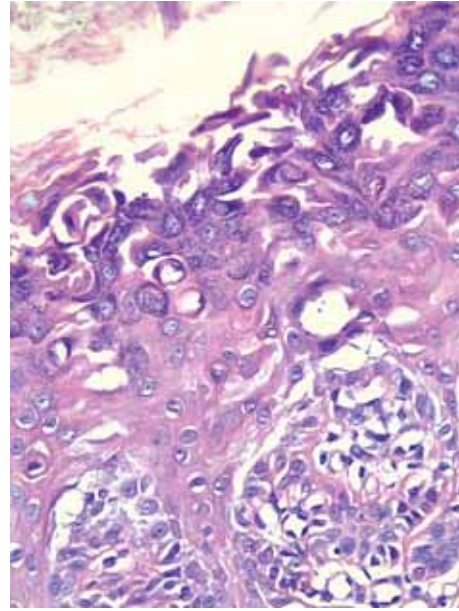


FIGURE 4: Darier's disease. Histopathological examination. HE. 200x. Epidermis with parakeratosis and acantholytic keratinocytes in the granular and spinosum layers. Observe the suprabasal acantholytic cleft

## DISCUSSION

DD occurs during adolescence and early adulthood. It affects both sexes equally.<sup>4</sup>

The classical form of DD is characterized by the gradual onset of hardened papules of verrucous plaques in seborrheic areas such as scalp, forehead, nasolabial folds, trunk and inguinal region. Eruption is usually symmetric. The most frequent symptom is pruritus. Fetid odor occurs mainly when skin folds are affected. This is in part the origin of sometimes considerable social isolation.<sup>4</sup> Our patient presented a characteristic strong odor, extensive verrucous plaques, more pronounced on the limbs, and intensive scaling. Other associated findings include unguinal abnormalities characterized by red and white longitudinal lines, onycholysis, distal fragility, sometimes a notch forming a "V" is distinguished in the free margin of nails and subungual hyperkeratosis. Sialolithiasis and cysts in long bones have occasionally been described in patients with DD.<sup>2,5</sup> At the time of our evaluation, there were no symptoms and signs of mucosae or osseous alterations, although she reported intense pruritus.

In rare occasions, the clinical picture is dominated by fragility of skin with painful erosions and fissures.<sup>5</sup> Our patient presented history of several hospitalizations for 8 years, due to skin infections secondary to fissures.

There are reports in literature of association of the disease with increased psychiatric morbidity such as depression, suicidal ideation and mood disorders.<sup>6</sup>

The DD gene was mapped for region 12q23-q24.1. The presence of a susceptibility gene for mood disorders in region 12q23 - q24 is backed by studies which associate the gene with bipolar affective

disorder and major depression. Observation is consistent with the hypothesis that some susceptibility genes contribute to both diseases.<sup>3</sup>

The Darier's disease locus was identified as the ATP2A2, which codifies a sarcoplasmic/endoplasmic reticulum calcium-ATPase, SERCA2. This gene presents potential susceptibility to bipolar disorder under the hypothesis that variations in SERCA2 have pleiotropic effects in the brain.<sup>3</sup> ATPase isoform 2 (protein SERCA2) is a calcium pump which keeps low concentrations of intracytoplasmic Ca<sup>2+</sup>, an important factor in the formation of epidermal desmosomes.<sup>5</sup>

Mood disorders, including bipolar disorder, major depression, suicide ideation and suicide attempts have been reported with high prevalence among individuals with DD.<sup>1,6</sup> The most commonly observed neuropsychiatric disease in patients with DD in a series of case reports was major depression.<sup>7</sup>

In a British study of patients with DD, 4% of the evaluated sample (total of 100 patients) were diagnosed with bipolar disorder (prevalence in the general population is estimated between 1-5%).<sup>8,9</sup> In 31% of

patients there was a history of suicidal thoughts and in 13%, suicidal attempts (prevalence in the United Kingdom estimated between 9-14% and 4%, respectively).<sup>10</sup> Our patient had suicide attempts during follow-up.

There is no specific treatment. The basic principles for the treatment are personal hygiene, as well as avoiding solar exposure, heat and excessive transpiration. Oral retinoids are frequently used and may be effective.<sup>6</sup> Not all patients tolerate acitretin. The use of this drug led to worsening of psychiatric symptoms in our patient.

To this day, the correlation of exuberant presentation of Darier's disease with psychiatric alterations such as bipolar affective disorder was not found in literature.

Our patient continues to follow good personal care and hygiene norms, using emollients and antipsychotic and anticonvulsant drugs. She is still being monitored both at our outpatient service and at the Center for Psychosocial Care (Centro de Atenção Psicossocial - CAPS) and at this time has a stable clinical picture. □

## REFERENCES

1. Burge S, Wilkinson DJ. Darier-White disease: a review of the clinical features in 163 patients. *J Am Acad Dermatol.* 1992;27:40-50.
2. Bale SJ, Toro JR. Genetic Basis of Darier-White Disease: Bad Pumps Cause Bumps. *J Cutan Med Surg.* 2000;4:103-6.
3. Green E, Elvidge G, Jacobsen N, Glaser B, Jones I, O'Donovan MC, et al. Localization of Bipolar Susceptibility Locus by Molecular Genetic Analysis of the Chromosome 12q23-q24 Region in Two Pedigrees With Bipolar Disorder and Darier's Disease. *Am J Psychiatry.* 2005;162:35-42.
4. Cheour M, Zribib H, Abdelhak S, Drira S, Osmanc AB. Les manifestations neuropsychiatriques de la maladie de Darier: résultat préliminaire d'une étude épidémioclinique et génétique de huit familles. Darier's disease: An evaluation of its neuropsychiatric component. *L'Encéphale.* 2009;35:32-5.
5. Godic A. Darier disease: A review of pathophysiological mechanisms. *Acta Dermatoven APA.* 2003;12:119-26.
6. Medansky RS, Woloshin AA. Darier's disease: an evaluation of its neuropsychiatric component. *Arch Dermatol.* 1961;84:482-4.
7. Ringpfeil F, Raus A, DiGiovanna JJ, Korge B, Harth W, Mazzanti C, et al. Darier disease - novel mutations in ATP2A2 and genotype-phenotype correlation. *Exp Dermatol.* 2001;10:19-27.
8. Gordon-Smith K, Jones LA, Burge SM, Munro CS, Tavadia S, Craddock N. The neuropsychiatric phenotype in Darier disease. *Br J Dermatol.* 2010;163:515-22.
9. Bebbington P, Ramana R. The epidemiology of bipolar affective disorder. *Soc Psychiatry Psychiatr Epidemiol.* 1995;30:279-92.
10. Meltzer H, Lader D, Corbin T, Singleton N, Jenkins R, Brugha T. Non-fatal Suicidal Behaviour among Adults aged 16 to 74 in Great Britain. London: The Stationery Office (Office for National Statistics); 2002.

## MAILING ADDRESS:

Jeane Jeong Hoon Yang  
Setor de Dermatologia  
Av. Emílio Ribas 1819- Jardim Tranquilidade  
07051-000 - Guarulhos - SP  
Brazil  
E-mail: jeanejhy@uol.com.br

**How to cite this article:** Yang JH, Lopes RS, Pereira MCF, Tebcherani AJ, Pires MC. Severe Darier's disease in a psychiatric patient. *An Bras Dermatol.* 2015;90 (3 Suppl 1): S66-8.