

Keratosis follicularis spinulosa decalvans - Case report

Queratose folicular espinulosa decalvante - Relato de caso

Alceu L. C. V. Berbert ¹

Ademir Rocha ³

Carolina M. Couto ⁵

Sônia A. O. Mantese ²

Cláudia P. Cherin ⁴

Abstract: Keratosis follicularis spinulosa decalvans is a rare disease, with genetic transmission either X-linked or sporadic, characterized by follicular hyperkeratosis and cicatricial alopecia. The disease usually begins in early childhood exacerbating throughout adolescence. The therapies are somewhat effective, with frustrating treatment when there are changes which are predominantly cicatricial. It is reported a case of child with intense cicatricial alopecia, with precocious changes (already present at birth) that rapidly evolved to diffuse cicatricial alopecia on the scalp, which has limited the treatment, with disappointing results.

Keywords: Hair follicle; Keratosis; Scalp dermatoses; Skin and connective tissue diseases

Resumo: A queratose folicular espinulosa decalvante é afecção rara, de transmissão genética ligada ao X ou esporádica, caracterizada por hiperqueratose folicular e alopecia cicatricial. Inicia-se, geralmente, na primeira infância, exacerbando-se na adolescência. As terapias são pouco efetivas, com tratamento frustrante, quando já há alterações predominantemente cicatriciais. Relata-se caso de criança com quadro de alopecia cicatricial intensa, com alterações precoces (já ao nascimento) e rápida evolução para alopecia difusa cicatricial do couro cabeludo, o que tornou o tratamento limitado e desapontador.

Palavras-chave: Ceratose; Dermatoses do couro cabeludo; Doenças da pele e do tecido conjuntivo; Foliculo piloso

INTRODUCTION

Keratosis follicularis spinulosa decalvans is a rare disease characterized by follicular hyperkeratosis and cicatricial alopecia. There are many sporadic cases but the most intensive manifestations are found in men suggesting a pattern of inheritance linked to X.^{1,2,3,4}

Manifestations of the disease start in childhood, frequently on the face, but it might be circumscribed to the face and extremities or generalized. Cicatricial alopecia on the scalp and supercilium is the marking characteristic of the disease. Some cases show association with corneal opacity, photophobia and palm-plantar hyperkeratosis that usually start in adolescence.^{1,2} Up to this moment a completely effective

therapy is not known.^{1,2,4,5}

There were not found in the medical literature studied Brazilian works related to this theme. It is reported here the case of a 5-year-old girl presenting intense and precocious follicular atrophy.

CASE REPORT

Female child, aged five, white, born from consanguineous parents (5th grade cousins). Reported absence of hairs at birth. As she grew fine, brittle and sparse hair appeared. It was not reported any other similar case in the family. No complaints of photophobia or case history of atopy. Dermatological exam:

Received on 13.08.2008.

Approved by the Advisory Board and accepted for publication on 19.12.2008.

* Study carried out in the Dermatological Service of the University Hospital of the Federal University of Uberlândia (HC/UFG) - Uberlândia (MG), Brazil.

Conflict of interest: None / *Conflito de interesse: Nenhum*

Financial funding: None / *Suporte financeiro: Nenhum*

¹ Assistant Professor of the Dermatological Service of the Federal University of Uberlândia (UFU) - Uberlândia (MG), Brazil.

² Associate Professor II of the Dermatological Service of the Federal University of Uberlândia (UFU) - Uberlândia (MG), Brazil.

³ Titular of the Service of Pathologic Anatomy of the Federal University of Uberlândia (UFU) - Uberlândia (MG), Brazil. (*In memoriam*).

⁴ Resident of the Dermatological Service of the Federal University of Uberlândia (UFU) - Uberlândia (MG), Brazil.

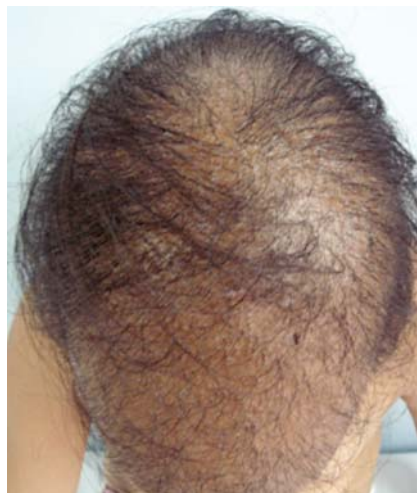⁵ Medical doctor, internship in Dermatology from the Federal University of Uberlândia (UFU) - Uberlândia (MG), Brazil.

hyperkeratotic papules associated with hipotrichosis, with fine, short, opaque and brittle hair, affecting the scalp, eyelashes and supercilia; follicular keratotic papules on the trunk and limbs. (Pictures 1, 2 and 3). Normal neuropsychomotor development and absence of ocular changes. Histopathologic examination of the scalp: lamellar hyperkeratosis in the follicular ostium, discrete superficial perivascular mononuclear infiltration and linear scar, vertical, corresponding to the pathway of a pilose follicle previously destroyed (Pictures 4 and 5). Haemogram, serum determination of phosphorus, calcium, alkaline phosphatase, TSH and cholecalciferol normal, FAN negative. Treated with emollients and topical keratolytics without significant improvement.

DISCUSSION

Atrophic pillar keratosis comprehends three conditions that differ from each other according to the location of the lesions and level of inflammation and atrophy. They are: pillar keratosis face atrophy, atrophodermia vermiculata and keratosis follicularis spinulosa decalvans, possibly belonging to the same pathologic process, characterized by follicular hyperkeratosis with inflammation and subsequent atrophy.^{1,4} Recently other authors have included a fourth type named folliculitis spinulosa decalvans, previously considered a persistent inflammatory variation of keratosis follicularis spinulosa decalvans.⁶

The term keratosis follicularis spinulosa decalvans was created by Siemens,⁷ in 1926, when he described some individuals from a Bavarian family that presented follicular papules on the face, trunk and extremities with partial loss of hairs on these areas and from that moment the disease became known as Siemens syndrome. Genetic studies in Dutch and



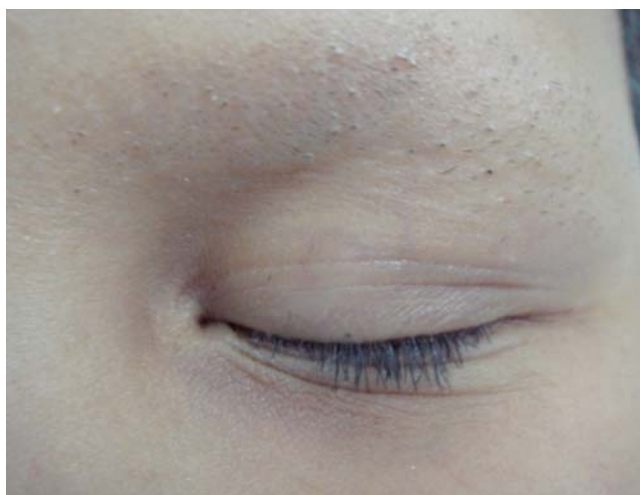PICTURE 2: Keratic follicular papules spread on the scalp

English families showed connection with the Xp21.2-p22 gene.⁸ However, other family analyses without evidence of inheritance linked to X suggest heterogeneous transmissions^{1,3,4,9} and also sporadic⁶ ones.

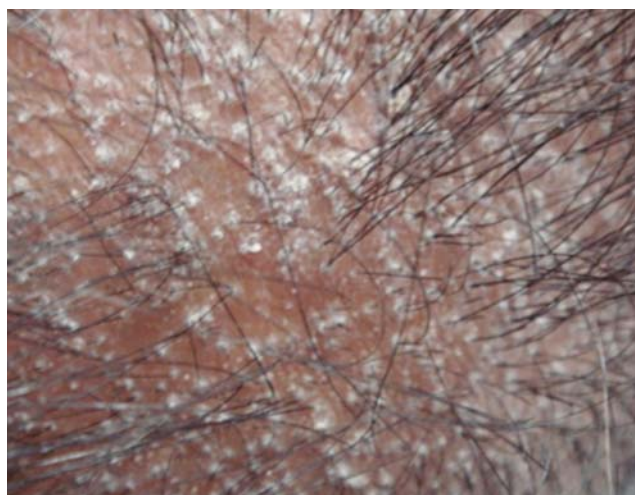This disease starts in the early years of life, initially on the face and progressing towards the trunk and limbs and it might spread to other parts of the body. Palm-plantar hyperkeratosis, photophobia, corneal abnormalities and atopies can be associated.¹ Men are more seriously affected by the disease¹.

The pathophysiology of the destruction of the pilar follicle is not well known yet. The first changes observed are hyperkeratosis and hypergranulosis of the infundibulum and isthmus, which cause inflammatory reaction (at the beginning acute and lately chronic, with mononuclear infiltrate) on the epidermis and on the papillary dermis. Chronic changes are followed by fibrosis and the destruction of the follicle.

However, hyperkeratosis does not seem to be



PICTURE 1: Follicular papules and hipotrichosis in the eyebrows with irregular eyelashes



PICTURE 3: Detail of cicatricial alopecia on the scalp, showing keratosis and adherent squamiae

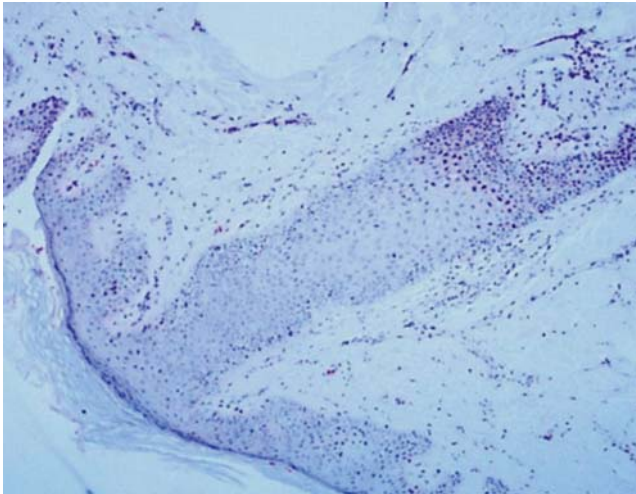


FIGURE 4: Lamellar focal hyperkeratosis corresponding to the ostium follicular region (HE 100x)

the primary event; keratinocyte disorders would precipitate abnormal liberation of cytokine resulting in hyperkeratosis and inflammatory reactions.³

The most important differential diagnoses for keratitis follicularis spinulosa decalvans are: KID syndrome (keratitis, ichthyosis, deafness), atrichia with papular lesions, and inherited mucoepithelial dystrophy.^{5,10}

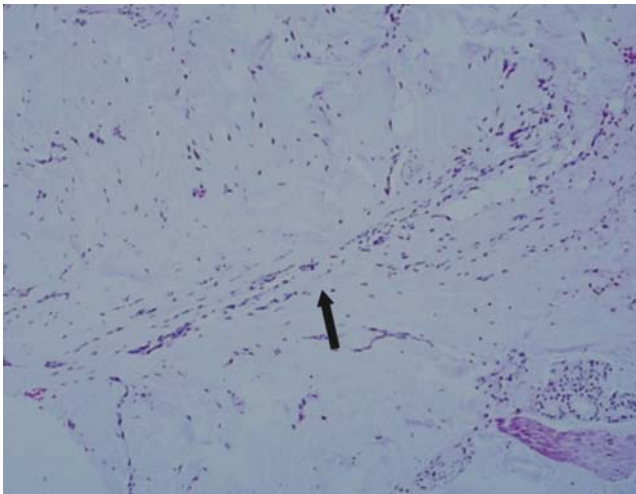


FIGURE 5: Linear vertical scar, corresponding to a pilose follicle previously destroyed (HE 100x)

This specific case refers to a female child, born from consanguineous parents presenting severe cicatricial alopecia that in general occurs in sporadic cases. The child was examined by specialists in genetics but it was not possible to determine if it was due to genetic inheritance or if it was a case of sporadic manifestation.

Keratitis follicularis spinulosa decalvans can present phases of more intense inflammatory activity in childhood, getting better throughout adolescence, which does not impede the slow progression to cicatricial alopecia in a later phase.

The present case calls the attention for its gravity and precocity of changes (at birth) with diffuse cicatricial alopecia on the scalp of a female patient.

The treatment is frustrating, with a few reports of slight improvement in cases at an early stage that present a major inflammatory component. The improvement, in general, refers only to stabilization of the alopecia and clinical improvement of the areas that present erythema and pustulas. Keratolytics, topical and intra lesions corticoids can reduce hyperkeratosis and inflammation, to a certain extent only.

Different systemic treatments including isotretinoin, etretinate, dapsone and antibiotics have been tried with varied results^{5,6,11} It is suggested that the use of retinoids in the early and more active phase of the disease, when histopathology shows perifollicular infiltrate, can bring some benefit.³

Treatment is even more disappointing when the disease predominantly shows cicatricial changes, as in this present study. Treatment in this circumstance is reduced only to the use of topical paliative medication.

Although it is a rare genodermatosis, keratitis follicularis spinulosa decalvans should always be considered in all cases of hyperkeratosis with alopecia as that apart from the genetic counselling needed in some cases, the treatment of such disease should be started the earliest possible (ideally still in the inflammatory phase) so as to retard and minimize the cicatricial sequels. □

REFERENCES

1. Rand R, Baden HP. Keratosis follicularis spinulosa decalvans. Report of two cases and literature review. *Arch Dermatol.* 1983;119:22-6.
2. Lacarrubba F, Dall'Oglio F, Rossi A, Schwartz RA, Micali G. Familial keratosis follicularis spinulosa associated with woolly hair. *Int J Dermatol.* 2007;46:840-3.
3. Baden HP, Byers HR. Clinical findings, cutaneous pathology, and response to therapy in 21 patients with keratosis pilaris atrophicans. *Arch Dermatol.* 1994;130:469-75.
4. Romine KA, Rothschild JG, Hansen RC. Cicatricial alopecia and keratosis pilaris. Keratosis follicularis spinulosa decalvans. *Arch Dermatol.* 1997;133:381-4.
5. Alfadley A, Al Hawsawi K, Hainau B, Al Aboud K. Two brothers with keratosis follicularis spinulosa decalvans. *J Am Acad Dermatol.* 2002;47(Suppl):S275-8.
6. Kunte C, Loeser C, Wolff H. Folliculitis spinulosa decalvans: successful therapy with dapsone. *J Am Acad Dermatol.* 1998;39:891-3.
7. Siemens HW. Keratosis follicularis spinulosa decalvans. *Arch Dermatol Syphilol.* 1926;151:384-7.
8. Oosterwijk JC, Nelen M, van Zandvoort PM, van Osch LD, Oranje AP, Wittebol-Post D, et al. Linkage analysis of keratosis follicularis spinulosa decalvans, and regional assignment to human chromosome Xp21.2-p22.2. *Am J Hum Genet.* 1992;50:801-7.
9. Goh MS, Magee J, Chong AH. Keratosis follicularis spinulosa decalvans and acne keloidalis nuchae. *Australas J Dermatol.* 2005;46:257-60.
10. Janjua SA, Iftikhar N, Pastar Z, Hosler GA. Keratosis follicularis spinulosa decalvans associated with acne keloidalis nuchae and tufted hair folliculitis. *Am J Clin Dermatol.* 2008;9:137-40.
11. Richard G, Harth W. [Keratosis follicularis spinulosa decalvans. Therapy with isotretinoin and etretinate in the inflammatory stage]. *Hautarzt.* 1993;44:529-34.

MAILING ADDRESS / ENDEREÇO PARA CORRESPONDÊNCIA:

*Alceu L. C. V. Berbert
Rua: Gonçalves Dias, 540. B: Tabajaras
38400 288 Uberlândia - MG, Brazil
Phone/fax: +55 34 3210 2012
E-mail: alceuberbertt@yahoo.com.br*

How to cite this article/Como citar este artigo: Berbert ALCV, Mantese SAO, Rocha A, Cherin CP, Couto CM. Keratosis follicularis spinulosa decalvans - A Case report. *An Bras Dermatol.* 2010;85(4):537-40.