

# Bednar tumor (pigmented dermatofibrosarcoma protuberans): a case report\*

## *Tumor de Bednar (dermatofibrossarcoma protuberante pigmentado): relato de um caso\**

Patrícia Motta de Moraes<sup>1</sup>  
Carlos Alberto Chirano<sup>3</sup>

Antônio Pedro Mendes Schettini<sup>2</sup>  
Greicianne Nakamura<sup>4</sup>

**Abstract:** Bednar tumor is a rare skin neoplasm, considered to be a pigmented variant of dermatofibrosarcoma protuberans. Diagnosis is confirmed through histopathologic examination and immunohistochemical evaluation. Bednar tumor is aggressive locally and recurrences are frequent, but metastases are rare. The most appropriate therapeutic procedure is Mohs' micrographic surgery. The case report presents a 35-year-old patient with this rare neoplasm in which the diagnosis was established through histopathologic examination and immunohistochemical study. The importance is emphasized for dermatologists to be attentive for diagnostic suspicion and have available the necessary means to confirm the diagnosis in order to adopt the best procedure.

**Keywords:** Dermatofibrosarcoma/surgery; Dermatofibrosarcoma/diagnosis; Fibrosarcoma/diagnosis; Immunohistochemistry; Skin neoplasms/surgery; Skin neoplasms/surgery/diagnosis

**Resumo:** O tumor de Bednar é uma rara neoplasia da pele, considerada variante pigmentada do dermatofibrossarcoma protuberans. O diagnóstico é confirmado pelo exame histopatológico e estudo imuno-histoquímico. O tumor de Bednar é agressivo localmente, recidivando com frequência, mas raramente ocorrem metástases. O procedimento terapêutico mais adequado é a cirurgia micrográfica de Mohs. Relata-se o caso de uma paciente de 35 anos, portadora dessa rara neoplasia, cujo diagnóstico foi estabelecido por exame histopatológico e estudo imuno-histoquímico. Ressalta-se a importância de o dermatologista estar atento para suspeitar do diagnóstico e dispor dos meios necessários para confirmá-lo, adotando a melhor conduta.

**Palavras-chave:** Dermatofibrossarcoma/cirurgia; Dermatofibrossarcoma/diagnóstico; Fibrosarcoma/diagnóstico; Imuno-histoquímica; Neoplasias cutâneas/cirurgia/diagnóstico

### INTRODUCTION

Bednar tumors are rare; they were described by Bednar in 1957.<sup>1</sup> They are considered to be a pigmented variant of dermatofibrosarcoma protuberans (DFSP), and differ from DFSP by the presence, in the histopathologic exam, of dendritic cells containing melanin, dispersed amidst the fusiform cells characteristic of DFSP. They involve individuals predominantly

in the third and fourth decades of life, however they may also occur in infancy.<sup>2</sup> They have been described in all ethnic groups, but with a predominance in blacks.<sup>3</sup> It is estimated that Bednar tumors make up a proportion of from 1 to 5% of all DFSPs, which in turn, represent 0,1% of skin cancers.<sup>4,5</sup> The clinical picture consists of plaque-like lesions, brownish or erythema-

Received on May 05, 2003.

Approved by the Consultive Council and accepted for publication on November 28, 2003.

\* Work done at Fundação Alfredo da Matta - Manaus (AM), Brazil.

<sup>1</sup> M.D. Dermatologist, Effective Member of the Brazilian Society of Dermatology (SBD), Currently doctor at Fundação Alfredo da Matta - Fuam (AM).

<sup>2</sup> M.D. Dermatologist, Effective Member of SBD and M.Sc. in Tropical Pathology, UFAM (Federal University of Amazon), Doctor at Fuam (AM).

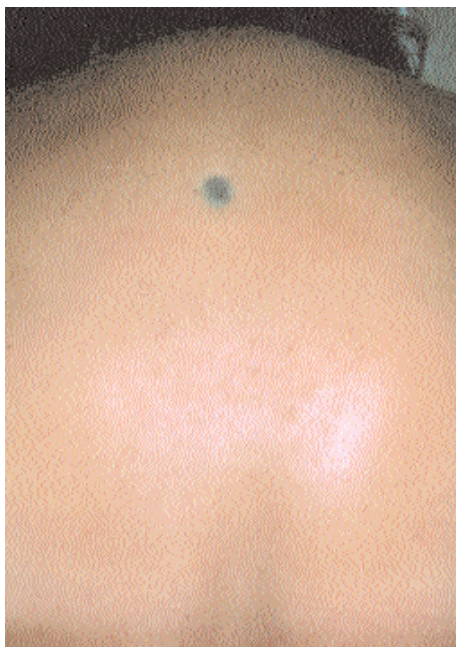<sup>3</sup> M.D. Dermatologist at Fuam (AM).

<sup>4</sup> M.D. Dermatologist, Effective Member of the SBD.

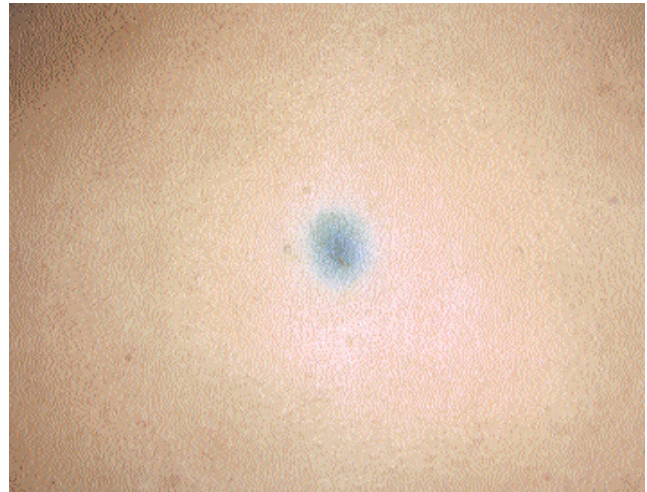tous-bluish, with smooth surface, irregular outlines and firm consistency, adhering to the deep levels.<sup>6,8</sup> Because they are rare, the diagnosis is established by histopathologic exam and immunohistochemical study. The recommended treatment is Mohs' micrographic surgery, but, since it is an aggressive tumor with a potential for metastases, there should be a prolonged period of follow-up as there have been reports of recurrences up to 23 years after removal of the initial lesion.<sup>9</sup>

**CASE REPORT**

The patient was a 35-year-old woman of mixed race and resident in Manaus. She sought the dermatology services of the Fundação Alfredo da Matta (Manaus, AM), complaining of a "tumor in her back" that appeared one year before. The lesion was asymptomatic and she only sought medical attention after advice from her family. At dermatologic exam a lesion was observed in plaque form with very well defined margins, dark-blue coloration; smooth surface and slightly depressed in the central portion, with a diameter of approximately 2 cm, located in the medial-dorsal region (Figures 1 and 2). The patient presented a good general state of health and lymphadenomegaly or visceromegaly were not found by palpation,. Biopsy of the lesion was accomplished by a 4 mm punch for histopathologic and immunohistochemical study. The histopathologic exam revealed neoplasia occupying the dermis and the subcutaneous cellular tissue, composed of fusiform cells with large nuclei, arranged in irregular bundles that were interconnected and, amidst these, fusiform cells containing melan-



**FIGURE 1:** Plaque with bluish coloration and well-defined margins, located in the medial dorsal region



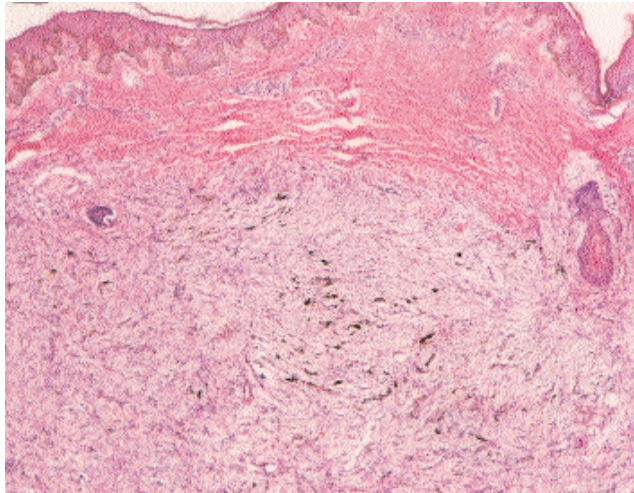
**FIGURE 2:** Detail of the lesion. Superficial smooth plaque, slightly depressed in the central portion

otic pigment (Figures 3 and 4). The panel of antibodies used in the immunohistochemical study by avidin-biotin peroxidase technique (ABC) revealed a positive reaction to CD 34 but was negative to HHF 35, muscular actin, desmins and protein S-100 (Figures 5 and 6). Total surgical exeresis of the lesion was performed with 3 cm wide lateral margins, corresponding to the margins in which the material obtained was histologically free from tumoral cells. The patient has been followed-up for one year.

**DISCUSSION**

Initially designated "*storiform neurofibroma*" by Bednar in 1957, this variant of dermatofibrosarcoma protuberans contains abundant melanotic pigment.<sup>1</sup> The Bednar tumor is rare and, in a series of published cases, corresponds to a proportion that varies from 1 to 5% of all the cases of dermatofibrosarcoma protuberans.<sup>10</sup> Some reports suggest a slight male predominance, others demonstrate an equal distribution between the sexes. It has been described in all ethnic groups, however it is generally more prevalent in blacks.<sup>11</sup> It usually occurs in the third and fourth decades of life, but cases have been described in children and neonates, including the occurrence of a congenital Bednar tumor.<sup>2</sup> Due to its rarity, the evaluation of its local behavior, prognosis, treatment and metastatic potential is based on characteristics of its close relative, dermatofibrosarcoma protuberans. Although the treatment is surgical, with a margin of safety, recurrences may be expected, as well as metastases.

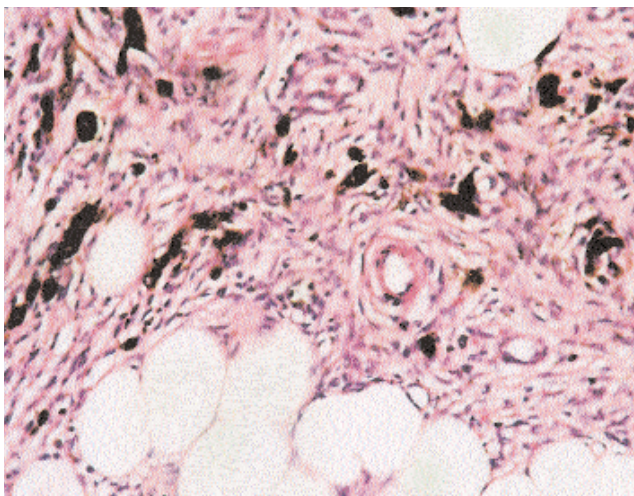
The histogenesis is controversial, it may be related to remnants of embryonic mammary tissue or to various kinds of local traumas, such as previous burns, vaccination scars, insect bites or vaccination (BCG).<sup>12</sup>



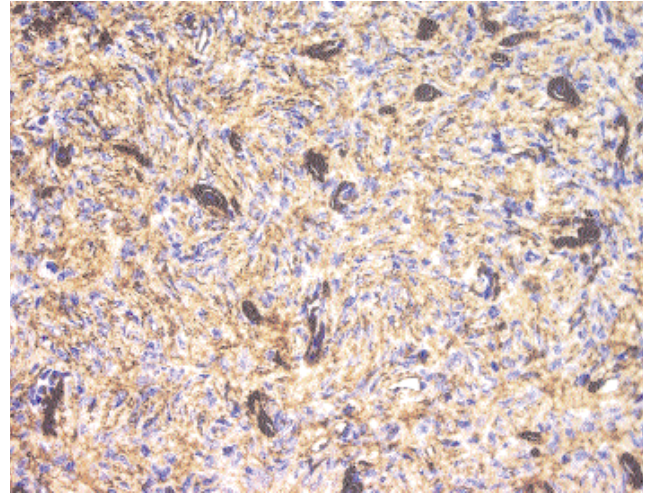
**FIGURE 3:** HE x 10. Neoplasia occupying the dermis and composed of fusiform cells and cells containing melanin pigment

The lesions present a slow growth, over a period of months or years. The most frequent location is in the trunk. Other areas that may be involved are: upper and lower members, or the head and neck.<sup>3</sup> The published cases generally report: plaque lesions of an erythematous-bluish or brownish color, with a smooth or irregular surface. In some cases the lesions are exophytic, nodular, multilobular and of firm consistence. Their invasive growth into the dermis, may reach the subcutaneous strata, fascia and profound musculature, in a manner similar to that of dermatofibrosarcoma protuberans.<sup>6</sup>

Because of its rarity, the Bednar tumor represents a challenge to the dermatologist in terms of its recognition. The clinical aspect is most commonly suggestive of a diagnosis of melanoma or residual inflammatory lesion, therefore histopathologic and



**FIGURE 4:** HE x 40. Detail of the cellular arrangement. Note the abundant melanin pigment in some of the cells dispersed in the dermis and subcutaneous layer



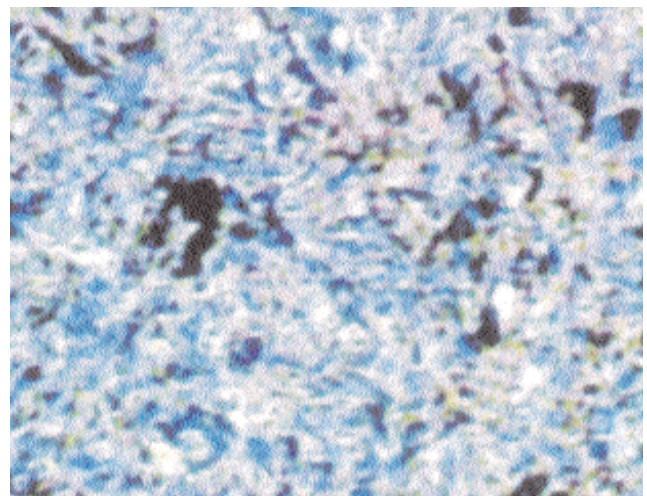
**FIGURE 5:** Immunohistochemical pattern. Reading of the reaction used the avidin-biotin peroxidase technique

immunohistochemical exams are necessary for the correct diagnosis.

Three populations of cells have been identified in Bednar tumors in studies by electron microscopy. Most of the cells are represented by fibroblasts. The second cellular population exhibits elongated, fine elongations, partially or completely enclosed in basal membrane. The third population consists of dendritic cells containing melanosomes and premelanosomes. The histogenesis remains controversial.<sup>13</sup>

In immunohistochemical studies most of the tumor cells exhibit a positive reaction to CD 34 and vimentin, and are negative to neuron-specific enolase, HMB-45 and protein S-100. However, those cells containing melanin may react positively to protein S-100 and vimentin.<sup>13</sup>

A Bednar tumor is aggressive and locally inva-



**FIGURE 6:** Immunohistochemistry. Positivity for antibody against CD 34, which confirmed the diagnosis

sive, with a pronounced tendency to local recurrence. Metastases are rare and late, and dissemination may occur preferentially via hematogenic means but rarely lymphatically. The principal site of metastasis is the lung, however the bones, liver, pancreas, stomach, intestine, thyroid and brain may be involved. In cases of disseminated lesions, a transformation in the fibrosarcomatosis of the tumor may occur.<sup>14,15</sup>

The treatment of choice is Mohs' micrographic surgery, because the principal source of recurrence of the tumor seems to be from cellular groups located deep within the subcutaneous cellular tissue, fascia and muscular bundles, that might not be excised by conventional surgical techniques.

In the case reported here, the correct diagnosis was not reached initially, but determined later by histopathologic and immunohistochemical exams.

Since Mohs' technique is not available routinely in Brazil, it was opted to perform an ample removal of the lesion, with margins of 3 cm that included some of the muscular fascia. Despite the extension of the surgical wound, the esthetic result of the surgical scar was acceptable (Figure 5). An analysis of the specimen demonstrated lateral and deep margins free of neoplasia. The patient has been in ambulatory follow-up for one year.

In conclusion, the need is underscored for the dermatologist to be attentive in recognizing rare neoplasias. In the case of a Bednar tumor, the histopathologic exam complemented by immunohistochemical study is fundamental for diagnosis. The recommended treatment is Mohs' micrographic surgery. Thus, it is necessary to ensure these resources are available in specialized clinics. □

## REFERENCES

1. Bednar B. Storiform neurofibromas of the skin, pigmented and nonpigmented. *Cancer*. 1957; 10:368-76.
2. Marcus JR, Few JW, Senger C, Reynolds M. Dermatofibrosarcoma protuberans and the Bednar tumor: treatment in the pediatric population. *J Pediatr Surg*. 1998; 33:1811-4.
3. Vandeweyer E, Deraemaecker R, Somerhausen ND, Geledan L, Gebhart M. Bednar tumor of the foot: a case report. *Foot Ankle Int*. 2001; 22:339-41.
4. Smola MG, Soyer HP, Scharnagl E. Surgical treatment of dermatofibrosarcoma protuberans. A retrospective study of 20 cases with review of the literature. *Eur J Surg Oncol*. 1991; 17:447-53.
5. Kransdorf MJ. Malignant soft-tissue tumors in a large referral population: distribution of diagnosis by age, sex, and location. *Am J Roentgenol*. 1995; 164:129-34.
6. Elgart GW, Hanly A, Busso M, Spencer JM. Bednar tumor (pigmented dermatofibrosarcoma protuberans) occurring in a site of prior immunization: immunochemical findings and therapy. *J Am Acad Dermatol*. 1999; 40: 315-7.
7. Kobayashi T, Hasegawa Y, Konohana A, Nakamura N. A case of Bednar tumor. Immunohistochemical positivity for CD 34. *Dermatology*. 1997; 195: 57-9.
8. Akasaka T, Ohyama N, Kon S. A case of pigmented dermatofibrosarcoma protuberans (Bednar tumor). *J Dermatol*. 1997; 24: 390-4.
9. Mochizuki Y, Narisawa Y, Kohda H. A case of Bednar tumor recurring after 23 years. *J Dermatol*. 1996; 23: 614-8.
10. Enzinger FM, Weiss SW. Fibrohistiocytic tumors of intermediate malignancy. In Enzinger FM, Weiss SW. *Soft tissue tumors*. St Louis: Mosby; 1995. p. 512-9.
11. Pigmented dermatofibrosarcoma protuberans (Bednar tumor). A pathologic, ultrastructural, and immunohistochemical study. *Am J Surg Pathol*. 1985; 9: 630-9.
12. Pack GT, Tabah EJ. Dermatofibrosarcoma protuberans. *Arch Surg*. 1951; 62:391.
13. Kagoura M, Toyoda M, Nagahori H, Makino T, Morohashi M. An ultrastructural and immunohistochemical study of pigmented dermatofibrosarcoma protuberans (Bednar tumor). *Eur J Dermatol*. 1999; 9: 366-9.
14. Pigmented dermatofibrosarcoma protuberans (Bednar tumor). An autopsy case with systemic metastasis. *Acta Pathol Jpn*. 1990; 40: 935-40.
15. Dupree WB, Langloss JM, Weiss SW. Pigmented dermatofibrosarcoma protuberans (Bednar tumor: a pathologic, ultrastructural, and immunohistochemical study). *Am J Surg Pathol*. 1985; 9:630-9.

### MAILING ADDRESS:

*Patrícia Motta de Morais*

*Rua Rio Jutai, 1139 apto. 704 - Ed. Saint Patrick  
Conjunto Vieiralves - Nossa Senhora das Graças  
69053-020 Manaus AM*

*Tel: (92) 633-1015 / Fax: (92) 663-3155*

*E-mail: pattymmorais@hotmail.com*