

## Becker's nevus syndrome – Case report \*

### Síndrome do nevo de Becker - Relato de caso

Isabela Guimarães Ribeiro Baeta<sup>1</sup>  
Ana Carolina Figueiredo Pereira<sup>3</sup>  
Flávia Vasques Bittencourt<sup>5</sup>

Carla Vilela Viotti<sup>2</sup>  
Sérgio Rodrigues da Costa Júnior<sup>4</sup>

**Abstract:** Becker's nevus is a hyperpigmented macula that is predominantly located on the anterior trunk or on the scapular region, frequently associated with hypertrichosis. The association of Becker's nevus with other cutaneous, musculoskeletal or maxillofacial anomalies has been called Becker's nevus syndrome. We report a case of a 16-year-old girl with a hyperpigmented macula which spread from her right anterolateral trunk to the inner part of her right thigh accompanied by ipsilateral mammary hypoplasia. The skin lesion started when the patient was seven years old when it was also noticed ipsilateral mammary hypoplasia. The histological exam confirmed the clinical hypothesis of Becker's nevus.

**Keywords:** Breast; Breast/abnormalities; Hamartoma; Pigmented nevus; Smooth muscle

**Resumo:** O nevo de Becker se manifesta como uma mácula hiperocrômica, localizada predominantemente no tronco anterior ou região escapular, e frequentemente associada à hipertricose. A coexistência do nevo de Becker e anormalidades cutâneas, músculo-esqueléticas ou maxilo-faciais corresponde à síndrome do nevo de Becker. Relata-se o caso de uma paciente de 16 anos, portadora desde os sete anos de mácula hiperocrômica, localizada no tronco ântero-lateral direito, estendendo-se até a face medial da coxa direita, acompanhada de hipoplasia mamária ipsilateral. O exame anatomopatológico confirmou a hipótese clínica de nevo de Becker.

**Palavras-chave:** Hamartoma; Mama; Mama/anormalidades; Músculo liso; Nevo pigmentado

#### INTRODUCTION

Becker's nevus is a located hyperpigmented macula with well defined and irregular borders, covered most of the times by terminal hairs.<sup>1</sup> It is located predominantly on the anterior trunk or on the scapular region,<sup>1-3</sup> but it can be located in other areas of the body.<sup>4</sup> Although there have been reports of multiple or bilateral cases, the lesion is generally unique and bilateral. Becker's nevus syndrome is associated with other cutaneous anomalies, musculoskeletal or maxillofacial.<sup>3,6</sup> In women the most commonly found anomaly is the ipsilateral mammary hypoplasia.<sup>6</sup>

#### CASE REPORT

A 16 year-old patient, female, without comorbidities, with hyperchromic brownish macula, with well defined limits and irregular borders, geographic outline asymptomatic, located in the right anterolateral trunk, spreading until the right flank and the medial face of the right thigh. (Pictures 1 and 2). The lesion started when the patient was 7 years old, presenting increase proportional to the growth of the child. It was also observed absence of ipsilateral mammary development (Picture 3). As the diagnostic hypothesis of Becker's nevus associated with mammary hypoplasia was considered, it was carried out biopsy of the skin on the dorsum. Morbid anatomy exams confirmed the clinical hypothesis of Becker's nevus. (Pictures 4 and 5).

Received on 10.08.2009.

Approved by the Advisory Board and accepted for publication on 29.01.2010.

\* Work carried out in the Dermatological Service of the Federal University of Minas Gerais (HC-UFGM) – Minas Gerais (MG), Brazil.

Conflict of interest: None / *Conflito de interesse: Nenhum*  
Financial funding: None / *Suporte financeiro: Nenhum*

<sup>1</sup> Resident of the Dermatological service of the University Hospital from the Federal University of Minas Gerais (HC-UFGM) – Minas Gerais (MG), Brazil.

<sup>2</sup> Resident of the Dermatological service of the University Hospital from the Federal University of Minas Gerais (HC-UFGM) – Minas Gerais (MG), Brazil.

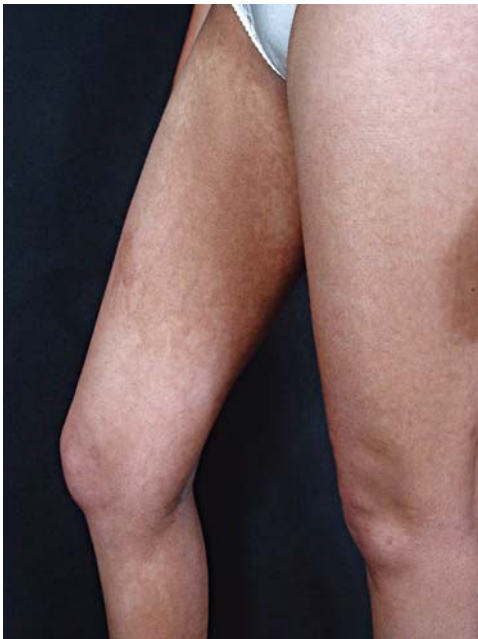<sup>3</sup> Resident of the Dermatological service of the University Hospital from the Federal University of Minas Gerais (HC-UFGM) – Minas Gerais (MG), Brazil.

<sup>4</sup> Resident of the Dermatological service of the University Hospital from the Federal University of Minas Gerais (HC-UFGM) – Minas Gerais (MG), Brazil.

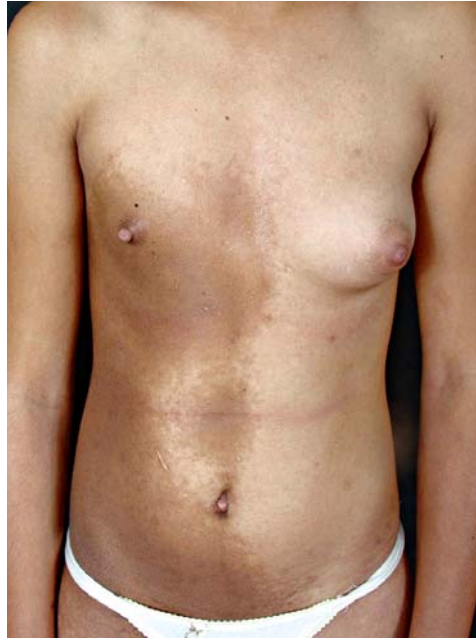<sup>5</sup> Assistant professor of Dermatology of the Faculty of Medicine of the Federal University of Minas Gerais (UFMG). Master and Doctorate degrees from the Federal University of Minas Gerais (UFMG). Fellowship in the University of New York. Coordinator of the Pigmented Lesions Ambulatory Service of the University Hospital of the Federal University of Minas Gerais (HC-UFGM) – Minas Gerais (MG), Brazil.



**FIGURE 1:** Hyperchromic brownish macula, with well defined limits and irregular border, geographic outline, located on the right anterolateral trunk



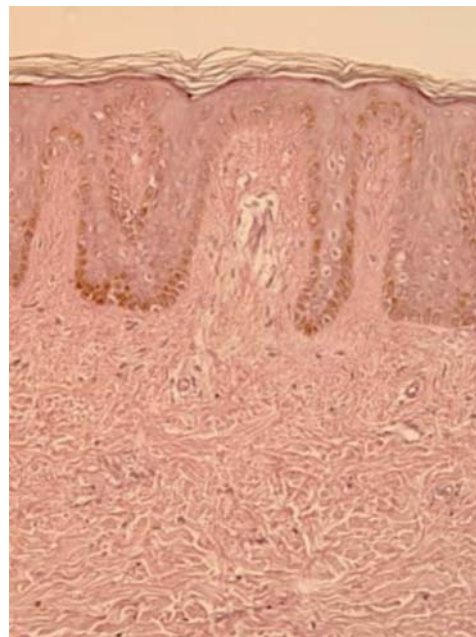
**FIGURE 2:** Expansion of the lesion to the internal region of the right thigh



**FIGURE 3:** Ipsilateral mammary hypoplasia

more discrete is underdiagnosed.<sup>3</sup> On average, lesions occur around eight years of age and become more evident in puberty.

Histology evidences acanthosis, hyperkeratosis, elongation and reticification of epithelial cones and hyperpigmentation of the basal layer. The number of melanocytes is generally normal or slightly increased and there are no nevus cells. The dermis can present a superficial and perivascular lympho-histiocytic infiltrate and melanophages can be seen in the papillary dermis.<sup>5,6</sup> In some cases it is found hyperplasia of smooth muscle fibers arranged in a disorganized way in the reticular dermis,



**FIGURE 4:** Histology compatible with Becker's nevus – HE 200x

## DISCUSSION

In 1949, S. William Becker described two cases of unilateral hyperchromic macula associated with hypertrichosis in young male patients and called it Becker's nevus.<sup>1</sup> Since then various cases have been described in the medical literature including reports of multiple or bilateral cases.<sup>4,5</sup> In 1981, Tymen *et al* estimated a prevalence of 0,5% in young (age varying from 17 to 26 years) male patients.<sup>2</sup> The proportion between the male and female sexes has been already described as 2:1.<sup>4,6</sup> However, Happle and Koopman believe that the prevalence is the same between sexes and suggest that the disease among women as it is

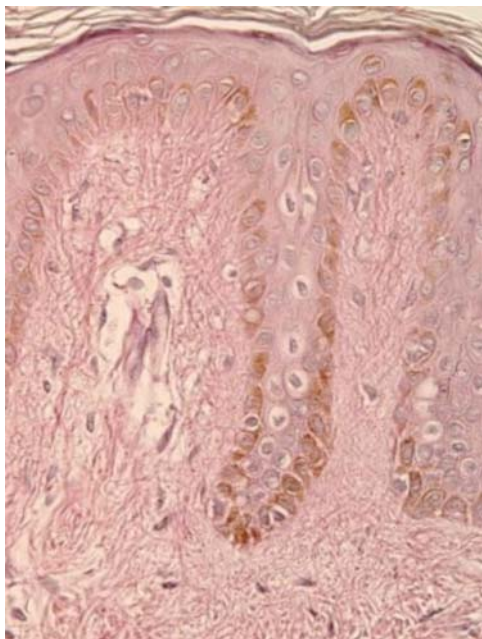


FIGURE 5:  
Elongation of  
epithelial cone  
and hyperpig-  
mentation of  
the basal  
layer.– HE  
400x

corresponding to a hamartoma.<sup>4,7</sup> The majority of the authors attribute an spectral concept to the Becker's nevus and to the smooth muscle hamartoma.<sup>6,9</sup>

The etiopathogenesis is not clear yet. The distribution of the lesions reflects a mosaicism pattern. Although the majority of cases is sporadic it has been reported family occurrence explained as a type of para-dominant inheritance.<sup>4</sup> It is also considered the hypothesis of a hormone-dependent disorder based on the increase of the number of androgen-receptors in the affected areas, that would explain the appearing of lesions in puberty and alterations such as hyper trichosis and acneiform eruptions restricted to the affected regions.<sup>5</sup> The differential diagnosis includes post-inflammatory hyperpigmentation, congenital melanocytic nevus, congenital hamartoma of smooth muscle fibers and spots of white coffee colour.

Becker's nevus syndrome was first described by Happle and Koopman in 1997.<sup>3</sup> It represents the association of Becker's nevus with unilateral mammary hypoplasia or other cutaneous abnormalities, musculoskeletal or maxillofacial. Among

the cutaneous abnormalities we find hyperplasia of the extra-mammary adiposus tissue, supernumerary nipples, hypoplasia of the contralateral labia minora and accessory scrotum. The musculoskeletal abnormalities manifest themselves with scoliosis, *pectus excavatum*, *pectus carinatum* and vertebral dysfunctions and the maxillofacial with facial asymmetry, absence of central incisors and canines.<sup>6</sup> As for women, the most frequently found abnormality is the ipsilateral mammary hypoplasia, which can have its pathogenesis explained by the increase in the number of androgen-receptors in the fibroblasts of the affected areas.<sup>6,10</sup> It can affect only the areola, the nipple or the entire breast and it is not exclusive of the female sex.<sup>6</sup> In the case reported here the patient presented only mammary hypoplasia. Other alterations described in the syndrome were not found.

Becker's nevus is benign with only a few malignant cases reported in the medical literature.<sup>11</sup> The therapeutic indication for the nevus lesion is therefore, essentially cosmetic and up to this moment the most effective treatment has not been well defined yet. The use of laser for depilation and to reduce hyperpigmentation has been described but with limited results. Trelles *et al* demonstrate the superiority of Erbium:YAG when comparing to Neodymium:YAG. The first presented complete clarification of 54% of the patients.<sup>12</sup> Another work using intense pulsated light showed not very satisfactory results, with clarification of less than 25% of the lesions.<sup>13</sup> A recent report of two cases using fractionate laser showed good response, without presenting side effects which turns it into a therapeutic modality to be more studied and to have more research carried on it.<sup>14</sup>

In relation to Becker's nevus syndrome the treatment of the abnormalities should be assessed individually. The use of spironolactone as antiandrogenic therapy has been described in the cases of mammary hypoplasia with satisfactory results.<sup>15</sup> As for female patients the implant of silicone prosthesis can be considered as it happened in the case presented here. □

## REFERENCES

1. Becker SW. Concurrent melanosis and hypertrichosis in distribution of nevus unius lateris. Arch Derm Syphilol. 1949;60:155-60.
2. Tymen R, Forestier JF, Boutet B, Colomb D. Late Becker's nevus: one hundred cases (author's transl). Ann Dermatol Venereol. 1981;108:41-6.
3. Happle R, Koopman RJ. Becker nevus syndrome. Am J Med Genet. 1997;68:357-61.
4. Khatami, A, Seradj MH, Gorouhi F, Firooz A, Dowlati Y. Giant bilateral Becker nevus: a rare presentation. Pediatr Dermatol. 2008;25:47-51.
5. Alfaro A, Torrelo A, Hernandez A, Zambrano A, Happle R. Síndrome del nevo de Becker. Actas Dermosifiliogr. 2007;98:624-6.
6. Danarti R, König A, Salhi A, Bittar M, Happle R. Becker's nevus syndrome revisited. J Am Acad Dermatol. 2004;51:965-9.
7. Darling T, Kamino H, Murray JC. Acquired cutaneous smooth muscle hamartoma. J Am Acad Dermatol. 1993;28:844-5.
8. Civatte J, Marinho E, Santos RO. Hamartoma muscular liso o nevo de Becker? A propósito de cuatro casos. Med Cut ILA. 1988;16:145-8.
9. Ribas CBR, Ribas J, Schettini APM. Hamartoma congênito de músculo liso: relato de caso. An Bras Dermatol. 1997;72:171-4.
10. Grande Sarpa H, Harris R, Hansen CD, Callis Duffin KP, Florell SR, Hadley ML. Androgen receptor expression patterns in Becker's nevi: an immunohistochemical study. J Am Acad Dermatol. 2008;59:834-8.
11. Fehr B, Panizzon RG, Schnyder UW. Becker's naevus and malignant melanoma. Dermatologica. 1991;182:77-80.
12. Trelles MA, Allones I, Moreno-Arias GA, Vélez M. Becker's naevus: a comparative study between erbium:YAG and Q-switched neodymium:YAG; clinical and histopathological findings. Br J Dermatol. 2005;152:308-13.
13. Moreno-Arias GA, Ferrando J. Intense pulsed light for melanocytic lesions. Dermatol Surg. 2001;27:397-400.
14. Glaich AS, Goldberg LH, Dai T, Kunishige JH, Friedman PM. Fractional resurfacing: a new therapeutic modality for Becker's nevus. Arch Dermatol. 2007;143:1488-90.
15. Jung JH, Kim YC, Park HJ, Cinn YW. Becker's nevus with ipsilateral hypoplasia: improvement with spironolactone. J Dermatol. 2003;30:154-6.

## MAILING ADDRESS / ENDEREÇO PARA CORRESPONDÊNCIA:

*Isabela Guimarães Ribeiro Baeta*  
*Avenida Raja Gabaglia 1583/807 Bairro Luxemburgo.*  
*30350-540 Belo Horizonte - MG, Brazil*  
*Mobile: +55 31 - 9345-2006*  
*Work: +55 31 - 3409-9560*  
*Fax-Number: +55 31 - 3409-9199*  
*E-mail: isabelagribeiro@hotmail.com*

How to cite this article/*Como citar este artigo*: Baeta IGR, Viotti CV, Pereira ACF, Costa SR Jr, Bittencourt FV. Becker's nevus syndrome – A Case report. An Bras Dermatol. 2010;85(5):713-6.