

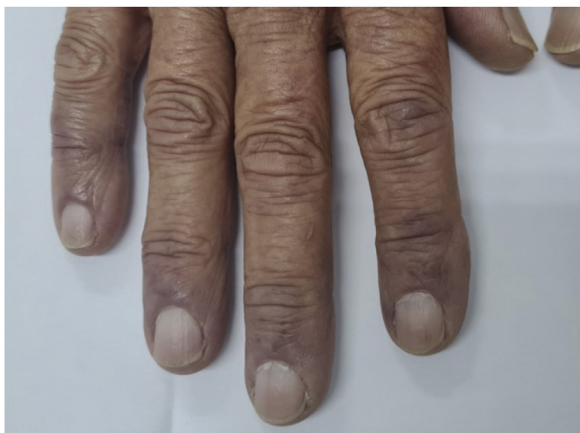

Figure 3 Persistence of acrocyanosis and full resolution of papules.

Financial support

None declared.

Authors' contributions

Lucas Campos Garcia: Approval of the final version of the manuscript; design and planning of the study; drafting and editing of the manuscript; intellectual participation in the propaedeutic and/or therapeutic conduct of the studied cases; critical review of the literature; critical review of the manuscript.

Vanessa Martins Barcelos: Drafting and editing of the manuscript; critical review of the literature; critical review of the manuscript.

Myrciara Macedo de Alcântara: Drafting and editing of the manuscript; critical review of the literature; critical review of the manuscript.

Priscila Jordana Costa Valadares: Drafting and editing of the manuscript; critical review of the literature; critical review of the manuscript.

Conflicts of interest

None declared.

References

1. Le Cleach L. Dermatology and COVID-19: much knowledge to date but still a lot to discover. *Ann Dermatol Venereol.* 2021;148:69–70.
2. McMahon DE, Amerson E, Rosenbach M. Cutaneous reactions reported after Moderna and Pfizer COVID-19 vaccination: a registry-based study of 414 cases. *J Am Acad Dermatol.* 2021;85:46–55.
3. Cappel JA, Wetter DA. Clinical characteristics, etiologic associations, laboratory findings, treatment, and proposal of diagnostic criteria of pernio (chilblains) in a series of 104 patients at Mayo Clinic, 2000 to 2011. *Mayo Clin Proc.* 2014;89:207–15.
4. Temiz SA, Abdelmaksoud A, Dursun R, Vestita M. Acral chilblain-like lesions following inactivated SARS-CoV-2 vaccination. *Int J Dermatol.* 2021;60:1152–3.
5. Aschoff R, Zimmermann N, Beissert S, Günther C. Type I interferon signature in chilblain-like lesions associated with the COVID-19 pandemic. *Dermatopathology (Basel).* 2020;7:57–63.

Lucas Campos Garcia ^a, Vanessa Martins Barcelos ^{a,*}, Myrciara Macedo de Alcântara ^b, Priscila Jordana Costa Valadares ^a

^a *Department of Dermatology, Hospital das Clínicas, Universidade Federal de Minas Gerais, Belo Horizonte, MG, Brazil*

^b *Dermatology Private Practice, Curitiba, PR, Brazil*

* Corresponding author.

E-mail: barcelosmvanessa@gmail.com (V.M. Barcelos).

Received 4 October 2021; accepted 12 January 2022;
Available online 30 March 2023

<https://doi.org/10.1016/j.abd.2022.01.015>

0365-0596/ © 2023 Sociedade Brasileira de Dermatologia.

Published by Elsevier España, S.L.U. This is an open access article under the CC BY license (<http://creativecommons.org/licenses/by/4.0/>).

Radiation recall dermatitis induced by ibuprofen[☆]



Dear Editor,

A 31-year-old female presented with a 1-week history of burning, painful and pruritic skin eruptions affecting the left chest and axillary region. She had previously undergone a modified radical mastectomy and lymph node dissection for ductal breast carcinoma 1 year ago. Then, the patient has prescribed 24 weeks of chemotherapy with doxorubicin, cyclophosphamide, and paclitaxel. Two months ago, she

was treated with 3-dimensional conformal radiation therapy (50 Gy: 25 fractions for five weeks). Mild erythema and scales with pruritus were observed at the end of radiotherapy and subsided with 0.05% desonide cream within several days. Six days before the eruptions appeared, she had taken ibuprofen orally for arthralgia. The inflammatory eruptions involved the areas previously treated with radiation and initially manifested well-demarcated rectangular erythema, edema, and tiny papules, followed by blisters and erosions (Fig. 1). The dermoscopy showed multiple brown circles along with the hair follicles as well as scales (Fig. 2). The histopathology revealed intraepidermal vesiculation, papillary dermal edema, and perivascular inflammatory infiltrate in the upper dermis (Fig. 3).

A diagnosis of radiation recall dermatitis (RRD) induced by ibuprofen was made. The patient was relieved after 1

[☆] Study conducted at the Chengdu Second People's Hospital, Chengdu, Sichuan, China.

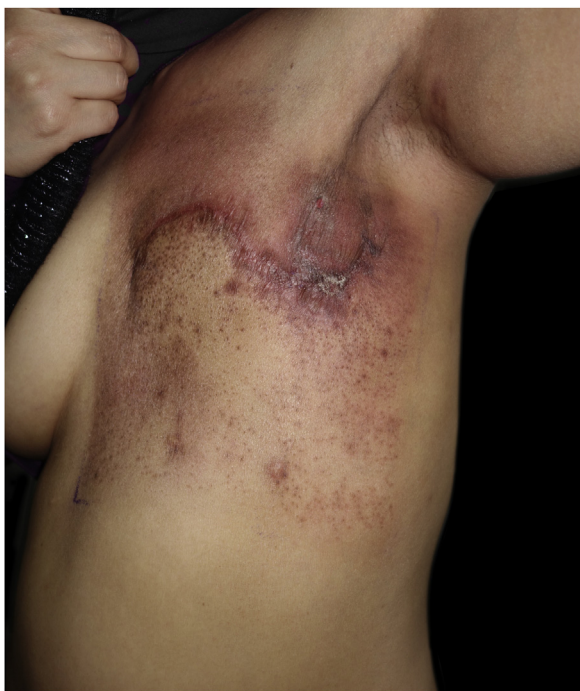

Figure 1 Well-demarcated rectangular erythema with edema, tiny papules, and erosions affecting the left chest and axillary region.

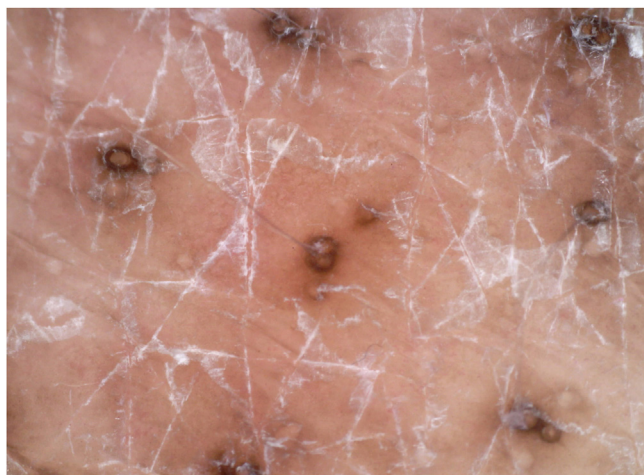

Figure 2 The dermoscopy showed multiple brown circles along with the hair follicles as well as white scales.

week of treatment with oral loratadine and topical 0.05% halometasone cream.

RRD is an uncommon acute dermatitis at regions of the previous radiotherapy in response to drug administration. The most commonly implicated medications are anticancer drugs, in particular cytotoxics, but other drugs can also induce RRD, including antibiotics, antituberculosis drugs, nimesulide, phentermine, and simvastatin.¹ Chu et al. reported only one case of RRD following topical agents.² RRD can occur at any time between days to years after radiation exposure. The time to develop the reaction may be longer for oral than intravenously administered drugs.³ RRD is drug-specific for any individual; it is impossible to predict which individuals will react to which drugs, and

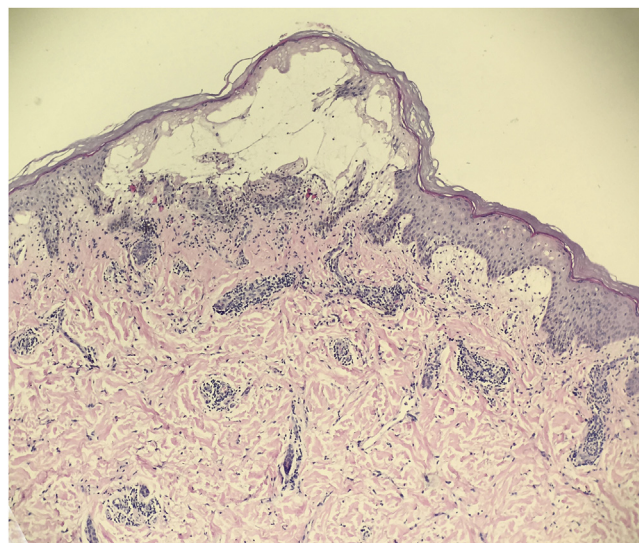


Figure 3 The histopathology revealed intraepidermal vesiculation, papillary dermal edema, and perivascular inflammatory infiltrate in the upper dermis (Hematoxylin & eosin, $\times 100$).

rechallenge does not uniformly cause a reaction.¹ Several possible explanations for the pathogenesis of RRD have been proposed including memory reaction of surviving epithelial stem cells, radiation-induced mutation, post-radiation vascular damage, and hypersensitivity reaction.³

Most of the time, RRD presents as erythema, papules, edema, vesicles, desquamation, or even ulceration.⁴ The area affected by RRD corresponds to the site previously irradiated, although may occasionally become generalized. The histological appearance is nonspecific and sometimes overlaps with acute radiation dermatitis. It is important to note however, radiation recall reactions may involve deep tissues and organs.¹

To our knowledge, there have been no reports of RRD induced by ibuprofen. This is the second case of RRD following a non-steroidal anti-inflammatory drug, and the first was induced by nimesulide.⁵ The dermoscopic manifestation shows a brown circle around the hair follicle that is similar to the dermoscopic appearance of lichen pilaris.

Financial support

None declared.

Authors' contributions

Li-wen Zhang and Juan Wu contributed equally to this work.

Li-wen Zhang: Study conception and planning; preparation and writing of the manuscript.

Juan Wu: Literature review.

Lu Zheng: Acquisition of data.





Tao Chen: Approval of the final version of the manuscript.

Conflicts of interest

None declared.

References

1. Burris HA, Hurtig J. Radiation recall with anticancer agents. *Oncologist*. 2010;15:1227–37.
2. Chu CH, Cheng YP, Liang CW, Chiu HC, Jee SH, Chan JYL, et al. Radiation recall dermatitis induced by topical tacrolimus for post-irradiation morphea. *J Eur Acad Dermatol Venereol*. 2017;31:e80–1.
3. Camidge R, Price A. Characterizing the phenomenon of radiation recall dermatitis. *Radiother Oncol*. 2001;59:237–45.
4. Guarneri C, Guarneri B. Radiation recall dermatitis. *CMAJ*. 2010;182:E150.
5. Ng AWY, Wong FCS, Tung SY, S K O. Nimesulide – a new trigger of radiation recall reaction. *Clin Oncol (R Coll Radiol)*. 2007;19:364–5.

Li-wen Zhang ^a, Juan Wu ^b, Lu Zheng ^a,
Tao Chen ^{a,*}

^a Department of Dermatovenereology, Chengdu Second People's Hospital, Chengdu, Sichuan, China

^b Sexually Transmitted Disease Institute, Shanghai Skin Disease Hospital, School of Medicine, Tongji University, Shanghai, China

* Corresponding author.

E-mail: 13980427003@163.com (T. Chen).

Received 29 July 2021; accepted 22 August 2021;
Available online 24 March 2023

<https://doi.org/10.1016/j.abd.2021.08.017>

0365-0596/ © 2023 Published by Elsevier España, S.L.U. on behalf of Sociedade Brasileira de Dermatologia. This is an open access article under the CC BY license (<http://creativecommons.org/licenses/by/4.0/>).

Synchronous and metachronous melanomas diagnosed at early stages in a patient with dysplastic nevus syndrome[☆]



Dear Editor,

A 34-year-old male patient, phototype II, according to the Fitzpatrick classification, with clinically dysplastic multiple nevi, was surgically treated in 2019 for a superficial spreading cutaneous melanoma with 0.45mm Breslow's thickness, on the lumbar region. He had no family history of melanoma and was referred for photo-dermoscopy/total body mapping (TBM) with the inclusion of all pigmented lesions. For that purpose, macroscopic photos of the patient's skin surface were taken in standard positions. A Canon EOS T7i[®] camera with EF 50 mm lens (f/1.4 USM aperture) was used to obtain the photos. The camera was attached to the set of hardware that constitutes the Fotofinder Dermoscope 1000[®]. The images were generated using Medicam full HD 1000[®], with non-polarized light, and aqueous gel was used on the interface between the skin and the lens. Afterwards, all lesions were analyzed considering the qualitative method of "pattern analysis".

A total of 645 melanocytic lesions were documented. Of these, nine showed dermoscopic findings with indication for additional histopathology. Suspicious melanocytic lesions were submitted to excision and three new melanomas were diagnosed: 1) A superficial spreading melanoma, with 0.5mm Breslow's thickness, on the right hypochondrium region (Fig. 1); *in situ* melanoma on the left flank (Fig. 2) and an *in situ* melanoma on the left leg (Fig. 3). The other six lesions were diagnosed as dysplastic nevi (marked dysplasia).

On histopathology, the atypical nevi showed components of junctional and dermal melanocytic cells (compound nevi) with architectural disarray and asymmetry, in addition to cytological atypia and subepidermal fibroplasia. In the

lesions diagnosed as *in situ* melanoma (flank and left leg), in addition to more intense cytological atypia, significant pagetoid dissemination was observed; however, without dermal invasion. The superficial spreading melanoma (abdominal region) showed intense cytological atypia, characterized by pleomorphism and nuclear hyperchromasia, exuberant pagetoid dissemination, and dermal invasion foci with atypical mitotic figures. Immunohistochemistry showed HMB45

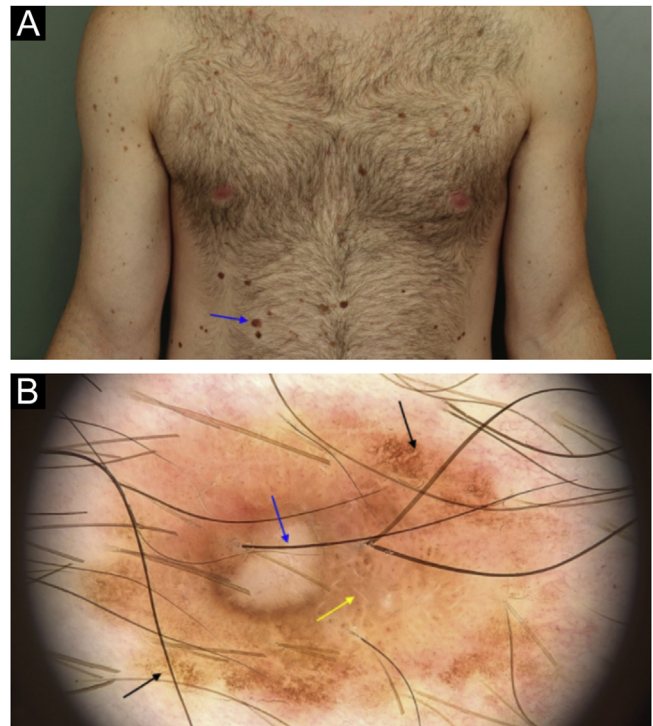


Figure 1 A superficial spreading melanoma, with 0.5mm Breslow's thickness on the right hypochondrium region: (a) Clinical appearance and location of the lesion (arrow). (b) Dermoscopy showing areas of atypical pigmented network (black arrow), area with reticulated hypopigmentation (yellow arrow); and depigmented/amorphous central area with intermingled linear and irregular vessels (blue arrow).

[☆] Study conducted at the Medical Course, Universidade Federal da Fronteira Sul, Chapecó, SC, Brazil.