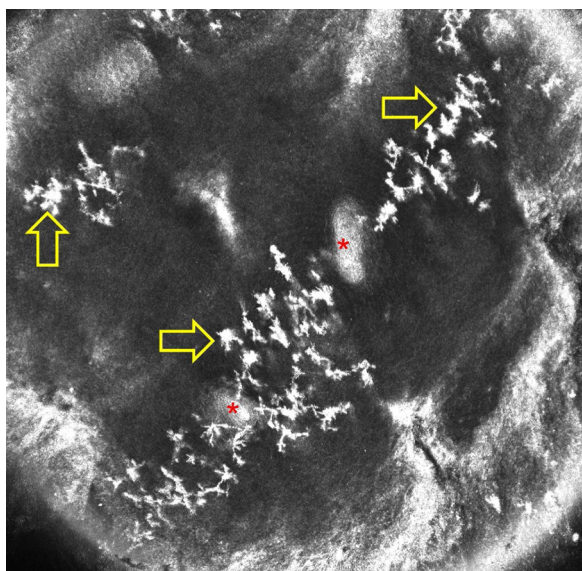

**Figure 2** Reflectance confocal microscopy image of normal acral skin of a healthy person shows artifacts presenting as stellate hyper-reflective bodies in the epidermis (yellow arrows; asterisks indicate acrosyringia).

and writing of the manuscript; critical revision of the manuscript.

Jean Luc Perrot: Approval of the final version of the manuscript; study design and planning; data collection, analysis and interpretation; effective participation in research orientation; intellectual participation in propaedeutic and/or therapeutic conduct of studied cases; critical literature review; critical revision of the manuscript.

Pietro Rubegni: Approval of the final version of the manuscript; effective participation in research orientation; intellectual participation in propaedeutic and/or therapeutic conduct of studied cases; critical revision of the manuscript.

## Conflicts of interest

None declared.

## References

1. Veasey JV, Avila RBde, Ferreira MAMdeO, Lazzarini R. Reflectance confocal microscopy of tinea nigra: comparing images with dermoscopy and mycological examination results. *An Bras Dermatol*. 2017;92:568–9.
2. Cinotti E, Perrot JL, Labeille B, Cambazard F. Reflectance confocal microscopy for cutaneous infections and infestations. *J Eur Acad Dermatol Venereol*. 2016;30:754–63.
3. Cinotti E, Labeille B, Cambazard F, Perrot JL. Reflectance confocal microscopy in infectious diseases. *G Ital Dermatol E Venereol*. 2015;150:575–83.
4. Uva L, Leal-Filipe P, Soares-de-Almeida L, Ferreira J, Oliveira A. Reflectance confocal microscopy for the diagnosis of tinea nigra. *Clin Exp Dermatol*. 2018;43:332–4.
5. Cinotti E, Perrot JL. Topographic and skin phototype variations of skin with special emphasis on facial and acral skin. In: Gonzalez S, editor. *Reflectance confocal microscopy of cutaneous tumors*. India: CRC Press; 2017. p. 120.

Elisa Cinotti <sup>a,\*</sup>, Jean Luc Perrot <sup>b</sup>, Pietro Rubegni <sup>a</sup>

<sup>a</sup> Department of Medical, Surgical and Neurological Science, Dermatology Section, University of Siena, S. Maria alle Scotte Hospital, Siena, Italy

<sup>b</sup> Department of Dermatology, University Hospital of Saint-Etienne, Saint-Etienne, France

\* Corresponding author.

E-mail: [elisacinotti@gmail.com](mailto:elisacinotti@gmail.com) (E. Cinotti).

Received 28 January 2019; accepted 24 April 2019

<https://doi.org/10.1016/j.abd.2019.04.013>

0365-0596/ © 2019 Sociedade Brasileira de Dermatologia.

Published by Elsevier España, S.L.U. This is an open access article under the CC BY license (<http://creativecommons.org/licenses/by/4.0/>).

## Beware of reflectance confocal microscopy artifacts when searching hyphae in acral skin – Reply<sup>☆☆</sup>

Dear Editor,

I would like to thank Cinotti et al. for their interest in our paper about tinea nigra's findings at confocal microscopy, as well as the opportunity offered by the editors of this journal



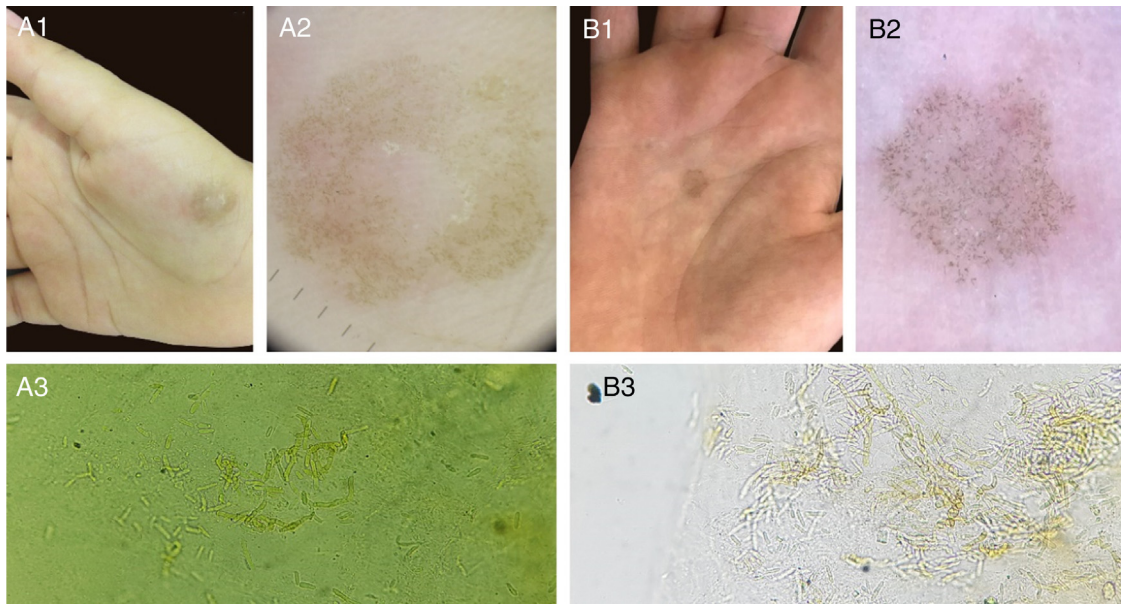
to answer the points raised by the authors in the article “Beware of reflectance confocal microscopy artifacts when searching hyphae in acral skin”.

The etiological agent of tinea nigra, *Hortaea werneckii*, is a dematiaceous geophilic fungus. The dermoscopic features of this disease consist of a fibrillar hyperchromic pattern, and the direct mycological examination (DME) presents short and thick dematiaceous hyphae, corresponding to the described dermoscopic findings.<sup>1,2</sup> Other cases seen in our service with fungal culture isolating *H. werneckii* are compatible with these findings (Fig. 1).

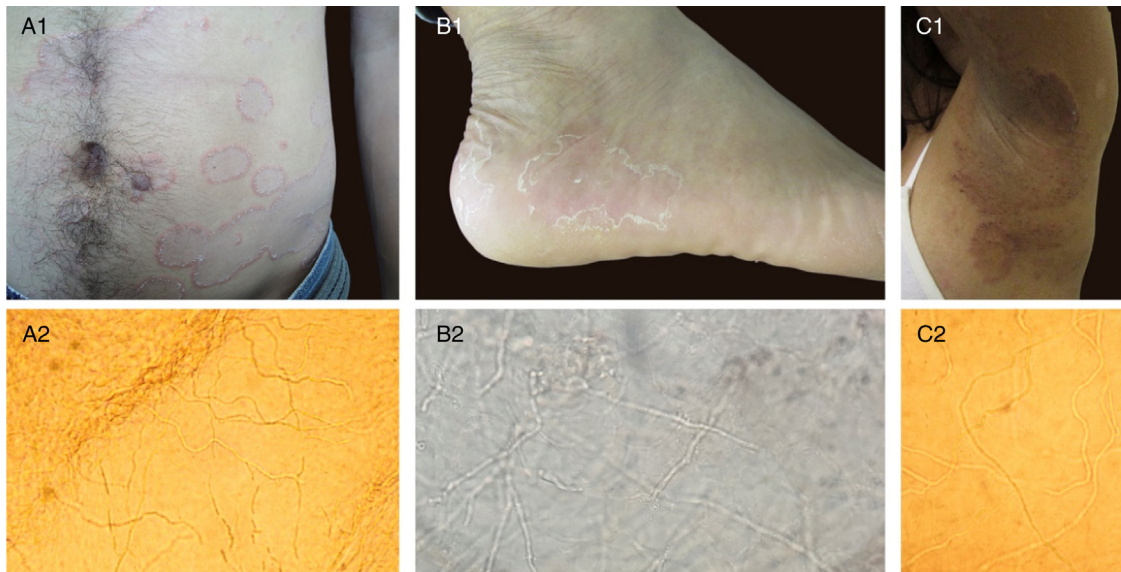
Such facts had led us to believe that the images identified by reflectance confocal microscopy (RCM) in our article would be compatible with the hyphae of *H. werneckii* parasitizing the epidermis. It is noteworthy that the morphology of short thick structures presented at dermoscopic examination and DME were compatible with those evidenced by the RCM.<sup>3</sup>

<sup>☆</sup> How to cite this article: Veasey JV. Beware of reflectance confocal microscopy artifacts when searching hyphae in acral skin – Reply. *An Bras Dermatol*. 2020;95:130–2.

<sup>☆☆</sup> Study conducted at the Dermatology Clinic, Hospital da Santa Casa de Misericórdia de São Paulo, São Paulo, SP, Brazil.



**Figure 1** Two cases of tinea nigra with classic clinical presentation (A1, B1). Dermoscopy of both cases, with short hyperchromic linear structures in the epidermis (A2, B2). Direct mycological examination (KOH 20%), with short dematiaceous septate hyphae (A3 x200, B3 x400).



**Figure 2** A1, B1, C1: clinical aspect of superficial mycoses. A2, B2, C2: direct mycological examinations (KOH 20%) corresponding to clinical presentations, presenting in all cases thin and long hyaline septated hyphae (x100, x400, x200, respectively).

As for the images presented in the response correspondence, composed of few thin and elongated septate hyphae at the surface of the epidermis, I would like to point out that in human microbiome studies there are evidence of filamentous fungi in the skin of healthy patients.<sup>4,5</sup> Such agents, when provoking superficial mycoses, present at the DME fine and long hyphae (Fig. 2), a morphology that has also been described in RCM analyzes.<sup>6-9</sup> An important fact in Cinotti et al. article was the lack of fungal culture of the specimen evidenced by RCM images, making it impossible to confirm that the hyphae visualized were of *H. werneckii*. I believe that these facts should be taken into account when finding

thin and long hyphae in the analysis of tinea nigra images, since the other tests performed for its diagnosis usually do not present these thin structures. Unfortunately, it is not possible to evaluate by the RCM if the hyphae presented in the cases are hyaline or dematiaceous, since both melanin and the cellular wall of the fungi present white color by the RCM examination.

Finally, it cannot be denied that the use of RCM for the analysis of tinea nigra presents various pitfalls, either due to the presence of filamentous fungal structures that could erroneously be considered compatible with *H. werneckii*, or to the presence of epidermal artifacts that could be con-

sidered as fungal structures. Further studies are required to help us elucidate the structures of this dermatosis.

### Financial support

None declared.

### Author's contribution

John Verrinder Veasey: Approval of the final version of the manuscript; elaboration and writing of the manuscript; collection, analysis, and interpretation of data; intellectual participation in the propaedeutic and/or therapeutic conduct of the studied cases; critical review of the literature; critical review of the manuscript.

### Conflicts of interest

None declared.

### References

1. Delgado L, Criado PR, Alonso G. Dermoscopy revealing a case of Tinea Nigra. *An Bras Dermatol*. 2013;88:128–9.
2. Veasey JV, Avila RB, Miguel BAF, Muramatu LH. White piedra, black piedra, tinea versicolor and tinea nigra: contribution to the diagnosis of superficial mycosis. *An Bras Dermatol*. 2017;92:413–6.
3. Veasey JV, Avila RB, Ferreira MAMO, Lazzarini R. Reflectance confocal microscopy of tinea nigra: comparing images with dermoscopy and mycological examination results. *An Bras Dermatol*. 2017;92:568–9.
4. Jo JH, Deming C, Kennedy EA, Conlan S, Polley EC, Ng WI, et al. Diverse human skin fungal communities in children converge in adulthood. *J Invest Dermatol*. 2016;136:2356–63.
5. Zaror L, Aliaga X. Dermatophytes in healthy Chilians. *Mycoses*. 1990;33:95–8.
6. Friedman D, Friedman PC, Gill M. Reflectance confocal microscopy: an effective diagnostic tool for dermatophytic infections. *Cutis*. 2015;95:93–7.
7. Liansheng Z, Xin J, Cheng Q, Zhiping W, Yanqun L. Diagnostic applicability of confocal laser scanning microscopy in tinea corporis. *Int J Dermatol*. 2013;52:1281–2.
8. Veasey JV, Meneses OMS, da Silva FO. Reflectance confocal microscopy of tinea capitis: comparing images with results of dermoscopy and mycological exams. *Int J Dermatol*. 2018;58:849–51.
9. Cinotti E, Perrot JL, Labeille B, Cambazard F. Reflectance confocal microscopy for cutaneous infections and infestations. *J Eur Acad Dermatol Venereol*. 2016;30:754–63.

John Verrinder Veasey 

*Infectious Dermatoses Sector, Clínica de Dermatologia, Santa Casa de Misericórdia de São Paulo, São Paulo, SP, Brazil*

*E-mail: johnveasey@uol.com.br*

Received 10 March 2019; accepted 29 April 2019

<https://doi.org/10.1016/j.abd.2019.04.014>

0365-0596/ © 2019 Sociedade Brasileira de Dermatologia.

Published by Elsevier España, S.L.U. This is an open access article under the CC BY license (<http://creativecommons.org/licenses/by/4.0/>).