

Verrucous hemangioma*

*Hemangioma verrucoso**

Emmanuel Rodrigues de França¹
Juliana de A. Souza⁴

Aldejane Gurgel²
Kelly França⁵

Trícia Campos³
Renata Azevedo⁶

Abstract: Verrucous Hemangioma is an uncommon vascular malformation, characterized by vascular proliferation and dilation from dermis to subcutaneous tissue, and proliferative reaction of the epidermis. The authors report a case of verrucous hemangioma, making a brief review of its clinical, histopathological and therapeutic aspects.

Keywords: Arteriovenous malformation; Hemangioma; Therapeutics

Resumo: O hemangioma verrucoso é malformação vascular, incomum, caracterizada por dilatação e proliferação vascular na derme e no subcutâneo com alterações reativas da epiderme. Os autores relatam um caso de hemangioma verrucoso fazendo breve revisão de seus aspectos clínicos, histopatológicos e terapêuticos.

Palavras-chave: Hemangioma; Malformações arteriovenosas; Terapêutica

INTRODUCTION

Verrucous hemangioma is an uncommon vascular malformation, sometimes clinically mistaken for circumscribed angiokeratoma. Its usual onset is at birth or beginning of childhood, as a plane lesion, which tends to grow proportionally to body development throughout the following years.^{1,2-10} It characteristically presents as vascular papules, plaques or nodules of bluish color, with verrucous surface and linear disposition, unilateral and are usually located in the lower limbs.³ Histologically, it displays increased vascularization from dermis to subcutaneous tissue, and relapse is common after conventional treatment with criotherapy or electrocoagulation.³

The authors report a case of verrucous hemangioma affecting the forearm, an unusual location.

CASE REPORT

Twenty-three-year-old brown-skinned female patient, born in and coming from Santa Maria da Boa Vista, PE, who reported asymptomatic lesions with onset 10 years before, located in the right forearm, and with progressive growth. She denied previous treatments. Upon dermatological examination, she presented erythematic-violet tumoral lesions, with verrucous surface, arcuate arrangement and atrophic scar center, disposed linearly along the extensor surface of right hand and forearm (Figures 1, 2 and 3). Anatomopathological examination (Figures 4 and 5) of a lesion fragment revealed marked hyperkeratosis, irregular acanthosis, papillomatosis and vascular proliferation in the superficial dermis extending deep in the subcutaneous tissue. Based on these histological findings, the diagnosis of verrucous hemangioma was established, and the patient was referred for deep exeresis of the lesion.

Received on November 22, 2002.

Approved by the Consultive Council and accepted for publication on July 28, 2006.

* Work done at Dermatology Department from the Faculdade de Ciências Médicas de Pernambuco, Universidade de Pernambuco (UPE) – Recife (PE), Brazil.

Conflict of interests: None

¹ PhD and Associate Professor of Dermatology. Head of the Department from the Faculdade de Ciências Médicas de Pernambuco, Universidade de Pernambuco (UPE) – Recife (PE), Brazil.

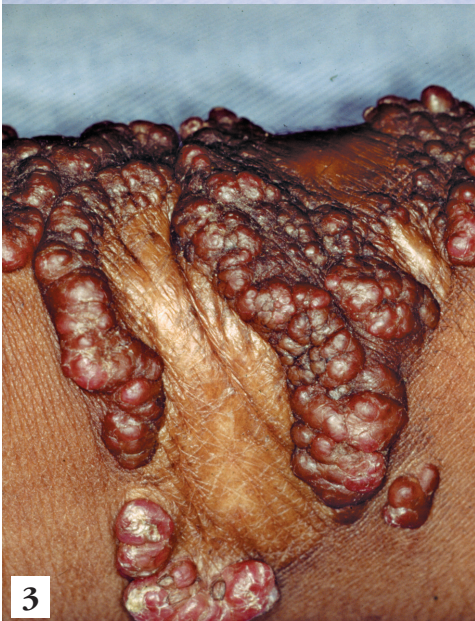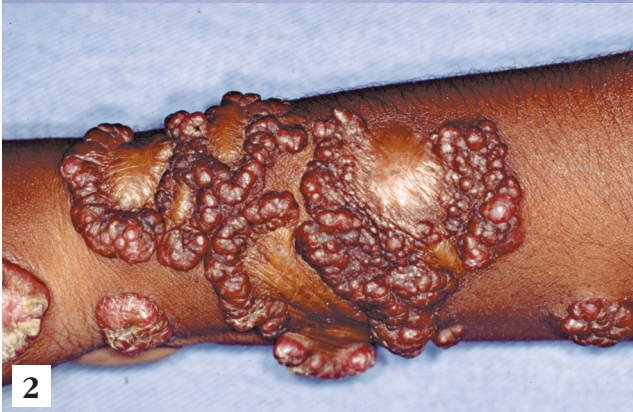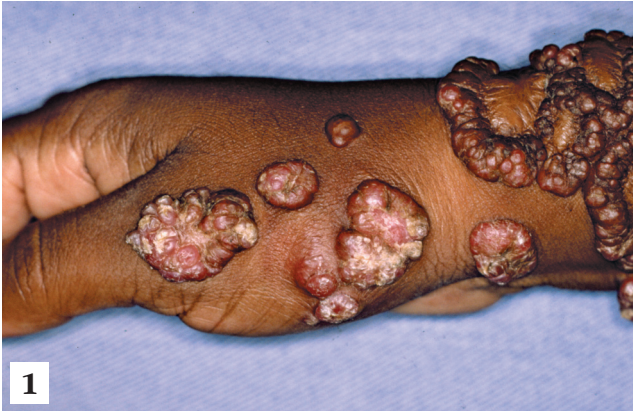² Dermatologist.

³ Dermatologist.

⁴ Dermatologist.

⁵ Dermatologist.

⁶ Dermatologist.



FIGURES 1, 2 e 3: Erythematic-violet lesions with verrucous surface, located in right hand and forearm

DISCUSSION

Verrucous hemangioma is an uncommon condition, which has been described in the literature under various names, including unilateral neviform hemangioma, unilateral verrucous hemangioma, unilateral vascular nevus and angiokeratotic nevus.⁴

The lesion appears as well-circumscribed erythematic-bluish maculas, which increase in size with

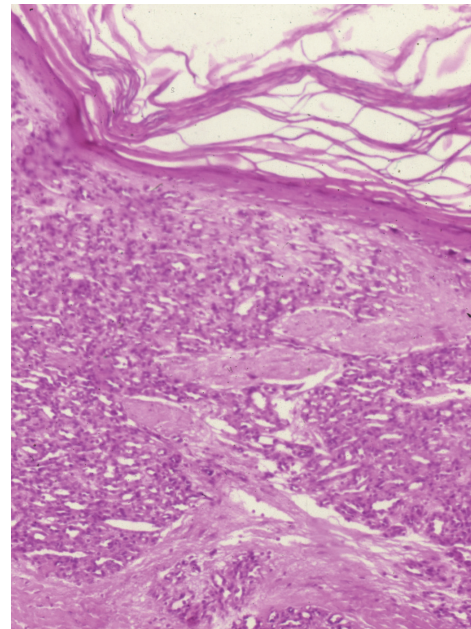


FIGURE 4: Epidermis displaying papillomatosis, acanthosis and hyperkeratosis in varied degrees

time, acquiring an erythematic-violet color, and its surface becoming verrucous and hyperkeratotic.¹ Such verrucous hyperkeratotic aspect of the lesion is considered to be a reaction to injuries, such as trauma or infection.^{5,6,9}

Unlike the present patient, who presented lesions in the forearm, in around 95% of cases, verrucous hemangioma is located in the lower extremities.⁴ Histopathologically, it is characterized by the presence of angiomatous proliferation with dilated vessels extending down to reticular dermis and subcutaneous tissue (Figure 5).^{6,7} Epidermis displays papillomatosis, acanthosis and hyperkeratosis in varied degrees, and atrophy may be found in some areas (Figure 4).^{2,8-10} Hematic or meliceric crusts may be

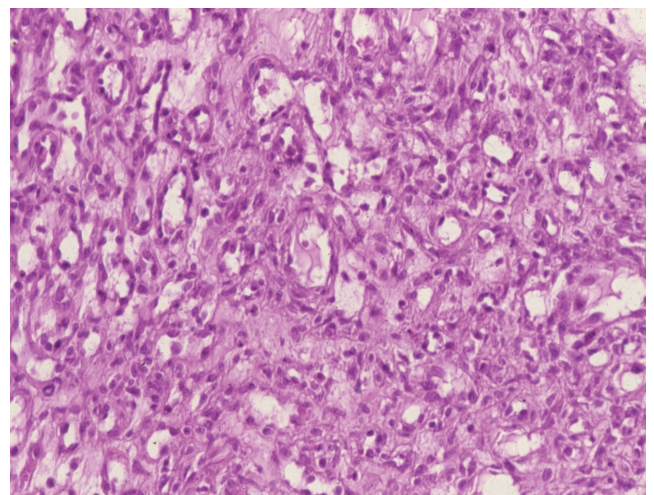


FIGURE 5: Angiomatous proliferation extending to reticular dermis and subcutaneous tissue

found in the horny layer, indicating previous trauma or secondary infection,⁴ as fibrosis and elastic fiber fragmentation, occasionally observed in the dermis, may also indicate.¹⁰

An important differential diagnosis of verrucous hemangioma is circumscribed angiokeratoma, essentially a vascular ectasis that is usually observed in the lower limbs, more commonly in women. Despite the clinical and histological similarities, the latter can be distinguished from verrucous hemangioma because the vascular component is restricted to the superficial dermis.^{1,8}

In contrast to circumscribed angiokeratoma, verrucous hemangioma does not respond well to most usual physical treatments, such as cryotherapy, electrocoagulation and laser therapy, presenting frequent relapses. This is due to its extension down to the subcutaneous tissue, which requires deep and wide excision or, in cases with larger lesions, excision followed by skin grafting.^{1,4,5}

For these reasons, early diagnosis and surgical interventions, with exeresis of lesions that are still reduced in size, are fundamental for obtaining a better cosmetic result. □

REFERENCES

1. Tan YY, Seah CS, Tan PH. Verrucous hemangioma: a case report. *Ann Acad Med Singapore*. 1998;27:255-7.
2. Kawaguchi H, Kawaguchi T, Ishii N, Nakajima H, Ichiyama S. Verrucous hemangioma. *Acta Derm Venereol*. 1997;77:405-6.
3. Wentscher U, Happle R. Linear verrucous hemangioma. *J Am Acad Dermatol*. 2000;42:516-8.
4. Calduch L, Ortega C, Navarro V, Martinez E, Molina I, Jorda E. Verrucous hemangioma: report of two cases and review of the literature. *Pediatr Dermatol*. 2000;17:213-7.
5. Wong DS, Hunt SJ, Inerra DW, Avell E. Unilateral Keratotic vascular lesion on the leg. Verrucous hemangioma. *Arch Dermatol*. 1996;132:705-8.
6. Imperial R, Helwig EB. Verrucous hemangioma. A clinicopathologic study of 21 cases. *Arch Dermatol*. 1967;96:247-53.
7. Mankani MH, Dufresne CR. Verrucous malformations: their presentation and management. *Ann Plast Surg*. 2000;45:31-6.
8. Fitzpatrick TB, Eisen AZ, Wolff K, Freedberg IM, Austen KF, eds. *Dermatology in general medicine*. 4th ed. New York: McGraw-Hill; 1993. p.1219.
9. Arthur R, Wilkinson DS, Ebling FJG, Champion RH, eds. *Textbook of Dermatology*. 6th ed. Oxford: Oxford University Press; 1998. p.567.
10. Alice CZ, Neftalí NV. Angioma verrucoso congénito. *Rev Chil Dermatol*. 1996;12:158.

MAILING ADDRESS:

Emmanuel Rodrigues de França
Av. Boa Viagem, 6372 - apto 701
51130-000 - Recife - PE - Brazil
Tel.: +55 (81) 9927-6720