

Successful treatment of erythrodermic pemphigus foliaceus with intravenous immunoglobulin[☆]



Dear Editor,

Pemphigus foliaceus (PF) is characterized by the presence of superficial vesicles or bullae in the absence of mucosal involvement, it results from the interaction of IgG autoantibodies with desmoglein 1, present in the upper layers of the epidermis.¹ PF is endemically present in Brazil and other South American countries¹ and can manifest as localized and disseminated forms. The disseminated forms are subdivided into four clinical variants, vesico-bullous, keratotic, herpetiform and erythrodermic. In the latter, the entire tegument is erythematous and desquamative, with areas of erosion, exudation, and crusts.²

This case report describes a 68-year-old female patient, who started showing erythematous-desquamative lesions on the face, upper trunk and arms, with circinate edges and lamellar desquamation (Fig. 1A). The edge of one lesion was biopsied and an upper intraepidermal cleavage was demonstrated on histopathology, along with acantholytic cells (Fig. 2), confirming the diagnosis of classic PF, since the patient does not come from an endemic area. Additional confirmation of the diagnosis was obtained through

immunofluorescence, which showed an intercellular epidermal pattern of IgG deposition.

Therapy with 60 mg of oral prednisone was implemented but there was acral expansion of the condition in the following six months, leading to lamellar desquamation of the plantar regions (Fig. 1B). Oral methotrexate (15 mg per week) was added to the therapy, which the patient did not tolerate. The condition continued to expand until it became erythrodermic after six months (Fig. 3A). Therapy was then instituted with intravenous (IV) immunoglobulin, at a total dose of 2 g/Kg/cycle, infused on five consecutive days; a total of four cycles were applied with four-week intervals between one and the next. Relevant clinical improvement was observed (Fig. 3B), with no side effects, which allowed a significant reduction in the oral corticosteroid use, which is currently at 5 mg daily, after a favorable 14-month follow-up.

The use of IV immunoglobulin is well established in autoimmune diseases, including pemphigus,^{3,4} and is recommended for refractory cases such as this one.⁴ Its action mechanism is probably multiple, with the most relevant being perhaps receptor saturation, with consequent immune cell inhibition. In view of the COVID-19 pandemic, the use of rituximab as a therapeutic alternative has been questioned, due to the intense inhibition of the humoral immune response, and so IV immunoglobulin is an excellent option.

There is only one Brazilian report of an adolescent patient with endemic pemphigus foliaceus,⁵ who also developed the

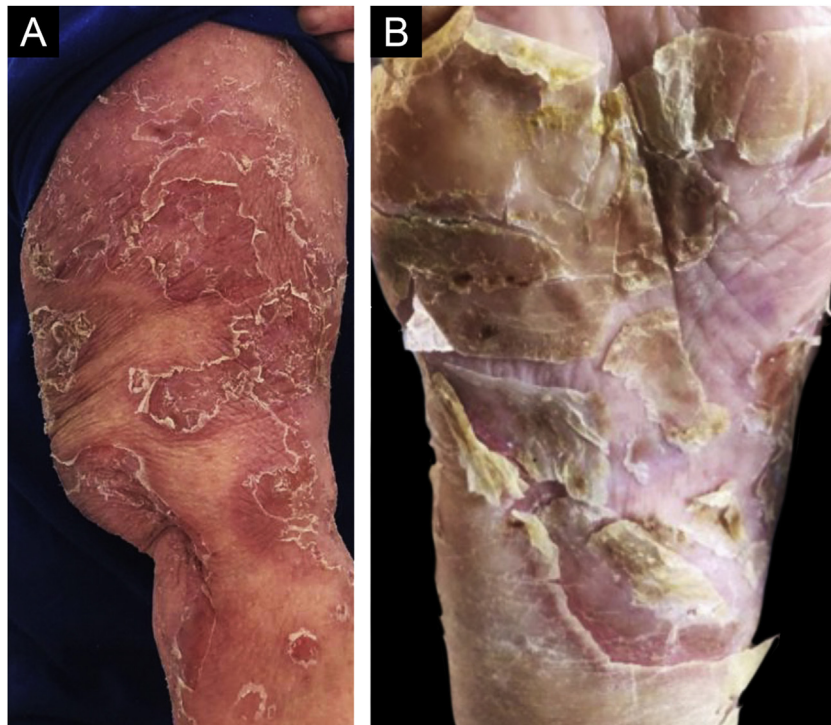


Figure 1 (A) Erythematous-desquamative lesions on the arm, with circinate edges and lamellar desquamation. (B) Plantar lamellar desquamation

[☆] Study conducted at the Universidade Católica de Pelotas, Pelotas, RS, Brazil.

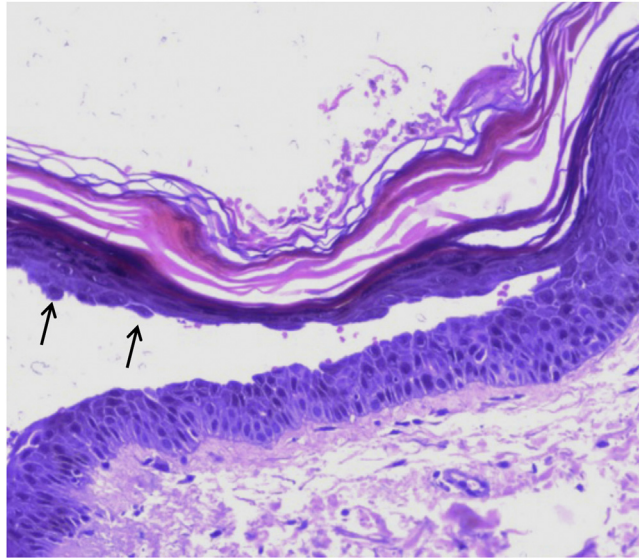


Figure 2 Histopathology showing intraepidermal cleavage and acantholytic keratinocytes (arrows); Hematoxylin & eosin, $\times 200$

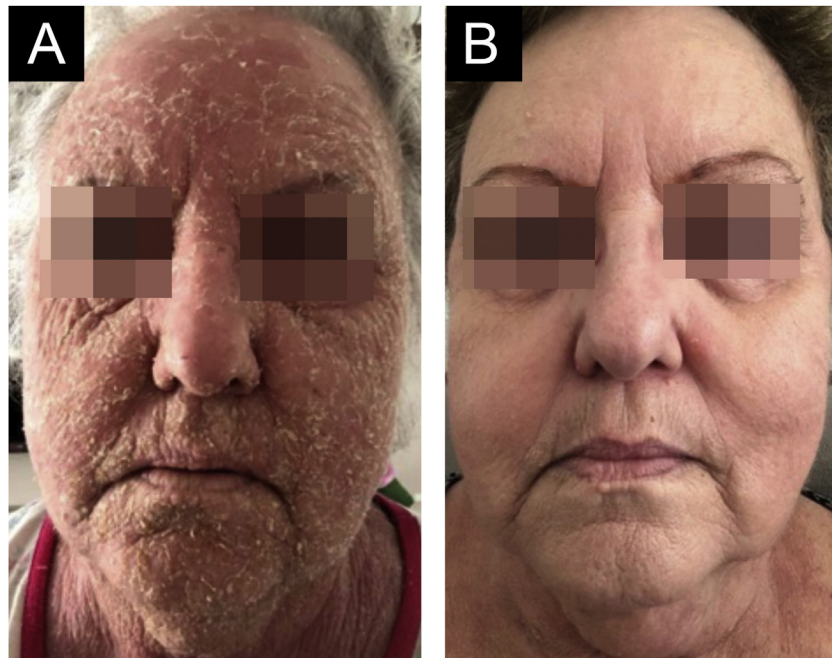

Figure 3 (A) Desquamation of the entire face before treatment. (B) Complete resolution with therapy

erythrodermic form and was treated with IV immunoglobulin. The case reported herein documents the successful use of this therapy in severe and extensive cases of pemphigus foliaceus, which is rare in this age group.

Financial support

None declared.

Authors' contributions

Hiram Almeida Jr: Approval of the final version of the manuscript; design and planning of the study; drafting and editing of the manuscript; collection, analysis, and interpretation of data; effective participation in research orientation; critical review of the manuscript.

Junior Wieczorek: Approval of the final version of the manuscript; design and planning of the study; drafting and

editing of the manuscript; collection, analysis, and interpretation of data; critical review of the manuscript.

Mahony Santana: Approval of the final version of the manuscript; design and planning of the study; drafting and editing of the manuscript; collection, analysis, and interpretation of data; critical review of the manuscript.

Celina Leite: Approval of the final version of the manuscript; design and planning of the study; drafting and editing of the manuscript; collection, analysis, and interpretation of data; critical review of the manuscript;

Conflicts of interest

None declared.

References

1. Aoki V, Rivitti EA, Diaz LA, Cooperative Group on Fogo Selvagem Research. Update on fogo selvagem, an endemic form of pemphigus foliaceus. *J Dermatol.* 2015;42:18–26.
2. Hans-Filho G, Aoki V, Bittner NRH, Bittner GC. Fogo selvagem: endemic pemphigus foliaceus. *An Bras Dermatol.* 2018;93:638–50.
3. Amagai M, Ikeda S, Shimizu H, Iizuka H, Hanada K, Aiba S, et al. A randomized double-blind trial of intravenous immunoglobulin for pemphigus. *J Am Acad Dermatol.* 2009;60:595–603.
4. Porro AM, Hans Filho G, Santi CG. Consensus on the treatment of autoimmune bullous dermatoses: pemphigus vulgaris and pemphigus foliaceus – Brazilian Society of Dermatology. *An Bras Dermatol.* 2019;94:20–32.
5. Teixeira TA, Fiori FC, Silvestre MC, Borges CB, Maciel VG, Costa MB. Refractory endemic pemphigus foliaceus in adolescence successfully treated with intravenous immunoglobulin. *An Bras Dermatol.* 2011;86:S133–6.

Hiram Larangeira de Almeida Jr. ^{a,b,*},
Junior Wiczorek ^a, Mahony Santana ^b,
Celina Leite ^c

^a Postgraduate Program in Health and Behavior, Universidade Católica de Pelotas, Pelotas, RS, Brazil

^b Department of Dermatology, Universidade Federal de Pelotas, Pelotas, RS, Brazil

^c Faculty of Medicine, Universidade Católica de Pelotas, Pelotas, RS, Brazil

* Corresponding author.

E-mail: hiramalmeidajr@hotmail.com (H.L. Almeida Jr.).

Received 9 March 2022; accepted 24 May 2022

Available online 22 September 2023

<https://doi.org/10.1016/j.abd.2022.05.013>

0365-0596/ © 2023 Sociedade Brasileira de Dermatologia.

Published by Elsevier España, S.L.U. This is an open access article under the CC BY license (<http://creativecommons.org/licenses/by/4.0/>).

Unresectable auricular squamous cell carcinoma with locoregional metastasis: use of cemiplimab in an immunosuppressed patient*



Dear Editor,

An 81-year-old male agricultural worker, with hypertension complicated with nephropathy and renal transplantation in 2005, using sirolimus, was submitted to radiotherapy and hormone blockade therapy in 2017 for prostate cancer. He had a past history of multiple basal cell carcinomas and squamous cell carcinomas (SCCs). He developed a moderately differentiated, ulcerated, and infiltrating SCC in the right auricular pinna (Fig. 1A), considered unresectable due to recurrence after four surgical interventions, with involvement of the perichondrium, cervical lymph nodes, and salivary glands, demonstrated by anatomopathological examination. Screening for distant metastasis through PET-CT was negative, and he was classified as T3N2bM1. He received intravenous cemiplimab, 350 mg every 21 days, and 20 sessions of radiotherapy (RT), 20 fractions of 250 cGy, a total dose of 50 Gy, in the tumor and auricular pinna, with

complete involution of the neoplasm and regional involvement in four months (Fig. 1B), evaluated clinically and through a second PET-CT. There were no adverse effects to the medication. He evolved with progression of the prostate cancer, confirmed by anatomopathological examination, and died 14 months after the use of cemiplimab.

Around 5% of SCCs are classified as advanced neoplasia when they present as locally advanced or metastatic and not amenable to curative surgery and/or curative radiotherapy.^{1,2} Until recently, chemotherapy and epidermal growth factor receptor inhibitors were the only options available for these cases, with low efficacy, nonsustained response rates, and various side effects, being considered palliative treatments.¹

Cemiplimab is the first approved systemic treatment for SCC that improves survival. This is a fully human anti-PD-1 IgG4 antibody.³ An indirect comparison of treatments concluded that it is the systemic therapy with the strongest evidence of clinical benefit for advanced cases and improved survival.⁴

The high mutation burden present in SCCs from exposure to ultraviolet radiation has been associated with the effectiveness of PD-1 inhibition in several advanced solid neoplasms.^{1,2} Furthermore, the strong association between immunosuppression and tumor risk has suggested that immunosurveillance plays an important role in tumor control, and approaches to enhance the anti-tumor immune system may be effective.¹

* Study conducted at the Hospital Mater Dei, Belo Horizonte, MG, Brazil.