

Disabling Acne Fulminans^{*}

Acne fulminans incapacitante

Tiago Pina Zanelato¹
Célia Antônia Xavier de Moares Alves²
Paulo Rowilson Cunha⁴

Gabriela Maria Abreu Gontijo¹
Jacqueline Campoi Calvo Lopes Pinto³

Abstract: Acne fulminans is a rare manifestation that may occur during the evolution of acne vulgaris primarily in male adolescents. Use of isotretinoin, testosterone, and exacerbated immune responses in the body are related triggers. Signs, symptoms and laboratory findings such as fever, hepatomegaly, polyarthralgia, leukocytosis, plaquetose, increased inflammatory markers and transaminases, are characteristic. A bone scan can detect osteolytic lesions in multiple skeletal sites. The treatment is performed with prednisolone, isotretinoin and antibiotics if secondary infection is present. This case describes a male patient with a diagnosis of grade III acne, who developed acne fulminans and bilateral sacroiliitis with inability to ambulate, after initiation of therapy with isotretinoin.

Keywords: Arthralgia; Isotretinoin; Prednisone

Resumo: Acne fulminans é uma manifestação rara, que pode ocorrer durante a evolução da acne vulgar, principalmente, em adolescentes masculinos. Uso de isotretinoína, testosterona, e reações imunológicas exacerbadas no organismo são desencadeantes relacionados. Sinais, sintomas e alterações laboratoriais como: febre, hepatomegalia, poliartralgia, leucocitose, plaquetose, aumento de provas inflamatórias e transaminases, são característicos. A cintilografia óssea pode detectar lesões líticas em vários sítios do esqueleto. O tratamento é realizado com prednisolona, isotretinoína e antibióticos se infecções secundárias. Este caso relata um paciente masculino com diagnóstico de acne grau III, que desenvolveu acne fulminans e sacroileíte bilateral, com incapacidade de deambulação após início de terapia com isotretinoína.

Palavras-chave: Artralgia; Isotretinoína; Prednisona

INTRODUCTION

Acne fulminans is a very rare, severe manifestation that can develop during the course of acne vulgaris. Synonyms like acne maligna and acute febrile ulcerative acne conglobata were substituted by the term acne fulminans described in 1975 by Plewig and Kligman.¹ It develops mostly in male adolescents, aged 13 to 16, with mild to moderate acne.² Its etiology is not yet fully understood. Heredity, exacer-

bated immune reactions, bacterial infections and use of some drugs such as isotretinoin, tetracycline and testosterone can be triggering factors.^{2,3,4} It is postulated that some antigens found on the bones and skin are similar to bacterial antigens and, through a hypersensitivity immune reaction, cause the bone lesions.⁵ There are cases described in association with Cohn's disease and after measles infection.^{6,7}

Received on 05.10.2010.

Approved by the Advisory Board and accepted for publication on 21.10.2010.

^{*} Work performed at the Dermatology Department of the Faculdade de Medicina de Jundiaí (FMJ) – Jundiaí (SP), Brasil.

Conflict of interest: None / *Conflito de interesse: Nenhum*

Financial funding: None / *Suporte financeiro: Nenhum*

¹ Medical resident of the Dermatology Service of the Faculdade de Medicina de Jundiaí (FMJ) – Jundiaí (SP), Brasil.

² Dermatologist – Assistant Teacher of the Dermatology Service of the Faculdade de Medicina de Jundiaí (FMJ) – Jundiaí (SP), Brasil.

³ Dermatologist. – Collaborating Teacher of the Dermatology Service of the Faculdade de Medicina de Jundiaí (FMJ) – Jundiaí (SP), Brasil.

⁴ Full Professor and Chief of the Dermatology Service of the Faculdade de Medicina de Jundiaí (FMJ). Associate Professor of the Faculdade de Medicina da Universidade de São Paulo (FMUSP) – São Paulo (SP), Brasil.

©2011 by Anais Brasileiros de Dermatologia

Acne fulminans manifests in patients previously diagnosed with mild to moderate acne, as an acute onset of multiple papules, plaques, hemorrhagic nodules, and ulcerations with necrotic floor that evolve to extensive scarring.² It develops on the face, trunk and rarely on the thighs. Signs and symptoms like fever, hepatosplenomegaly, polyarthralgias, polyarthritis (mostly in large joints), erythema nodosum, myalgia, anorexy, and weight loss might be present.^{8,9}

Laboratory tests usually show leukocytosis, thrombocytosis, anaemia, microscopic hematuria, increased hemossedimentation rate, reactive C protein and alteration of the hepatic enzymes.⁹ Bone scintigraphy can detect inflammatory and lithic lesions with increased uptake of the radiotracer.¹⁰

The treatment is based on the use of prednisolone with gradual reduction of the dose and concomitant or subsequent introduction of isotretinoin.^{2,9,11} Systemic antibiotics can be associated to control secondary infections and local care of the lesions involves use of compresses and emollients.

CASE REPORT

The authors report a case of a male patient, 14 years old, with dark skin, with acne level III, in use of tetracycline for two months without improvement. After 12 days of beginning isotretinoin (0.5 mg per kilo per day) associated to prednisone (0,1 mg per kilo per day) there was worsening of the acne with sudden development of ulceronecrotic lesions on the face, back and trunk. (Figures 1 and 2). He also complained of fever, severe pain on the rib cage, hips and lower limbs, associated with inability to walk and in

use of wheelchair. The laboratory tests showed; leukocytosis: 20490/mm³, (without deviation to the left); thrombocytosis: 849000/mm³; reactive C protein: 93,4mg/dl; hemossedimentation rate: 30mm; **gamma glutamyl transferasis**: 175U/l (normal < 30U/l); normal transaminases and bilirubins; negative HLA B27, ANF, and hemocultures. Imaging exams (simple x-ray, ultrasound and computerized tomography of the pelvis) were unaltered. Bone **scintigraphy** showed evidence of bilateral **sacroiliitis** and multiple osteoarticular processes with abnormal bone activity on the sternoclavicular, **scapulothoracic**, costochondral, mandible, ankles and lumbar spine joints. (Figure 3). The patient was admitted to hospital and the isotretinoin was suspended. He was treated with prednisone (0,5mg per kilo per day), acetaminofen 500mg four times daily, associated to sulfamethoxazole-trimethoprim (800/160mg) twice a day for secondary infection. The cutaneous lesions improved and the patient was able to walk again in 15 days. Isotretinoin was reintroduced (0,2mg per kilo per day) 30 days after being suspended. After two months the dose was increased to 0,5 mg per kilo per day with gradual reduction of the corticosteroid. (Figures 4 and 5).

DISCUSSION

The reported case represents a typical case of acne fulminans, a rare manifestation with few cases described on the literature. The development of ulceronecrotic lesions on the face, back and chest in male young patients with moderate acne associated with fever, polyarthralgia, laboratorial and scintigraph-

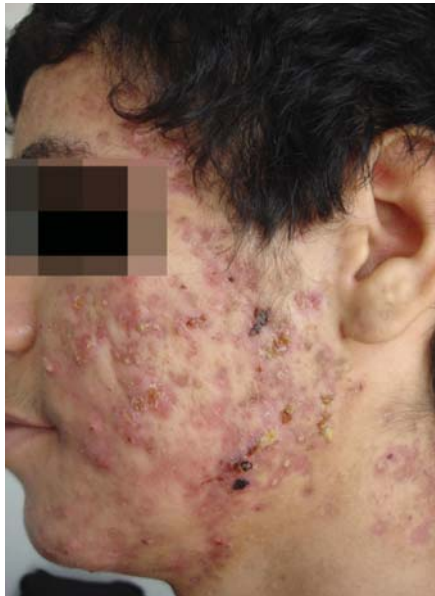

FIGURE 1:
Papules, pustules, confluent nodules and ulceronecrotic lesions on the face

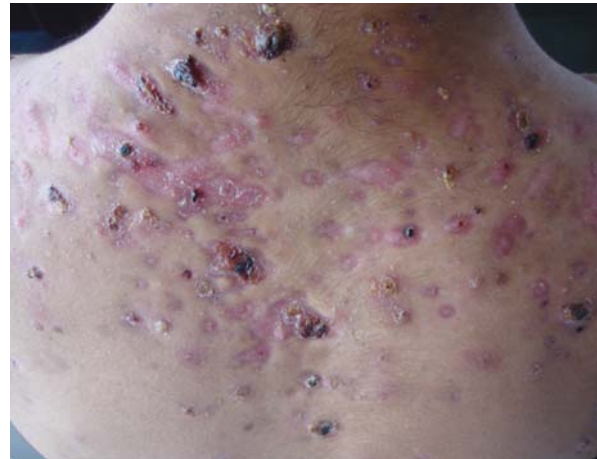


FIGURE 2: Ulceronecrotic lesions on the back

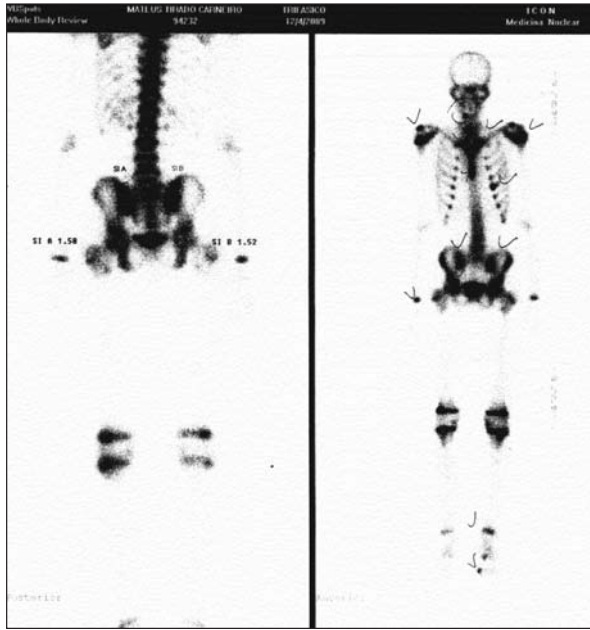


FIGURE 3: Bone scintigraphy: multiple osteoarticular processes – indicated by arrows

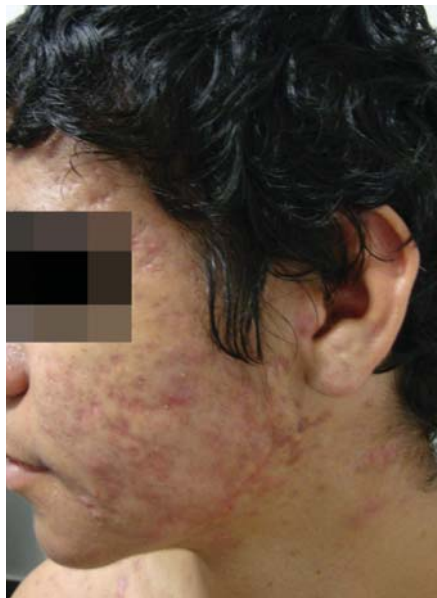

FIGURE 4: After two months of treatment: nodules and extensive scars on the face

ic abnormalities are characteristic of this disease. On the present case we regard the beginning of the therapy with isotretinoin as the triggering factor of the acne fulminans.^{9,12} This could be explained by the increased fragility of the pilosebaceous ducts induced

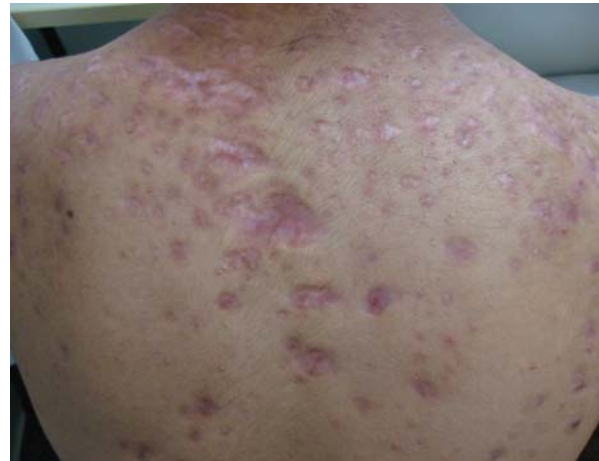

FIGURE 5: After two months of treatment: extensive scars on the back

by isotretinoin and the extensive exposure to *Propionibacterium acnes* antigens.² The chemotaxis of the neutrophils and an exacerbated immune response to these antigens could have been a possible trigger.¹³ Polyarthralgia, as seen on various involved sites through the scintigraphy, and especially the extreme sacroiliitis, reported in 21% of the patients with acne fulminans, lead to the patient's notable incapacity for walking. He had to use a wheelchair and later a walking aid to help him move around.⁸

Osteolytic lesions, with increased radiotracer uptake at scintigraphy, on the sternum, clavicle, sacroiliac joints, humerus and ankles are described.^{9,12} Usually they are sterile and have a good prognosis. Previous studies revealed growth of *Propionibacterium acnes* on culture of an osteolytic lesion in only one patient.¹⁴

Hemocultures from the patient collected during febrile episodes were negative, in accordance to the literature review. Of the other 15 reported cases all hemocultures were negative.⁹ The use of prednisone and sulfamethoxazole-trimethoprim as the treatment of choice led to the clinical improvement of the patient with return to his usual activities. The use of antibiotic was aimed at treating the secondary infection as well as at diminishing possible existent super antigens. The reintroduction of the isotretinoin was gradual due to the risk of worsening of the symptoms. Despite being a triggering factor it is indicated on treatment of acne fulminans in low doses with subsequent increase according to the patient's tolerance.¹⁵ □

REFERENCES

1. Plewig G, Kilgman AM. Acne: Morphogenesis and Treatment. Berlin: Springer; 1975. p.196.
2. Jansen T, Plewig G. Review Acne fulminans. Int J Dermatol. 1998;37:254-7
3. Wong SS, Pritchard MH, Holt PJA. Familial acne fulminans. Clin Exp Dermatol. 1992;17:351-3.
4. Fyrand O, Fiskadaal HJ, Trygstad O. Acne in pubertal boys undergoing treatment with androgens. Acta Derm Venereol. 1992;72:148-9.
5. Hunter LY, Hensinger RN. Destructive arthritis associated with acne fulminans: a case report. Ann Rheum Dis. 1980;39:403-5.
6. McAuley D, Miller RA. Acne fulminans associated with inflammatory bowel disease: report of a case. Arch Dermatol. 1985;121:91-3.
7. Honma M, Murakami M, Iinuma S, Fujii M, Komatsu S, Sato K, et al. Acne fulminans following measles infection. J Dermatol. 2009;36:471-3.
8. Barbareschi M, Paresce E, Chiaratti A, Ferla LA, Clerici G, Greppi F. Unilateral sacroiliitis associated with systemic isotretinoin treatment. Int J Dermatol. 2010;49:331-3.
9. Karvonen SL. Acne fulminans: Report of clinical findings and treatment of twenty-four patients. J Am Acad Dermatol. 1993;28:572-9.
10. Jemec GBE, Rasmussen L. Bone lesions of acne fulminans. J Am Acad Dermatol. 1989;20:353-7.
11. Allison MA, Dunn CL, Person DA. Acne fulminans treated with isotretinoin and pulse/corticosteroids. Pediatr Dermatol. 1997;14:39-42.
12. Cavicchini S, Ranza R, Brezzi A. Acne fulminans with sacroiliitis during isotretinoin therapy. Eur J Dermatol. 1992;2:327-8.
13. Perkins W, Crockett KV, Hodgkins MB. The effect of treatment with 13-cis-retinoic acid on the metabolic burst of peripheral blood neutrophils from patients with acne. Br J Dermatol. 1991;124: 429-32.
14. Nault P, Lassonde M, St-Antoine P. Acne fulminans with osteolytic lesions. Arch Dermatol. 1985;121: 662-4.
15. Thomson KF, Cunliffe WJ. Acne fulminans `sine fulminans. Clin Exp Dermatol. 2000;25:299-301.

MAILING ADDRESS / ENDEREÇO PARA CORRESPONDÊNCIA:

Tiago Pina Zanelato

Rua Francisco Telles 250

Vila Arens - Jundiaí - SP, Brazil

Cep: 13202-550

E-mail: tizanelato@hotmail.com

How to cite this article/*Como citar este artigo*: Zanelato TP, Gontijo GMA, Alves CAXM, Pinto JCCL, Cunha PR. Disabling Acne Fulminans. An Bras Dermatol. 2011;86(S1):S9-12.

An Bras Dermatol. 2011;86(4Supl1):S9-12.