

## Financial support

None declared.

## Authors' contributions

Elena Canal-Garcia: Study concept and design; drafting and editing of the manuscript; writing of the manuscript or critical review of important intellectual content; data collection, analysis and interpretation; effective participation in the research guidance; intellectual participation in the propaedeutic and/or therapeutic conduct of the studied cases; critical review of the literature; final approval of the final version of the manuscript.

Xavier Soria: Study concept and design; drafting and editing of the manuscript; writing of the manuscript or critical review of important intellectual content; data collection, analysis and interpretation; effective participation in the research guidance; intellectual participation in the propaedeutic and/or therapeutic conduct of the studied cases; critical review of the literature; final approval of the final version of the manuscript.

Felip Vilardell: Writing of the manuscript or critical review of important intellectual content; data collection, analysis and interpretation; effective participation in the research guidance; intellectual participation in the propaedeutic and/or therapeutic conduct of the studied cases; critical review of the literature; final approval of the final version of the manuscript.

Rosa M. Martí: Study concept and design; drafting and editing of the manuscript; writing of the manuscript or critical review of important intellectual content; data collection, analysis and interpretation; effective participation in the research guidance; intellectual participation in the propaedeutic and/or therapeutic conduct of the studied cases; critical review of the literature; final approval of the final version of the manuscript.

## Conflicts of interest

None declared.

## References

1. Requena C, Requena L, Kutzner H, Yus ES. Spitz nevus: a clinicopathological study of 349 cases. *Am J Dermatopathol*. 2009;31:107–16.
2. Lallas A, Apalla Z, Ioannides D, Lazaridou E, Kyrgidis A, Broganelli P, et al. Update on dermoscopy of Spitz/Reed naevi and management guidelines by the International Dermoscopy Society. *Br J Dermatol*. 2017;177:645–55.
3. Nakagawa K, Kishida M, Okabayashi A, Shimizu N, Taguchi M, Kinoshita R, et al. Spitz nevus on the palm with crista transverse dots/dotted lines revealed by dermoscopic examination. *J Dermatol*. 2015;42:649–50.
4. Montenegro Jaramillo SE, Jo G, Darmawan CC, Lee C, Mun J-H. Dermoscopic findings of Spitz nevus on acral volar skin. *Indian J Dermatol Venereol Leprol*. 2019;85:629–32.
5. Jurakić Tončić R, Bradamante M, Ferrara G, Štulhofer-Buzina D, Petković M, Argenziano G. Parallel ridge dermoscopic pattern in plantar atypical Spitz nevus. *J Eur Acad Dermatol Venereol*. 2018;32:e86–121.

Elena Canal-Garcia <sup>a,\*</sup>, Xavier Soria <sup>a</sup>, Felip Vilardell <sup>b</sup>, Rosa M. Martí <sup>a,c</sup>

<sup>a</sup> Department of Dermatology, Hospital Universitari Arnau de Vilanova, University of Lleida, IRBLleida, Lleida, Spain

<sup>b</sup> Department of Pathology, Hospital Universitari Arnau de Vilanova, University of Lleida, IRBLleida, Lleida, Spain

<sup>c</sup> Centre of Biomedical Research on Cancer, Instituto de Salud Carlos III, Madrid, Spain

\* Corresponding author.

E-mail: [ecanal.germanstrias@gencat.cat](mailto:ecanal.germanstrias@gencat.cat) (E. Canal-Garcia).

Received 5 February 2021; accepted 1 May 2021;

Available online 3 January 2023

<https://doi.org/10.1016/j.abd.2021.05.022>

0365-0596/ © 2022 Sociedade Brasileira de Dermatologia.

Published by Elsevier España, S.L.U. This is an open access article under the CC BY license (<http://creativecommons.org/licenses/by/4.0/>).

## Bilateral giant Becker's nevus<sup>☆</sup>



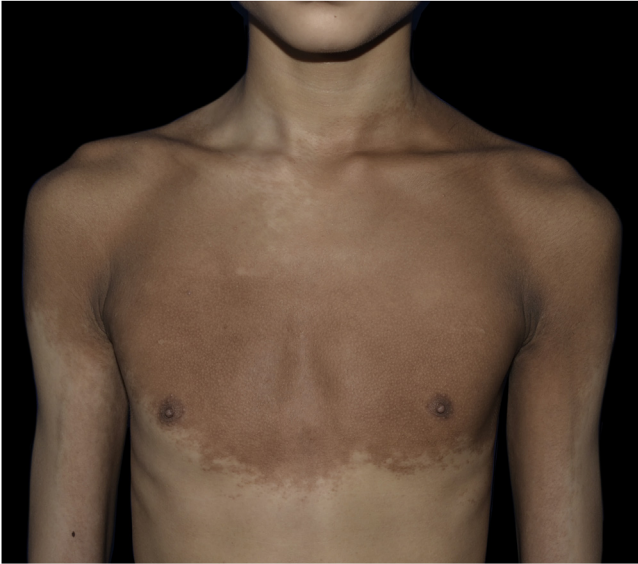
Dear Editor,

A 13-year-old boy presented with a 6-year history of multiple asymptomatic brown macules affecting the chest and scapular regions bilaterally. The pigmentation gradually darkened and progressively involved the neck, right forearm, both shoulders, upper arms, and axillae (Figs. 1 and 2). Increased hairs were observed on the lesions. No other accompa-

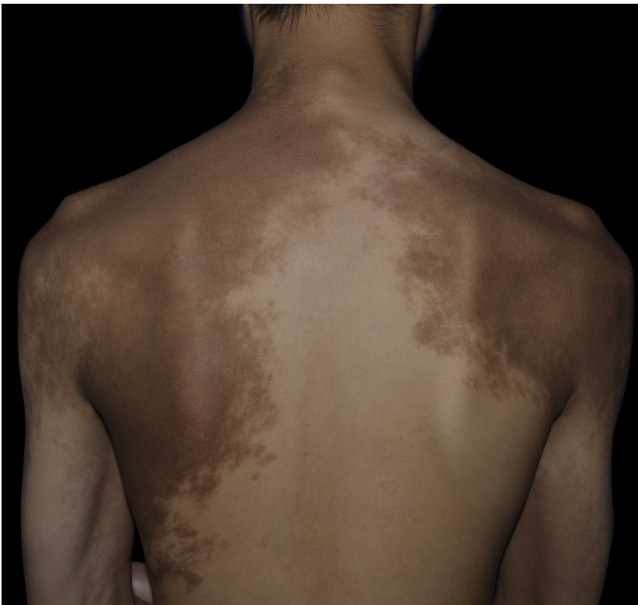nied abnormality of the skin or musculoskeletal system was found. Familial and medical histories were unremarkable. Laboratory investigations including complete blood cell count, liver, and renal function were all normal. Radiography of the chest, spine and upper extremities also showed no abnormality. The histopathological examination revealed slight hyperkeratosis, with acanthosis, elongation, and fusion of the epidermal ridges and hyperpigmentation of the basal layer (Fig. 3). These features were suggestive of Becker's nevus.

Becker's nevus is a type of epidermal nevus, characterized by a single hyperpigmented patch with or without hypertrichosis, and predominantly involves the unilateral upper trunk, scapular region, or upper arm unilaterally, the

<sup>☆</sup> Study conducted at the Department of Dermatovenereology, Chengdu Second People's Hospital, Chengdu, Sichuan, China.



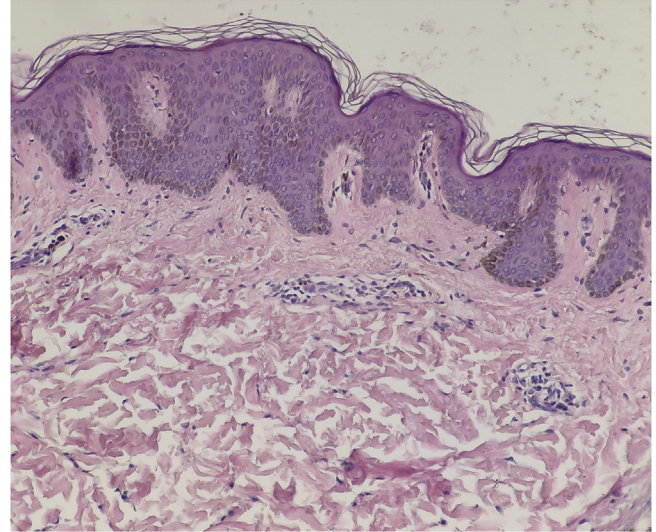
**Figure 1** Multiple brown macules with hypertrichosis on the chest, shoulders, upper arms and axillae.



**Figure 2** The pigmentation on the neck and scapular regions.

disorder most likely reflects mosaicism. Becker's nevus is an androgen-dependent lesion because it becomes more prominent after adolescence and tends to be more conspicuous in male patients because of increased hairiness of this area. The male-to-female ratio was said to be 2:1~5:1.<sup>1,2</sup> However, some authors believed that the true sex ratio may be 1:1, due to Becker's nevus tends to be less conspicuous in female patients.<sup>1,3</sup> The other pathogenetic hypothesis of Becker's nevus was postzygotic mutations in beta-actin.<sup>4</sup>

Multiple or bilateral Becker's nevus is rarely reported in the literature. We reviewed a total of 25 reported cases of bilateral Becker's nevus recently.<sup>5</sup> Among them, the male-to-female ratio was 18:7; 10 cases presented a single giant coalescent lesion; 15 cases were multiple separated lesions. The lesion distribution presented as symmetrical



**Figure 3** The histopathological examination revealed slight hyperkeratosis, acanthosis, elongation, and fusion of the epidermal ridges, with hyperpigmentation of the basal layer (Hematoxylin & eosin,  $\times 200$ ).

or asymmetrical (including 4 cases of checkerboard pattern). Like common Becker's nevus, the majority of bilateral Becker's nevus manifested in adolescence, and only a few patients present at birth or shortly after birth. There were 6 cases with extracutaneous abnormalities, so-called Becker's nevus syndrome, including breast hypoplasia, musculoskeletal defects, mental retardation, and cardiac defects. The incidence of Becker's nevus syndrome appears to be higher in bilateral Becker's nevus. Therefore, patients with a diagnosis of bilateral Becker's nevus should undergo clinical evaluation for extracutaneous involvement.

### Financial support

None declared.

### Authors' contributions

Li-Wen Zhang and Cun-Huo Jiang contributed equally to this work.

Li-Wen Zhang: Study conception and planning, preparation and writing of the manuscript.

Cun-Huo Jiang: Acquisition of data.

Lin Li: Literature review.

Tao Chen: Approval of the final version of the manuscript.





### Conflicts of interest

None declared.

### References

1. Danarti R, Konig A, Salhi A, Bittar M, Happle R. Becker's nevus syndrome revisited. *J Am Acad Dermatol.* 2004;51:965-9.

- Alhuqayl A, Alsaif F, Alsaad A, Alali A. Multiple bilateral Becker's nevus in a Saudi female: a rare presentation. *AME Case Rep.* 2019;3:42.
- Happle R, Koopman RJ. Becker nevus syndrome. *Am J Med Genet.* 1997;68:357–61.
- Cai ED, Sun BK, Chiang A, Rogers A, Bernet L, Cheng B, et al. Postzygotic Mutations in Beta-Actin Are Associated with Becker's Nevus and Becker's Nevus Syndrome. *J Invest Dermatol.* 2017;137:1795–8.
- Antunes-Duarte S, Bouceiro-Mendes R, Fraga A, Soares-de-Almeida L. One person, two bilateral symmetrical giant Becker nevi. *Dermatol Online J.* 2020;26, 13030/qt44x2j7nr.

Li-Wen Zhang , Cun-Huo Jiang , Lin Li ,  
Tao Chen \*

Department of Dermatovenereology, Chengdu Second People's Hospital, Chengdu, Sichuan, China

Corresponding author.

E-mail: 13980427003@163.com (T. Chen).

Received 16 April 2021; accepted 14 May 2021;  
Available online 23 January 2023

<https://doi.org/10.1016/j.abd.2021.05.024>

0365-0596/ © 2022 Published by Elsevier España, S.L.U. on behalf of Sociedade Brasileira de Dermatologia. This is an open access article under the CC BY license (<http://creativecommons.org/licenses/by/4.0/>).

## Case for diagnosis. Hair analysis in a child with delayed psychomotor development and fragile and brittle hair: Trichothiodystrophy<sup>☆</sup>



Dear Editor,

A 4-year-old female child presented to the Dermatology Department with short, thin, and fragile hair since birth (Fig. 1). She also presented important xerosis and eczematous plaques in her back, trunk, and scalp and photosensitivity. The patient also had short stature, severe myopia, delayed psychomotor development, and recurrent respiratory infections.

Examination of the hair under a polarized light microscope showed fine hair and trichoschisis with typical alternating dark and light transverse banding, called "tiger-tail pattern" (Fig. 2) and an irregular surface (Fig. 3).

A genetic study revealed a mutation in the ERCC2 gene.

### What is your diagnosis?

- Xeroderma Pigmentosum
- Trichothiodystrophy
- Menkes disease
- Cockayne syndrome

### Discussion

Based on clinical presentation, trichological and genetic examination, the diagnosis of trichothiodystrophy was established.

Trichothiodystrophy (TTD) is a heterogeneous group of neuroectodermal disorders with an autosomal recessive inheritance, although a few cases with possible X-linked transmission have been reported. The photosensitive form

of TTD is caused by mutations in XPB, XPD, or p8/TTDA genes, which encode subunits of TFIIH transcription/repair factor. Non-photosensitive form of TTD is genetically heterogeneous, being TTDN1 gene the one described in a small proportion of patients.<sup>1</sup> In photosensitive TTD, the most frequently described is XPD (ERCC2) mutation,<sup>2</sup> which is also involved in the pathogenesis of xeroderma pigmentosum (XP) and Cockayne syndrome, although, unlike XP, there is no predisposition to cutaneous malignancies. XP, Cockayne syndrome, and TTD are an example of the phenomenon called clinical heterogeneity, in which mutations in one gene (in this case XPD) may result in distinct diseases or variants.<sup>3</sup>

Clinical features of patients with TTD vary widely in nature and severity, and the single common feature in all patients is fragile hair (short, unruly, fragile hair of the scalp, eyebrows, and eyelashes) due to abnormally low sulfur content. In addition, a wide spectrum of other clinical symptoms that usually affect organs of ectodermal and neuroectodermal origin may be present, such as intellectual and growth retardation, ichthyosis, short stature, decreased fertility, neurologic and ocular abnormalities and, in some cases, recurrent infections,<sup>4</sup> as in the case of our patient. Approximately half of the patients present photosensitivity.<sup>1,4</sup>

When examined under a polarized microscope, hair samples constantly show striking bright and dark transverse banding or "tiger tail pattern", and they often exhibit an undulating, irregular contour in all hairs (differently from pseudo-tiger tail banding).<sup>5,6</sup> Trichoschisis and trichorrhhexis nodosa-like defects are also distinctive hair shaft abnormalities in TTD though not always present. In contrast to TTD, other patients with similar defects in DNA repair and mutations in the XPD gene do not show true "tiger tail banding". A "pseudo-tiger tail banding" can be observed in segments of normal shafts, but the banding pattern is usually less pronounced and less regular than the bright and dark banding observed in TTD patients.<sup>5</sup> In fact, characteristic microscopic hair findings distinguish trichothiodystrophy from other conditions with congenital alopecia or hypotrichosis. For example, patients with Menkes disease typically present "kinky hairs" with twists around their long axis at irregular intervals in the shaft

<sup>☆</sup> Study conducted at the Hospital Regional Universitario de Málaga, Málaga, Spain.