

## RESEARCH LETTER

### Allergic contact dermatitis to corticosteroids: experience of a referral clinic from 2014 to 2018<sup>☆</sup>



Dear Editor,

The use of topical corticosteroids is common in dermatological practice. Due to their anti-inflammatory and immunomodulatory effects, they are often the drugs of choice in the treatment of dermatites. However, there is little discussion regarding the role of corticosteroids as possible triggers of an allergic process.<sup>1,2</sup>

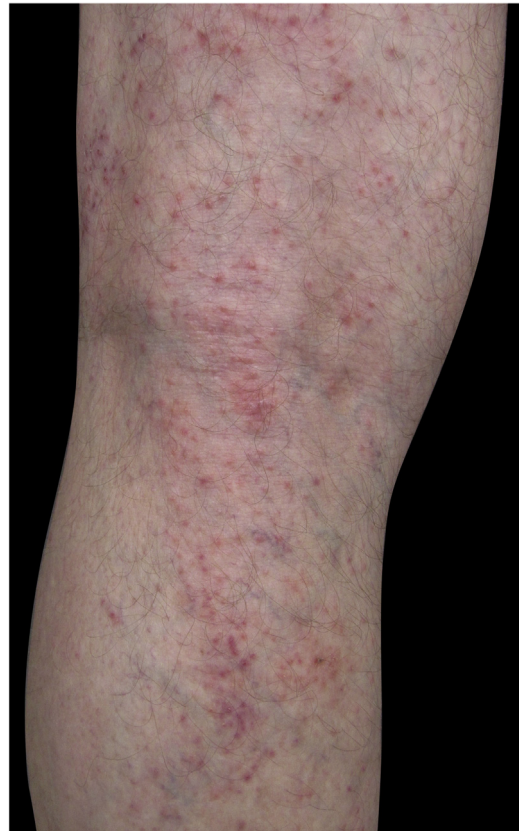As they have low molecular weight and are lipophilic molecules, they have the capacity to penetrate the skin barrier in a relatively easy way, binding to carrier proteins and transforming into immunogens. These are phagocytosed and sensitize T-lymphocytes so that in subsequent contacts, they might trigger a cell hypersensitivity reaction, manifesting as allergic contact dermatitis (ACD).<sup>2-4</sup>

The frequency of ACD to corticosteroids varies from 0.5 to 5% in the literature.<sup>1,3</sup> In Brazil, there are no statistical data on the topic, which justifies the performance of the current study, which was approved by the Ethics Committee of the institution. (33471620.7.0000.5479).

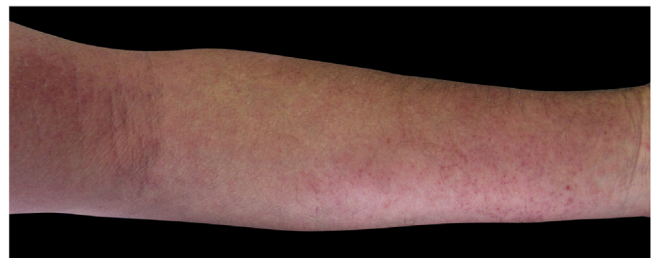Through the analysis of data from the service medical records, a total of six patients diagnosed with ACD to corticosteroids was found, two (33.3%) male and four (66.7%) female patients, representing 1% of the total cases submitted to patch tests from 2014 to 2018. The mean age of these patients was 60 years (ranging from 37 to 76 years), and the symptom period ranged from five months to 17 years, with a mean time for diagnosis of five and a half years. The long period reflects a probable difficulty in accessing a specialized dermatological service, delaying the diagnosis and resulting in greater morbidity.

According to the literature, the main risk factors for ACD to corticosteroids are the presence of previous chronic dermatoses, use of corticosteroids without medical follow-up, and genetic susceptibility.<sup>1</sup> Corroborating these findings, the six patients had a history of irregular and prolonged use of topical corticosteroids, as well as previous dermatoses: psoriasis in two (33.3%), stasis dermatitis in two (33.3%), and chronic eczema of undefined etiology in two (33.3%).

Four (66.7%) of the six cases had lesions in the lower limbs, two (33.3%) in the upper limbs, one (16.7%) in



**Figure 1** Eczema on the lower limb due to allergic contact dermatitis to corticosteroid.



**Figure 2** Eczema on the upper limb due to allergic contact dermatitis to corticosteroid.

the trunk, and two (33.7%) had a disseminated pattern (Figs. 1 and 2). The typical picture, as in the present cases, is a dermatosis that is refractory to treatment with corticosteroids, characterized by eczematous lesions, which may be more evident on the edges than in the center. More-

<sup>☆</sup> Study conducted at the Clínica de Dermatologia da Santa Casa de São Paulo, São Paulo, SP, Brazil.

**Table 1** Classification of the corticosteroids (Baeck et al., 2011).<sup>7</sup>

Group 1	Group 2	Group 3
Non-methylated and mostly non-halogenated (Group A and D2 of the Coopman classification, and budesonide)	Halogenated with C16/C17 cis ketal/diol structure (Group B of the Coopman classification)	Halogenated and C16-methylated molecules (Group C and D1 of the Coopman classification)
Budesonide	Triamcinolone	Alclomethasone dipropionate
Cloprednol	Amcinonide	Beclomethasone dipropionate
Cortisone acetate	Desonide	Betamethasone
Dichlorisone acetate	Flucoronide	Betamethasone 17-valerate
Difluprednate	Flumoxonide	Betamethasone dipropionate
Fludrocortisone acetate	Flunisolide	Betamethasone sodium phosphate
Fluorometholone	Fluocinolone acetonide	Clobetasol propionate
Prednisolone acetate	Fluocinonide	Clobetasone butyrate
Hydrocortisone	Halcinonide	Deoxymethasone
Hydrocortisone aceponate	Triamcinolone acetonide	Dexamethasone
Hydrocortisone acetate	Triamcinolone benetonide	Dexamethasone acetate
Hydrocortisone 17-butyrate	Triamcinolone diacetate	Dexamethasone sodium phosphate
Hydrocortisone 21-butyrate	Triamcinolone hexacetonide	Diflucortolone valerate
Hydrocortisone succinate		Diflorasone diacetate
Isofluprednone acetate		Flumethasone pivalate
Mazipredone		Fluocortin butyl
Medrisone		Fluocortolone
Methylprednisolone acetate		Fluocortolone caprylate
Methylprednisolone aceponate		Fluocortolone pivalate
Methylprednisolone hemisuccinate		Fluocortolone acetate
Prednicarbate		Fluprednidene acetate
Prednisolone		Halomethasone
Prednisolone caproate		Meprednisone
Prednisolone pivalate		Fluticasone propionate
Prednisolone sodium metasulfobenzoate		Momethasone furoate
Prednisolone succinate		
Prednisone		
Tixocortol pivalate		

over, there may be signs indicating chronic corticosteroid use, such as skin atrophy, rosacea, perioral and paranasal dermatitis.<sup>1,5</sup>


In 1989, Coopman et al. categorized topical corticosteroids into four groups: A (hydrocortisone type), B (acetonide type), C (non-esterified betamethasone type), and D (esters, subdivided into D1-stable and D2-labile). In 2011, Baeck et al. proposed another classification system based on methylation patterns and allergenic profiles derived from patch tests, dividing them into three groups (Table 1). Group 1 corticosteroids more frequently result in allergic reactions, while those in Group 3 have the least sensitizing power and risk of cross-reactions. However, it is important to emphasize that the same patient may manifest hypersensitivity to more than one group.<sup>1,6-8</sup>

The patch test is the gold standard diagnostic tool and should be performed to confirm the suspicion and individualize the therapeutic approach, which can range from the substitution of the corticosteroid by another that belongs to a different group to complete withdrawal of this pharmacological class.<sup>1,5</sup>

Studies have shown that tixocortol pivalate, budesonide, and hydrocortisone 17-butyrate are the corticosteroids most likely to cause ACD.<sup>2</sup> This is probably due to the greater capacity of these molecules to bind to the arginine in serum

proteins, forming an antigen.<sup>1</sup> These markers identify the majority of patients with ACD to corticosteroids; however, since they all belong to Group 1, patients who are allergic to the other groups may go unnoticed. Therefore, in patients who are positive for any of these markers and in those with high clinical suspicion, the ideal action is to expand the patch test study by using a specific series of corticosteroids containing drugs from all groups.

Patients with ACD to corticosteroids diagnosed in the service where the present study was carried out were tested with the Latin American supplementary battery (Chemotechnique), which contains hydrocortisone 17-butyrate, budesonide, and tixocortol pivalate, in addition to the standard Brazilian battery (FDA Allergenic). Among them, one (16.7%) was positive only for tixocortol pivalate (Fig. 3), three (50%) were positive for budesonide, and the other two (33.3%) were positive for both budesonide and tixocortol. The use of the supplementary battery in the patch tests was essential to allow the diagnosis to be attained since there are no corticosteroid markers in the standard battery. In all cases, it was recommended to withdraw contact with corticosteroids from Group 1. Although the ideal approach would be to perform a new test with a specific battery of corticosteroids, it was not possible in these cases. In one of the patients with dissem-



**Figure 3** Positive patch test for tixocortol pivalate.

inated lesions, methotrexate and phototherapy were used. The others showed a good response with the change of medication to Group 3 corticosteroids, such as fluticasone propionate and betamethasone valerate.

Moreover, five (83.3%) of the patients were polysensitized; that is, they had three or more positive reactions to unrelated allergens. These allergens were components of topical medications (neomycin, bacitracin, benzocaine, promethazine), additives (Kathon CG®, formaldehyde, thimerosal), rubber components (thiuram and carba-mix), and metals (nickel sulfate, cobalt chloride), data compatible with the literature, as these are individuals with chronic dermatoses, who have a breach in the skin barrier, and are sensitized to multiple components of medications, emollients, and other contact agents.<sup>1,9,10</sup>

There are also other elements present in topical medications (in addition to the active ingredient) that can act as allergens, such as stabilizers (e.g., ethylenediamine), vehicles (e.g., propylene glycol), and fragrances, further reinforcing the importance of patch tests.

Therefore, ACD to corticosteroids should be considered as a hypothesis in the presence of recurrent conditions, with no response to corticosteroid treatment. Patch tests should be indicated in these cases, aiming at the removal of the causal agent and the early introduction of adequate treatment.

### Financial support

None declared.

### Authors' contributions

Mariana de Figueiredo Silva Hafner: Design and planning of the study; drafting and editing of the manuscript; collection,

analysis, and interpretation of data; effective participation in research orientation; intellectual participation in the propaedeutic and/or therapeutic conduct of the studied cases; critical review of the literature; critical review of the manuscript; approval of the final version of the manuscript.

Amanda Ivanchuk Lopes: Drafting and editing of the manuscript; collection, analysis, and interpretation of data; approval of the final version of the manuscript.

Nathalie Mie Suzuki: Effective participation in research orientation; intellectual participation in the propaedeutic and/or therapeutic conduct of the studied cases; critical review of the literature; critical review of the manuscript; approval of the final version of the manuscript.

Rosana Lazzarini: Design and planning of the study; drafting and editing of the manuscript; collection, analysis, and interpretation of data; effective participation in research orientation; intellectual participation in the propaedeutic and/or therapeutic conduct of the studied cases; critical review of the literature; critical review of the manuscript; approval of the final version of the manuscript.

### Conflicts of interest

None declared.

### References

- Berbegal L, DeLeon FJ, Silvestre JF. Hypersensitivity reactions to corticosteroids. *Actas Dermosifiliogr.* 2016;107:107–15.
- Brar KK, Leung DYM. Eczema complicated by allergic contact dermatitis to topical medications and excipients. *Ann Allergy Asthma Immunol.* 2018;120:599–602.
- Otani IM, Banerji A. Immediate and delayed hypersensitivity reactions to corticosteroids: evaluation and management. *Curr Allergy Asthma Rep.* 2016;16:18.
- Baeck M, Soria A, Marot L, Theate I, Hendrickx E, Belle A, et al. Characterization of the T cell response in allergic contact dermatitis caused by corticosteroids. *Contact Dermatitis.* 2013;68:357–68.
- Baeck M, Goossens A. Immediate and delayed allergic hypersensitivity to corticosteroids: practical guidelines. *Contact Dermatitis.* 2012;66:38–45.
- Coopman S, Degreef H, Dooms-Goossens A. Identification of cross-reaction patterns in allergic contact dermatitis from topical corticosteroids. *Br J Dermatol.* 1989;121:27–34.
- Baeck M, Chemelle JA, Goossens A, Nicolas JF, Terreux R. Corticosteroid cross-reactivity: clinical and molecular modelling tools. *Allergy.* 2011;66:1367–74.
- Pratt MD, Mufti A, Lipson J, Warshaw EM, Maibach HI, Taylor JS, et al. Patch test reactions to corticosteroids: retrospective analysis from the North American Contact Dermatitis Group 2007-2014. *Dermatitis.* 2017;28:58–63.
- Baeck M, Goossens A. Systemic contact dermatitis to corticosteroids. *Allergy.* 2012;67:1580–5.

10. Baeck M, Chemelle JA, Terreux R, Drieghe J, Goossens A. Delayed hypersensitivity to corticosteroids in a series of 315 patients: clinical data and patch test results. *Contact Dermatitis*. 2009;61:163–75.

Mariana de Figueiredo Silva Hafner <sup>a,\*</sup>,  
Amanda Ivanchuk Lopes <sup>b</sup>, Nathalie Mie Suzuki <sup>a</sup>,  
Rosana Lazzarini <sup>a</sup>

<sup>a</sup> *Clínica de Dermatologia da Santa Casa de São Paulo, São Paulo, SP, Brazil*

<sup>b</sup> *Faculdade de Ciências Médicas da Santa Casa de São Paulo, São Paulo, SP, Brazil*

\* Corresponding author.

E-mail: [mariana@hafner.med.br](mailto:mariana@hafner.med.br) (M.F. Hafner).

Received 15 August 2020; accepted 5 December 2020

Available online 17 March 2022

<https://doi.org/10.1016/j.abd.2020.12.012>  
0365-0596/ © 2022 Published by Elsevier España, S.L.U. on behalf of Sociedade Brasileira de Dermatologia. This is an open access article under the CC BY license (<http://creativecommons.org/licenses/by/4.0/>).

## Concordance analysis of dermoscopic features between five observers in a sample of 200 dermoscopic images<sup>☆</sup>



Dear Editor,

Dermoscopy is a non-invasive technique that has been proven in recent metanalysis to increase the accuracy in the diagnosis of cutaneous melanoma compared to the naked eye examination. However, its application can be considered subjective and too observer-dependent, with a heavy influence by previous experience. To this date, few reproducibility studies focusing on interobserver agreement of dermoscopic images have been published. Most of them are based on the evaluation of <50 cases by each observer.<sup>1–3</sup> Furthermore, since the Internet Consensus Meeting of 40 dermoscopy experts in 2003, a few novel dermoscopic features have been described that were not evaluated.<sup>1</sup>

The aim of this project was to analyze and determine the reproducibility of the analysis of both classic and novel dermoscopic features for the diagnosis of melanoma in 200 dermoscopic images by five blinded observers (E.H.T., L.N.B, JAAI, BLM, ERL). Previous experience on dermoscopy was >10 years (1 observer), >5 years (2 observers), and <5 years (2 observers).

A retrospective evaluation of dermoscopic images collected from the database of the Melanoma Unit in our department was performed. Images were obtained using a digital polarized dermoscopy system (Dermlite Photo II Pro HR<sup>®</sup> [3Gen<sup>®</sup>, San Juan Capistrano, CA, USA] and an Olympus E-420<sup>®</sup> camera [Olympus, Tokyo, Japan]). Lesion diameter had to fit in the picture to be included. Cases without histopathological confirmation, melanoma metastases, or melanomas of special sites (facial, acral, nail, genital, or mucosal melanoma) were excluded. The distribution of diagnosis in our sample is shown in [Table 1](#).

The following dermoscopic features were analyzed: colors (light brown, dark brown, black, blue/gray, red/pink, white), asymmetry of color/structures, atypical, pigmented network, irregular globules, streaks, irregular blotches, shiny white streaks, negative pigment o brown areas,

blue-black pigmentation, milky-red areas, rainbow pattern, pseudolacunae, ulceration, and irregular vessels. Data were analyzed using SPSS version 22.0 (Chicago, IL, USA). Inter-observer agreement between the five dermoscopists was evaluated using the Fleiss' Kappa statistic test.

The results of the concordance analysis are shown in [Table 2](#). Most of the dermoscopic features ranged Kappa values between 0.3–0.5, which can be considered fair to moderate. Asymmetry of color and structures (yes/no) showed a moderate agreement (0.46–0.49), slightly higher than the same evaluation considering one or two axes. The presence of more than three colors presented the moderate agreement as well (0.46). The melanoma-specific structures that showed more consistency were the shiny white streaks (up to 0.55), while structureless brown areas had the worst results (0.05). A few features that have been recently described, such as prominent skin markings and blue-black pigmentation, showed a very poor correlation (0.23 and 0.18, respectively) between all observers.

Previous studies have determined that features regarding the overall organization, colors, and symmetries have a higher agreement and discriminatory power than many well-known diagnostic structures such as atypical pigment networks or irregular blotches.<sup>1–3</sup> Recent dermoscopic algorithms, such as CASH and TADA algorithms, are based on this idea.<sup>4,5</sup> This finding has been confirmed in our concordance analysis and supports this approach. On the other hand, the low values observed in novel features such as prominent

**Table 1** Distribution of diagnosis in the 200 cases for evaluation.

Diagnosis	n	%
Melanoma	99	49.5
Melanocytic nevus	45	22.5
Melanocytic nevus with histopathological atypia	22	11.0
Blue nevus	5	2.5
Spitz nevus	4	2.0
Basal cell carcinoma	14	7.0
Seborrheic keratosis	5	2.5
Dermatofibroma	2	1.0
Squamous cell carcinoma	2	1.0
Other neoplasms	2	1.0
<b>Total</b>	<b>200</b>	<b>100</b>

<sup>☆</sup> Study was conducted using data from patients obtained from the Melanoma Unit of the Hospital General Universitario Gregorio Marañón, Madrid, Spain.