

alent alterations, that is, symptoms immediately after the procedure, cataracts in the shape of spicules and difficult-to-control glaucoma. It is noteworthy that the patient had already undergone the same procedure before, with an older device, without complications.

Due to these significant adverse effects, the Brazilian Society of Glaucoma sent a letter in November 2019 to the Brazilian Society of Dermatology, issuing the necessary warning and highlighting the peculiar finding of a "spiky" cataract. It is important to emphasize that ophthalmological complaints after dermatological procedures should be evaluated by an ophthalmologist.^{4,5}

The authors consider this communication to be opportune because it serves as a warning to colleagues, who must be very attentive to the use of new technologies. In the present case, specifically, the possible severe ophthalmological complications related to the use of MU.⁵

Financial support

None declared.

Authors' contributions

Mariana Marques Rechuan: Drafting and editing of the manuscript.

Jordana Cezar Vaz: Drafting and editing of the manuscript.

Fernanda de Azevedo Pereira Marques: Drafting and editing of the manuscript.




David Rubem Azulay: Drafting and editing of the manuscript; critical review of the manuscript.

Conflicts of interest

None declared.

References

1. Shome D, Vadera S, Ram S, Khare S, Kapoor R. Use of micro-focused ultrasound for skin tightening of mid and lower face. *Plas Reconstr Surg Glob Open*. 2019;7:2498.
2. Gutowski K. Microfocused ultrasound for skin tightening. *Clin Plastic Surg*. 2016;43:577–82.
3. Friedmann D, Bourgeois G, Chan HL, Zedlitz AC, Butterwick KJ. Complications from microfocused transcutaneous ultrasound: case series and review of the literature. *Lasers Surg Med*. 2018;50:13–9.
4. Delbarre M, Froussart-Maille F. Signs, symptoms, and clinical forms of cataract in adults. *J Fr Ophtalmol*. 2020;43:653–9.
5. Jonas J, Aung T, Bourne R, Bron A, Ritch R, Panda-Jonas S, et al. Glaucoma. *Lancet*. 2017;390:2183–93.

Mariana Marques Rechuan , Jordana Cezar Vaz ,
Fernanda de Azevedo Pereira Marques ,
David Rubem Azulay 

Instituto de Dermatologia Professor Rubem David Azulay, Santa Casa da Misericórdia do Rio de Janeiro, Rio de Janeiro, RJ, Brazil

* Corresponding author.

E-mail: mrechuan@gmail.com (M.M. Rechuan).

Received 9 August 2021; accepted 13 December 2021

Available online 23 June 2023

<https://doi.org/10.1016/j.abd.2021.12.013>

0365-0596/ © 2023 Sociedade Brasileira de Dermatologia.

Published by Elsevier España, S.L.U. This is an open access article under the CC BY license (<http://creativecommons.org/licenses/by/4.0/>).

Proliferating trichilemmal tumor[☆]



Dear Editor,

Proliferating trichilemmal tumor (PTT) is a rare adnexal neoplasm^{1,2} derived from the outer sheath of the hair follicle and may originate from a pre-existing pilar/trichilemmal cyst as a result of trauma and/or inflammation in the latter.^{1,3} It was first reported in 1966 by Wilson Jones^{2,4,5} and it is benign in most cases^{3,4} but eventually it can be malignant, recur locally, invade adjacent tissues and cause distant metastases.^{1,3–5} It often presents as a solitary, soft nodular lesion, measuring 1 to 10 cm in diameter, on the scalp of elderly women.^{1,3} and may be associated with an area of alopecia. More rarely, it can affect other topographies such

as the neck, trunk, groin, mons pubis, vulva, gluteal region, and skull base.^{1,3}

This report describes the case of a 52-year-old male patient, with no comorbidities, who sought medical care complaining of a lesion on the scalp, with discomfort on palpation, that had been growing for about a year. He had a personal history of scalp cyst removal years before. On clinical examination, a tumor-like, erythematous lesion with a pedunculated structure in the center, measuring approximately 3 cm in its largest diameter, was observed in the parieto-occipital region (Fig. 1). The main hypothesis was trichilemmal cyst with atypical clinical presentation and, for this reason, an incisional spindle biopsy was performed, measuring about 2 cm in its largest diameter for anatomopathological analysis. Histopathology showed a dermal tumor, with no connection with the epidermis, consisting of an expansive lobular proliferation of squamous cells with ample eosinophilic cytoplasm and abrupt keratinization, without the formation of a granular layer - trichilemmal-type keratinization – in the central portion of the lobes (Fig. 2). Some of these cells had atypical nuclei, but no

[☆] Study conducted at the Private Practice, Porto Alegre, RS, Brazil.

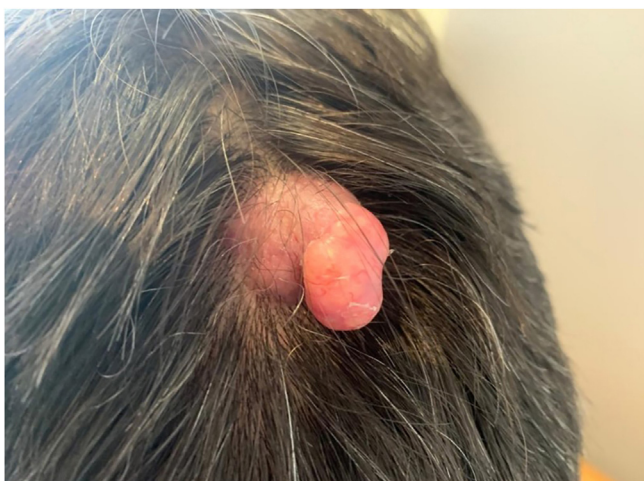

Figure 1 Tumor in the parieto-occipital region

mitosis (Fig. 3), findings consistent with a proliferating trichilemmal tumor. The patient was referred for complete excision of the lesion and showed good evolution, with no signs of recurrence to date.

The anatomopathological analysis is crucial for the diagnosis of PTT, because clinically, as in the case reported herein, it can be mistaken for a trichilemmal cyst, or other adnexal tumors.¹ What histopathologically characterizes this tumor is the proliferation of squamous cells with trichilemmal keratinization (defined by the abrupt transition from nucleated to anucleated epithelial cells, with the absence of a granular layer) and varying degrees of atypia.¹⁻³ The presence of poorly-defined borders, high-grade atypia, aneuploidy, necrosis, cellular pleomorphism and atypical mitoses are related to malignancy (malignant proliferating trichilemmal tumor) and, in this

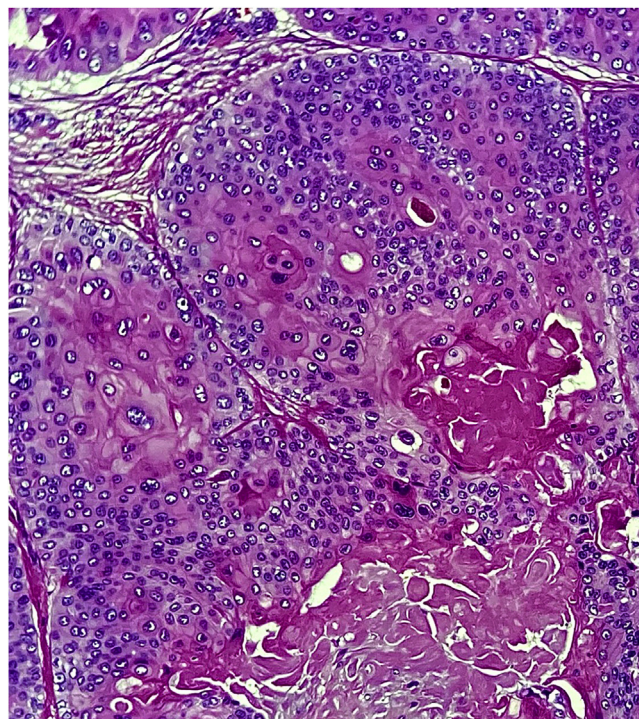


Figure 3 Squamous cells with atypical nuclei, but without mitosis. Towards the central part of the tumor island there is abrupt keratinization of the trichilemmal type (Hematoxylin & eosin, ×400)

case, distant metastases may rarely appear, even years after the excision of the primary tumor.^{1,3,5} Immunohistochemistry can be used to help in the detection of malignancy.^{1,2}

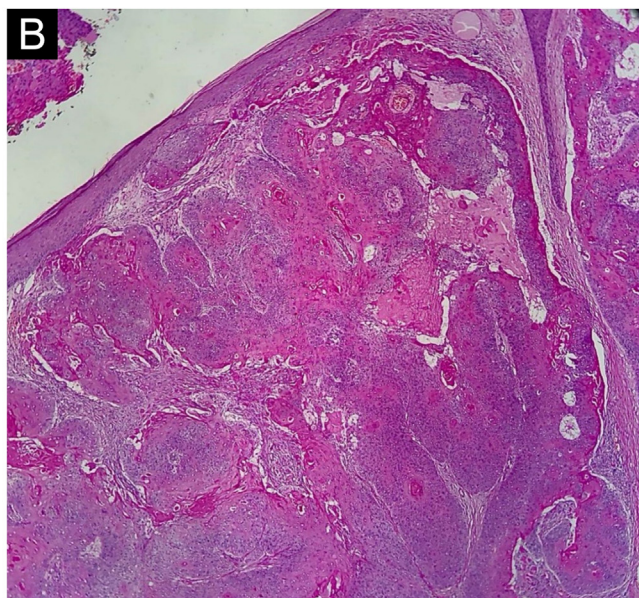
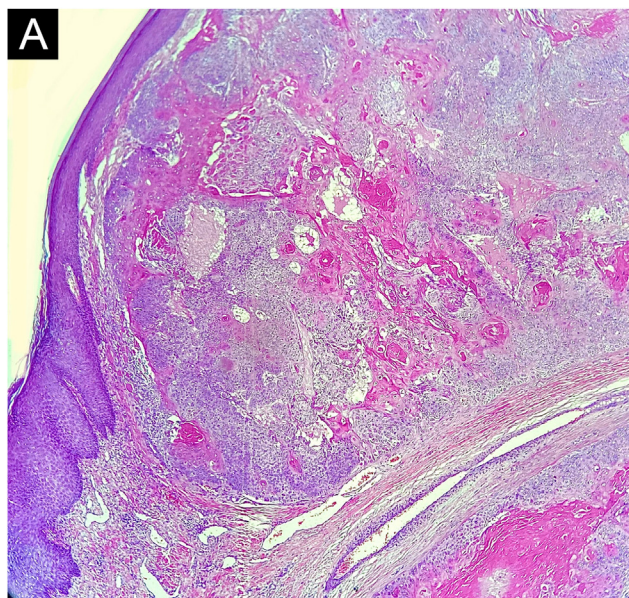


Figure 2 (A and B) Proliferation of lobular squamous tumor islands in the dermis, without connection with the epidermis. There is trichilemmal-type keratinization, consisting of compact and eosinophilic keratin in the center, in two distinct areas (Hematoxylin & eosin, ×40)

Treatment consists of surgical excision, with margins ranging from 1 cm to large resections, depending on the histopathology of the tumor.^{1,3} Radiotherapy and chemotherapy have been described as alternative or adjuvant treatments.^{1,3} To reduce the risk of recurrence, the evaluation of the margins with Mohs micrographic surgery is the procedure of choice,^{1,3,4} as well as the close follow-up of these patients.^{1,3}

Financial support

None declared.

Authors' contributions

Andrea Abê Pereira: Critical review of the literature; drafting and editing of the manuscript; approval of the final version of the manuscript; design and planning of the study.

Jéssica Lüders Bueno: Critical review of the literature; approval of the final version of the manuscript; design and planning of the study; drafting and editing of the manuscript.

Ana Leticia Boff: Drafting and editing of the manuscript; collection, analysis and interpretation of data; critical review of the manuscript.

Paulo Ricardo Martins Souza: Approval of the final version of the manuscript; design and planning of the study; drafting and editing of the manuscript; collection, analysis and interpretation of data; intellectual participation in the propaedeutic and/or therapeutic conduct of the studied cases; critical review of the literature; critical review of the manuscript.

Conflicts of interest

None declared.

References

1. Satyaprakash AK, Sheehan DJ, Sangüeza OP. Proliferating trichilemmal tumors: a review of the literature. *Dermatol Surg.* 2007;33:1102–8.
2. Peryassu MA, Peryassu BC, Peryassu RC, Piñeiro-Maceira J, Ramos-E-Silva M. Proliferating trichilemmal tumor: a case on the nose of a 70-year-old man. *Case Rep Dermatol.* 2013;5:248–53.
3. Tierney E, Ochoa MT, Rudkin G, Soriano TT. Mohs' micrographic surgery of a proliferating trichilemmal tumor in a young black man. *Dermatol Surg.* 2005;31:359–63.
4. Sharma R, Verma P, Yadav P, Sharma S. Proliferating trichilemmal tumor of scalp: benign or malignant, a dilemma. *J Cutan Aesthet Surg.* 2012;5:213–5.
5. Park BS, Yang SG, Cho KH. Malignant proliferating trichilemmal tumor showing distant metastases. *Am J Dermatopathol.* 1997;19:536–9.

Andrea Abê Pereira ^{a,b,*}, Jéssica Lüders Bueno ^{a,b}, Ana Leticia Boff ^{a,b}, Paulo Ricardo Martins Souza ^{a,b}

^a *Department of Dermatology, Universidade Federal de Ciências da Saúde de Porto Alegre, Porto Alegre, RS, Brazil*

^b *Department of Dermatology, Santa Casa de Misericórdia de Porto Alegre, Porto Alegre, RS, Brazil*

* Corresponding author.

E-mail: andrea.abetm@gmail.com (A.A. Pereira).

Received 16 September 2021; accepted 11 November 2021
Available online 3 August 2023

<https://doi.org/10.1016/j.abd.2021.11.015>

0365-0596/ © 2023 Published by Elsevier España, S.L.U. on behalf of Sociedade Brasileira de Dermatologia. This is an open access article under the CC BY license (<http://creativecommons.org/licenses/by/4.0/>).

Recurrence of psoriasis on the resolution sites left with lentiginous pigmented patches after TNF inhibitor therapy[☆]



Dear Editor,

To date, several cases of multiple lentiginous in resolved psoriasis lesions have been reported. Herein, we describe a rare case of psoriasis that resolved leaving multiple small lentiginous patches in the lesions after successful treatment with a Tumor Necrosis Factor (TNF) inhibitor. Moreover, a recurrence of psoriasis was observed in the pigmentary patches.

A 55-year-old male was diagnosed with psoriasis vulgaris 6 years previously and had been treated with topical corticosteroid ointment. Joint pain appeared on the bilateral fingers, wrists, and ankles 3 years previously, and he

received systemic therapy with adalimumab (subcutaneous injection of 80 mg, and 40 mg thereafter every other week). Both cutaneous and joint manifestations responded well to adalimumab. Psoriasis Activity and Severity Index (PASI) score was reduced from 6.0 to 0 (PASI clear), and also, he was relieved from joint pain. After the complete disappearance of psoriasis, pigmentation emerged. However, during maintenance therapy with adalimumab, cutaneous psoriasis relapsed 7 months later, but without recurrence of joint pain. Physical examination showed multiple brownish plaques on the lower extremities. A few psoriatic plaques were observed in some, but not all, of the resolved lesions (Fig. 1A–C). In one of the lesions, psoriatic lesions appeared within the pigmented macule and spread beyond the pigmented macule (Fig. 1C).

There are several cases of psoriatic plaques that were treated with biologics such as TNF inhibitors, Interleukin-17 (IL-17) inhibitors, IL-12/23 inhibitors, T-cell inhibitors, and phosphodiesterase 4 inhibitors, and left lentiginous lesions in the resolved area.^{1–4} Previous studies have shown that inflammatory cytokines such as TNF- α and IL-17 can

[☆] Study conducted at the Fukushima Medical University, Fukushima, Japan.