

*Accidents caused by lepidopterans (moth larvae and adult): study on the epidemiological, clinical and therapeutic aspects**

Acidentes por Lepidópteros (larvas e adultos de mariposas): estudo dos aspectos epidemiológicos, clínicos e terapêuticos*

Alberto Eduardo Cox Cardoso¹

Vidal Haddad Junior²

Abstract: The authors present and discuss some aspects of injuries caused by larvae of Lepidoptera (moths), emphasizing the skin manifestations and intense pain that characterize these conditions. Moreover, they present moth larvae that cause extracutaneous manifestations, such as severe coagulation disorders and ankylosing arthropathies, and dermatitis related to adult insects. The main groups of Lepidoptera that cause injuries in humans are presented as well as current therapeutic alternatives. Lepidopterism and erucism are common accidents and it is important that dermatologists be aware and able to recognize and treat this kind of poisoning.

Keywords: Venomous animals; Envenomation; Lepidoptera; Moths; Insect bites and stings

Resumo: Os autores apresentam e discutem aspectos dos acidentes causados por larvas de lepidópteros (mariposas), enfatizando as manifestações dermatológicas e a dor intensa que caracterizam estes agravos. Além disso, são apresentadas larvas de mariposas que causam manifestações extracutâneas, tais como severos distúrbios de coagulação e artropatias anquilosantes, e ainda dermatites provocadas por insetos adultos. Os principais grupos de lepidópteros causadores de acidentes em humanos são demonstrados, e as medidas terapêuticas atualizadas são discutidas. O lepidopterismo e o erucismo são acidentes comuns, e é importante que o dermatologista saiba reconhecer e tratar esse tipo de envenenamento.

Palavras-chave: Animais venenosos; Envenenamento; Lepidópteros; Mariposa; Mordeduras e picadas de insetos

INTRODUCTION

There are not many studies in the Brazilian literature on accidents caused by lepidopterans (butterflies and moths), although they are common and result in diverse clinical pictures. From the medical point of view, it is important to study lepidopterans due to skin lesions caused by two mechanisms - contact with irritating hairs or setae of some caterpillars and, more rarely, the action of body setae of adult moths.¹⁻¹¹

Most lepidopterans are not harmful to humans.

Butterflies and moths play an essential role in flower pollination. The caterpillars, which are larvae, on turn, when feeding can cause damage to crops, but fertilize the soil with their feces. Some have commercial importance, such as the silkworm (*Bombix mori*).

The Lepidoptera order comprises two suborders: Rhopalocera, with adult specimens that fly during daytime and are called butterflies, and Heterocera, with nocturnal activities and called

Received on July 25, 2005.

Approved by the Editorial Council and accepted for publication on October 30, 2005.

* Work done at Dermatology Services of Hospital Universitário Professor Alberto Antunes, Universidade Federal de Alagoas and Hospital Universitário da Faculdade de Medicina de Botucatu, Universidade Estadual Paulista - São Paulo (SP), Brazil.

¹ Adjunct Professor IV of Centro de Ciências da Saúde da Universidade Federal de Alagoas (UFAL), Titular Professor of Escola de Ciências Médicas de Alagoas - (UNCISAL) - (AL), Brazil.

² PhD Assistant Professor of Faculdade de Medicina de Botucatu - Universidade Estadual Paulista (Unesp) - São Paulo (SP), Brazil.

moths. In Brazil there are approximately 50,000 species of lepidopterans. Their development phases are egg, larva or caterpillar, pupa or chrysalis and adult (imago); in other words, they present a complete or holometabolic evolution.^{2,5,9}

HISTORY

There are reports of dermatological lesions after contact with irritating caterpillars since Ancient Greece. During the Roman Empire, Pliny the Elder and Galen wrote about the irritating properties of lepidopterans.^{1,2} In the American continent, the first reports were made by priest José de Anchieta in his "Letters from São Vicente" (1569), in which the Jesuit reports some manifestations and habits of Brazilian Indians, which included rubbing caterpillars on the penis to cause edema and help during sexual intercourse.⁷

Marcgrave and Piso, the fathers of Natural History in Brazil, recorded cases of accidents with caterpillars in the Northeastern region, in 1658.⁷ In 1918, in the French Guiana, Leger and Mouzels¹² described the first cases of dermatitis caused by moth hair of the *Hylesia* genus, and their studies were continued by Boyé, in 1932.¹³ In Brazil, the first outbreak was described by Gusmão et al. (1960)¹⁴ in the current State of Amapá. Martins and Machado, in the 1940's, drew attention to accidents with pararama, a caterpillar that causes destructive arthritis on the hands of rubber latex tappers working in the Amazon region.^{1,10,11}

CLINICAL ASPECTS

Lepidopterism

The word Lepidoptera, from Greek *lepis*, *idos* and *ptera*, means scaly wing. The accidents caused by contact with the winged adult forms of moths are called lepidopterism. In the Anglo-Saxon literature, the term is also used for accidents caused by contact with larvae. Dermatoses caused by contact with winged specimens are rare and the literature on the subject is scarce.^{5,8,10,11}

There are descriptions from several South and Central American countries of accidents caused by contact with the setae existing in the abdomen of females from certain species of the *Hylesia* genus, Hemileucidae family.¹⁵⁻¹⁹ These moths cause epidemic outbreaks in rural areas during the hot and rainy months, when they fly and hit against light sources. Only female moths cause the disease (Figure 1).

Similar cases were described in Central Africa, caused by species from the *Anaphae* genus. There is a controversy regarding abdominal spicules containing venom in their interior. The simple fact of the seta penetrating seems to be cause intense popular, pruritic



FIGURE 1: A female *Hylesia* sp moth responsible for accidents in humans

inflammatory reactions, similar to those observed in accidents caused by tarantulas (Figure 2). These setae are easily detached from the moth's body and float in "clouds" in environments in which they are present, usually camps or summer homes, where they can even fall over clothes and cause accidents.^{10,11,18,19}

ERUCISM

This is a more serious and common accident, mainly associated with three families of moths: Megalopygidae, Saturnidae and Arctiidae. Eruca means larva. The most important genera of the Megalopygidae family are *Podalia* and *Megalopyge* (Figure 3). The Saturnidae family includes caterpillars that have less setae than those from the Megalopygidae family, whose aspect is similar to small pine

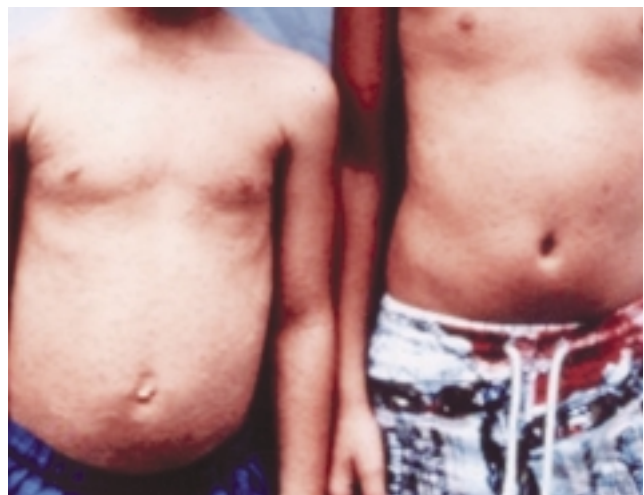

FIGURE 2: Two patients with pruritic, erythematous and papular eruptions after sleeping in a rural setting with moths of the *Hylesia* genus

trees, a characteristic and decisive factor to identify the family. The important genera are: *Automeris* (Figure 4), *Dirphia* and *Lonomia*.

According to a survey conducted at Hospital Vital Brasil (Instituto Butantã), in São Paulo, from 1975 to 1979, there were 568 cases of accidents caused by contact with caterpillars. Although subnotified, this kind of injury is undoubtedly the most common accident caused by venomous animals in the country. In 52 accidents, it was possible to identify the causing agent: Megalopygidae family: 14; *Megalopyge* sp: 11, *Megalopyge albicollis*: 9; *Megalopyge lanata*: 8, *Podalia* sp: 3; *Automeris* sp (Saturnidae family): 2; *Automeris aurantica*: one; *Automeris illustres*: one; *Dirphia multicolor*: 2; *Papilionidae* family: one.¹¹ The accidents were more common with children.¹¹

The caterpillar setae act as a biological defense mechanism against natural predators; the contact with humans occurs by accident due to professional reasons. The shape of the hairs or setae enables recognizing the two main moths families involved in accidents: the Megalopigidae family presents thin and plentiful setae throughout the whole body, whereas the Saturnidae family presents less setae, shaped as small pine trees (Figures 3, 4 and 6).

The urticating properties are due to hollow hairs that contain an urticating liquid secreted by cells located at their base and called trichogen cells. When the seta penetrates the skin and breaks, the irritating liquid performs its action.^{1,2,10,11}

In general, toxins from all species contain thermolabile proteins. Some species have proteolytic enzymes, others are plasminogen activators and have



FIGURE 4: Caterpillar of a moth of the *Automeris* genus (*Saturnidae* family). Observe the body spicules similar to small pine trees.

activities similar to that of trypsin and chymotrypsin.¹¹ Valle et al.²⁰ demonstrated the presence of histamine in the secretion of some genera: *Dirphia* and, in minimal quantities, *Megalopyge*. Recent studies with several species of *Euproctis*, conducted in the United States, Europe and Asia showed a serine esterase similar to the kallikrein found in the setae. These compounds would activate the kinin sequence.³ These findings demonstrate there is not a single toxin.

The accidents are characterized by immediate intense pain, erythema, edema, vesicles, blisters, erosions, petechias, superficial cutaneous necrosis, ulcerations and lymphangitis (Figures 3, 5 and 6).



FIGURE 3: Above: Caterpillar of a moth of the *Megalopyge* genus (*Megalopygidae* family). Below: recent accident. Observe slight erythema and edema, which are not compatible with the intense pain reported by the victim

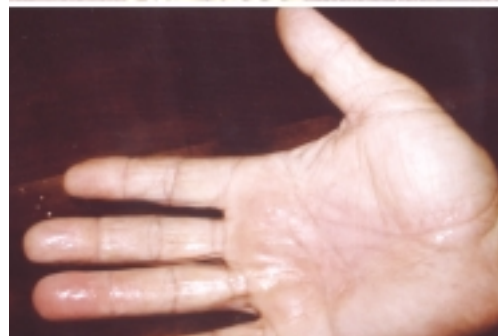
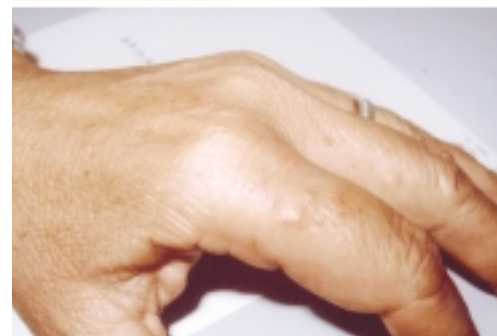

FIGURE 5: Recent accident in the hand of a child who handled the caterpillar shown in the previous image. The erythema is evident, but there is little edema, and the lesion is extremely painful



Eye involvement may lead to conjunctivitis, keratitis and iridocyclitis.^{1,2,10,11} Sensitization may cause rhinitis and asthma. In rare occasions the contacts may result in more serious problems, such as arrhythmias, chest pain, dyspnea, hemorrhagic disorders, peripheral neuropathies, shock, limb paralysis and seizures.^{10,11} The main signs and symptoms in 90% of envenomations are intense pain and local edema and erythema, which are not proportional to the observed pain.

The histopathological aspects of induced or natural dermatitis consist of spongiosis, hydropic degeneration, upper dermis edema and lymphocytic and plasma cell infiltrate.^{3,21} (Figure 7).

HEMORRHAGIC SYNDROMES CAUSED BY CONTACT WITH CATERPILLARS

In Brazil there are reports of serious hemorrhagic accidents caused by contact with caterpillars of the *Lonomia* genus, which are parasites in rubber trees (*Hevea Braziliensis*). The venomous species are *Lonomia achelous*, a parasite in rubber trees in the State of Amapá and in Marajó Island, and *Lonomia obliqua*, a parasite found in fruit trees such as peach, avocado and plum trees in the States of Rio Grande do Sul, Santa Catarina and Paraná,^{10,11} and throughout the Southeastern region (Figure 8). Rural workers are the main victims of this injury. In the States above-mentioned, the caterpillar is responsible for serial injuries, but isolated accidents can occur in any State from the Southeastern and Southern regions.

The *Lonomia* genus was identified as responsible for hemorrhagic events, in Venezuela in the

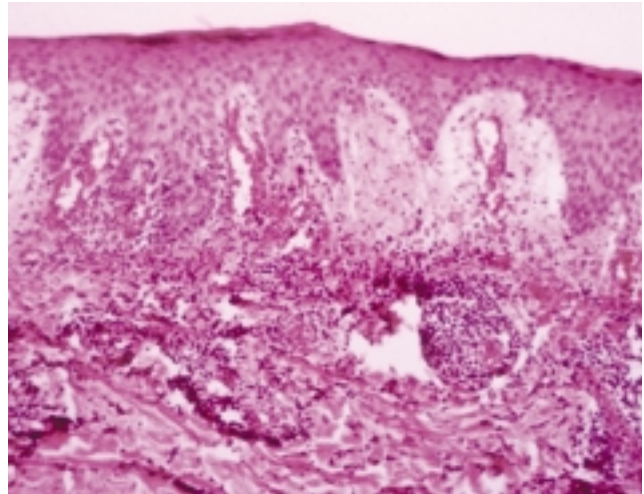


FIGURE 7: Caterpillar of the *Lonomia* genus (*Lonomia obliqua*), responsible for severe hemorrhagic events in humans. Below: a patient with significant ecchymosis after contact with an army of caterpillars

1960's. As of 1989, however, accidents caused by *Lonomia obliqua* have taken up epidemic proportions in the western part of the State of Santa Catarina, the northern part of the State of Rio Grande do Sul, especially in regions near the cities of Chapecó and Passo Fundo, respectively. There has been an increased number of cases, even in the States of Paraná and São Paulo.²²⁻²⁶ The areas where the caterpillar exists present temperate climate with annual average temperature of 63.5°F (17.5°C). It is likely that deforestation and ecological changes have contributed to a raise in accident rates.

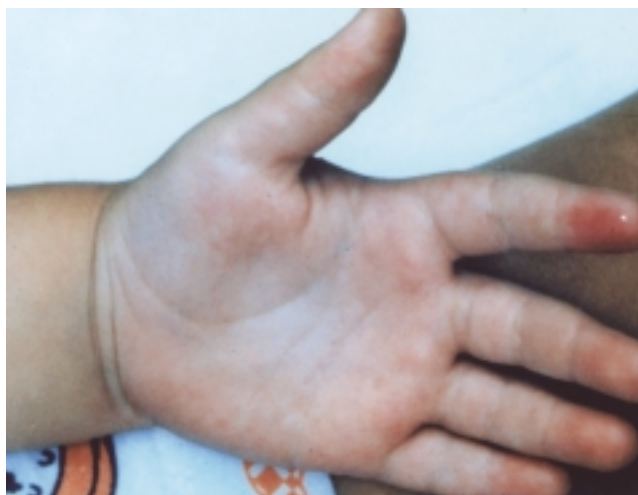

FIGURE 6: Details of arboriform spicules of a caterpillar of the *Saturniidae* family. Below: Accident on the hand of a patient with erythematous papules and discreet superficial cutaneous necrosis

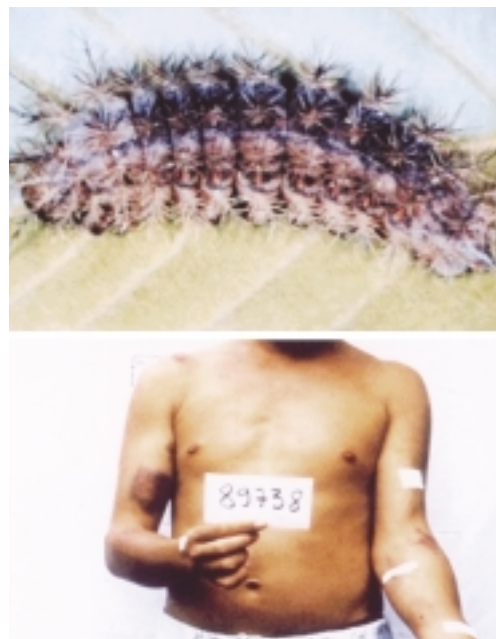

FIGURE 8: histopathological examination of skin after contact with a caterpillar. There is an intense and urticari-form edema in the dermis and local mononuclear infiltrate

The pathophysiology of envenomation by *Lomomia* is still not completely clear. Depending on the toxin chemical composition, which seems to change according to larva age, primary or secondary fibrinolysis may occur, and severity of disease varies according to intensity of the contact. Patients may present ecchymosis to intense hemorrhage, shock and acute renal failure (Figure 8). Death may occur due to intracerebral bleeding and these patients have altered hemostasis. The venom of *Lonomia achelous* causes intense fibrinolytic action and a picture similar to that of disseminated intravascular coagulation, which produces very low levels of fibrinogen, plasminogen and other coagulation factors. A dose-dependent pro-coagulant action was verified *in vitro* studies with *L. obliqua* venom. It is potentiated by calcium, which would trigger thrombin formation by activating coagulation factors. The complement system is also activated. In addition to the action of these substances, the participation of inflammatory mediators would justify the alterations that occur in human envenomation.²²⁻²⁶

In 29 cases observed in the Northern region of Brazil, from 1978 to 1982, over 38% were lethal; and in the 60 cases studied in the Southern region, from 1989 to 1991, four were fatal.

PARARAMA

Pararama is the common name in Brazil of an urticating caterpillar found in artificial rubber tree plantations in the State of Pará. It is the larval stage of the moth *Premolis semirufa*. The accidental contact with the caterpillar small hairs or with one of the cocoon setae causes a chronic inflammatory reaction in the interphalangeal joints resulting in ankylosis.²⁷⁻³⁰ The morbid condition specially affects rubber tappers and is therefore considered an occupational disease.

According to Dias,²⁷⁻³⁰ in Belterra, 72.7% of accidents were observed on the right hand, 51.7% affected the middle finger, and 62% were located on the third joint. Rodrigues described 73.60% of injuries affecting the right hand and 43.31% the middle finger. The explanation for this event relates to the fact that rubber tappers, when collecting the coagulated latex in containers, use their fingers to help extraction and come into contact with the setae left by the caterpillars.⁹ Contact with the pararama larvae also results in erythema, edema and pruritus on the affected site, and the symptoms resolve within hours or days.²⁹

In a histopathological study of a biopsy of periarticular and sinovial tissue from a chronic lesion, it was possible to observe dense fibrosis and hyalinization.²⁹ Dias and Azevedo²⁹ studied the caterpillar and observed that the setae had several sizes, which were classified as large, medium and small. Conducting experiments with mice, these authors verified that the lesions submitted to biopsy after 24 and 48 hours presented edema with acute leukocytic infiltration and presence of setae. In late lesions, however, there were histiocytic infiltration, giant cells and granulomas involving the setae with variable fibrosis. Dermal, periarticular and sinovial lesions were also detected.

TREATMENT

The treatment for lepidopterism and erucism is symptomatic, and the medical literature has diverse therapeutic options. Accidents by *Hylesia* can cause a very pruritic, erythematous and popular lesions that should be controlled by oral antihistamine drugs and topical corticosteroids. In extreme cases, it may be necessary to use systemic corticosteroids in order to control the clinical picture.¹¹ In accidents caused by caterpillars, according to Rosen,³ the use of antihistamine drugs is disappointing. This author suggests the use of intramuscular triancinolone acetone and potent topical corticosteroids. Cardoso^{4,5} recommends trunk block with local anesthetic agents (4ml of lidocaine for adults), topical corticosteroids and cold water compresses. In pararama, it is essential to use systemic corticosteroids. The intra-articular use of corticosteroids is likely to be beneficial. In the case of hemorrhagic accidents, patients should be treated with antilonomic serum developed and produced at Instituto Butantã. Haddad Jr¹¹ has been using intramuscular dipyrone to control pain and a topical combination of 2.5mg lidocaine and 2.5mg prilocaine. The effect begins 30 minutes after and lasts for several hours.^{10,11} If pain recurs, up to three new applications can be made until the disease is under control. □

ACKNOWLEDGEMENTS

To MD João Luiz Costa Cardoso, for sending data and images

REFERENCES

1. Fonseca F. Acidentes por lagartas. In: Animais peçonhentos. São Paulo: Instituto Butantã; 1950. p. 284-96.
2. Alexander J O. Arthropods and Human Skin. Berlin: Springer Verlag-Heidelberg; 1984. p. 177-97.
3. Rosen T. Caterpillar Dermatitis. *Dermatol Clin*. 1990; 8: 245-52.
4. Cardoso JLC. Erucismo. In: Schwartsman S. Plantas venenosas e Animais Peçonhentos. São Paulo: Editora Sarvier; 1990. p. 237-8.
5. Cardoso JLC. Lepidopterismo. In: Schwartsman S. Plantas venenosas e animais peçonhentos. São Paulo: Sarvier; 1990. p. 236.
6. Moraes RHP. Lepidópteros de importância médica. In: Schwartsman S. Plantas venenosas e animais peçonhentos. São Paulo: Sarvier; 1990. p. 233-6.
7. Rotberg A. Taturanas e mariposas. Folha de São Paulo. [Acesso em: 27 jan 1990].
8. Rotberg A. Erucismo e lepidopterismo. [resumo] In: Anais. 13º Curso de Dermatopatologia Tropical. - Recife; 1991.
9. Carrera M. Insetos de interesse médico e veterinário. Curitiba: Editora da Universidade do Paraná; 1991. p. 228.
10. Brasil. Ministério da Saúde. Manual de Diagnóstico e Tratamento de Acidentes por animais peçonhentos. Brasília: Ministério da Saúde, Fundação Nacional da Saúde; 1997. p. 75-85.
11. Haddad Jr V, Cardoso JLC. Erucismo e Lepidopterismo. In: Cardoso JLC, Wen FH, França FOS, Malaque CMS, Haddad Jr V. Animais peçonhentos no Brasil: biologia, clínica e terapêutica dos acidentes. São Paulo: Sarvier; 2003. p 220-3.
12. Leger M, Mouzels P. Dermatose pruriginose determinada par des papillons Sartunides du genre *Hylesia*. *Bull Soc Pathol Exot Filiales*. 1918; 11: 104-7.
13. Boyé R. La Papillonite Guyanese. *Bull Soc Pathol Exot Filiales*. 1932; 25: 1099-107.
14. Gusmão HH, Foratini OP, Rotberg A. Dermatite provocada por lepidóptero do gênero *Hylesia*. *Rev Inst Med Trop São Paulo*. 1961; 3: 114-20.
15. Jorg ME. Nota prévia sobre el principio ativo urticante de *Hylesia Nigricans* (Lepidoptera, Hemileueidae) y las dermatitis provocadas por el miemo. *Reun Soc Argent Patol*. 1933; 8: 482-95.
16. Tisseuil J. Contribution à l'étude de la papillonite guyanaise. *Bull Soc Pathol Exot Filiales*. 1935; 28: 719-721.
17. Jorg ME. Dermatoses Lepidopterianas (segunda nota). *Rev Soc Argent Patol Reg*. 1939; 9: 1617-35.
18. Cardoso JLC, Borges Filho TS, Carneiro ECG, Moraes HP. Surto de dermatite por *Hylesia paulex* no litoral do Estado de São Paulo, Bertioga, verão 1990. *Mem Inst Butantan*. 1990; 52 (supl): 82.
19. Glasser CM, Cardoso JLC, Carréri-Bruno GC, Domingos MF, Moraes RHP, Ciaravolo RMC. Surtos epidêmicos de dermatite causada por mariposas do gênero *Hylesia* (Lepidoptera: Hemilucinae) no Estado de São Paulo, Brasil. *Rev Saúde Pública*. 1993; 27: 217-20.
20. Valle JR, Picarelli ZP, Prado JL. Histamine Content and pharmacological properties of crude extrats from setae of urticating caterpillar. *Arch Int Pharmacody Terer*. 1954; 98: 324-44.
21. Goldman L, Sawyer F, Levine A, Goldman J, Goldman S, Spinanger J. Investigative studies of skin irritations from caterpillars. *J Invest Dermatol*. 1980; 5: 261-6.
22. Fraiha H, Costa D, Leão RNQ, Ballarini A. Acidentes hemorrágicos por larvas de *Lonomia*. In: Schwartsman S. Plantas venenosas e animais peçonhentos. São Paulo: Sarvier; 1990. p. 241-4.
23. Arocha-Pinãngo CL, Layrisse M. Fibrinolysis produced by contact with a caterpillar. *Lancet*. 1969;1:810-2.
24. Donato JL, Moreno RA, Hyslop S, Duarte A, Antunes E, Le Bonniec BF, et al. *Lonomia obliqua* caterpillar spicules trigger human blood coagulation via activation of factor X and phrotrombin. *Thromb Haemost*. 1998; 79: 539-42.
25. Rocha-Campos ACM. Caracterização biológica e imunológica do extrato de cerdas de *Lonomia obliqua* e produção do soro policlonal específico para uso humano. [tese]. São Paulo: Universidade de São Paulo; 1999.
26. Zanin M. Avaliação dos parâmetros de coagulação e fibrinólise no plasma de pacientes acidentados por contato com lagartas da espécie *Lonomia obliqua*. [tese]. São Paulo: Universidade Federal de São Paulo; 2002.
27. Dias LB. Pararama. In: Instituto Evandro Chagas: 50 anos de contribuição às ciências Biológicas e à Medicina Tropical. Belém: Globo; 1986. p. 799-809.
28. Dias LB. Acidentes por Pararama: Paramose. In: Schwartsman S. Plantas venenosas e animais peçonhentos. São Paulo: Sarvier; 1990. p. 238-41.
29. Dias LB, Azevedo MC. Pararama. In: Veronesi R e cols. Doenças infecciosas e parasitárias. Rio de Janeiro: Guanabara Koogan; 1991. p. 988-9.
30. Dias LB, Azevedo MC. Pararama, a disease caused by moth larvae: experimental findings. *Pathol Bull*. 1973; 7:9-14.

MAILING ADDRESS:

Alberto Eduardo Cox Cardoso

Rua Moreira e Silva, 469

57021-500 Maceió AL

Telefone: (82) 3223-4802

Fax: (82) 3325-4524

E-mail: albertoecardoso@hotmail.com

haddadjr@fmb.unesp.br

 Questions and answers to questions

1. Moth caterpillars are involved in accidents with humans. How are these accidents called?
 - a) lepidopterism
 - b) Paederus dermatitis
 - c) erucism
 - d) phoneutria
2. The accidents caused by *Hylesia* are manifested by:
 - a) severe cutaneous necrosis
 - b) intense edema and erythema as urticariform plaques
 - c) generalized bullous lesions
 - d) pruriginous papules in exposed areas
3. The venomous setae of caterpillars of the family *Saturniidae* are:
 - a) fine and few
 - b) arboriform and plenty
 - c) arboriform and few
 - d) fine and plenty
4. The poison-secreting cells of caterpillars are called:
 - a) trichogen cells
 - b) secreting-cells
 - c) excreting-cells
 - d) tricophytes
5. The main symptom in erucism is:
 - a) intense pruritus
 - b) generalized myalgia
 - c) intense local pain
 - d) severe headache
6. The dermatological examination of a patient injured by a caterpillar shows:
 - a) intense and large erythema and edema
 - b) deep cutaneous necrosis
 - c) vesicle of zosteriform distribution
 - d) discreet inflammatory signs that are not compatible with pain
7. The histopathological exam of a recent accident caused by a caterpillar looks like:
 - a) wheal
 - b) pemphigus foliaceus
 - c) discoid lupus erythematosus
 - d) multiform erythema
8. The contact with caterpillars is usually manifested by intense pain. If a patient reports the accident occurred the day before and has disseminated ecchymoses, would you suspect of:
 - a) accident by *Hylesia*
 - b) accident by *Lonomia*
 - c) simultaneous bothropic accident and contact with caterpillars
 - d) pararama
9. In which state of Brazil there are no hemorrhagic syndromes associated with accidents by *Lonomia*?
 - a) Sao Paulo
 - b) Minas Gerais
 - c) Santa Catarina
 - d) the accidents may occur in all Southeastern and Southern states
10. Which of the following accidents is not related with occupational diseases?
 - a) hemorrhagic syndrome by *Lonomia*
 - b) pararama
 - c) papular dermatitis by *Hylesia*
 - d) none of the above answers
11. The main cause of death in poisoning by *Lonomia* is:
 - a) renal failure
 - b) acute pulmonary edema
 - c) severe cardiac arrhythmia
 - d) intracerebral bleeding
12. The caterpillar responsible for pararama is:
 - a) *Podalia sp*
 - b) *Lonomia obliqua*
 - c) *Automeris sp*
 - d) *Premolis semirufa*
13. In which anatomical area does pararama occur more often?
 - a) hands
 - b) feet
 - c) face
 - d) anterior chest
14. The histopathological alterations in the dermis and joints caused by pararama hairs are:
 - a) spongiosis and fibrinoid necrosis
 - b) granulomas and fibrosis
 - c) keratinocyte necrosis
 - d) achantolysis
15. The accidents caused by caterpillars of the *Saturniidae* and *Megalopygidae* genera (except for *Lonomia*) are more often observed in:
 - a) rural workers
 - b) urban workers
 - c) children
 - d) paramedicals

16. Pain is the main symptom in erucism. The management to control it is:

- a) immediate use of anti-venomous serum
- b) use of oral anti-histamines
- c) general anesthesia
- d) local trunk anesthesia

17. Anti-histamines are useful to treat accidents by:

- a) *Lonomia*
- b) *Hylesia*
- c) Pararama
- d) *Megalopyge*

18. Systemic corticosteroids are an absolute indication for:

- a) hemorrhagic syndromes by *Lonomia*
- b) papular and pruriginous lesions caused by *Hylesia*
- c) arthropaties and dermatites caused by pararama setae
- d) intense pain caused by Saturnidae

19. Anti-venomous serum is produced to treat accidents caused by:

- a) pararama
- b) caterpillars of the *Megalopygidae* family
- c) *Lonomia*
- d) *Hylesia* sp

20. Trunk block generally controls pain in accidents by caterpillars. If pain recurs, the management is:

- a) to repeat trunk block up to three times
- b) corticosteroid infiltration
- c) immersion of the affected limb in hot water for 30 minutes
- d) use of vinegar baths every four hours to inactivate venom

ANSWERS

Lymphoproliferative processes of the skin
Part 1 - Primary cutaneous B-cell lymphomas
2005;80(5):461-71.

- | | |
|-------|-------|
| 1. C | 11. A |
| 2. C | 12. A |
| 3. D | 13. D |
| 4. A | 14. B |
| 5. D | 15. C |
| 6. B | 16. B |
| 7. A | 17. A |
| 8. C | 18. B |
| 9. D | 19. D |
| 10. C | 20. B |