

## CLINICAL CASE

# Febrile ulceronecrotic Mucha-Habermann disease in adult patient successfully treated with systemic corticosteroid\*

Doença de Mucha-Habermann úlcero-necrótica febril em adulto com boa resposta à corticoterapia oral

Priscila Wolf Nassif<sup>1</sup>  
Sadamitsu Nakandakari<sup>3</sup>  
Cleverson Teixeira Soares<sup>5</sup>

Deise Aparecida Santos Godoy<sup>2</sup>  
Cinthia Janine Meira Alves<sup>4</sup>

**Abstract:** The Febrile Ulceronecrotic Mucha-Habermann (FUMHD) disease is a rare variant of *pityriasis lichenoides et varioliformis acuta* (PLEVA). Its etiology still remains unknown and it is characterized by a sudden onset of ulceronecrotic skin lesions associated with systemic symptoms. It is reported here the case of a male patient with a sudden and acute evolution of macules and papules, ulceronecrotic and vesicle-bullous lesions associated with systemic symptoms. The patient was treated with prednisone 0,5 mg/kg/day with a dramatic response. The FUMHD is a severe variant of PLEVA and its diagnosis is clinical and histopathological. Many treatments such as methotrexate, corticosteroids and PUVA have been described. However, none of them has been settled.

**Keywords:** Adrenal cortex hormones; Pityriasis lichenoides; Vasculitis

**Resumo:** A doença de Mucha-Habermann úlcero-necrótica febril (FUMHD) é uma variante clínica rara da pitiríase liquenoide variceliforme aguda (PLEVA). Tem etiologia incerta e é caracterizada por lesões úlcero-necróticas, associadas a sintomas sistêmicos. Relata-se um caso de paciente masculino, com início agudo de lesões máculo-papulares, vesicobolhosas e úlcero-necróticas, associadas à febre alta e mialgia. Tratado com prednisona 0,5 mg/kg/dia, obteve-se excelente resposta terapêutica. A FUMHD é uma variante severa da PLEVA, cujo diagnóstico é clínico e histopatológico. Vários tratamentos são descritos, tais como: metotrexato, corticoesteróides, PUVA, mas nenhum foi estabelecido.

**Palavras-chave:** Corticosteróides; Pitiríase liquenoide; Vasculite

## INTRODUCTION

The Febrile Ulceronecrotic Mucha-Habermann (FUMHD) disease is a rare variant of *pityriasis lichenoides et varioliformis acuta* (PLEVA) with only 39 cases described in the medical literature up to this moment<sup>1</sup>. Its etiology is uncertain and it is characterized by the occurrence of ulceronecrotic lesions, associated with high fever and systemic symptoms.<sup>1</sup> In adults, besides being a more severe condition, there is also a malignant potential that can be related to the clonality of T cells. This case is

reported here due to the rarity and seriousness of the disease in adults and also because of the excellent clinical response to treatment with corticosteroids.

## CASE REPORT

Male patient, aged 49, presenting generalized erythematous macules and papules for 1 week (Figure 1), attacking palms, soles and mucous, that developed into vesiculobullous and ulceronecrotic lesions, some with central crust. (Figure 2). This

Received on 03.08.2009.

Approved by the Advisory Board and accepted for publication on 28.08.2009.

\* Work carried out in the Dermatology Service of the Lauro de Souza Lima Institute (ILSL) – Bauru (SP), Brazil.

Conflict of interest: None / *Conflito de interesse: Nenhum*

Financial funding: None / *Suporte financeiro: Nenhum*

<sup>1</sup> MD, ongoing specialization course in Dermatology from the Lauro de Souza Lima Institute (ILSL) – Bauru (SP), Brazil.

<sup>2</sup> MD, Dermatologist, Preceptor of the residency in Dermatology of the Lauro de Souza Lima Institute (ILSL) – Bauru (SP), Brazil.

<sup>3</sup> MD, Dermatologist- Chief-Preceptor of the residency in Dermatology of the Lauro de Souza Lima Institute (ILSL) – Bauru (SP), Brazil.

<sup>4</sup> MD, Dermatology resident of the Lauro de Souza Lima Institute (ILSL) – Bauru (SP), Brazil.

<sup>5</sup> MD, Pathologist of the Lauro de Souza Lima Institute (ILSL) – Bauru (SP), Brazil.

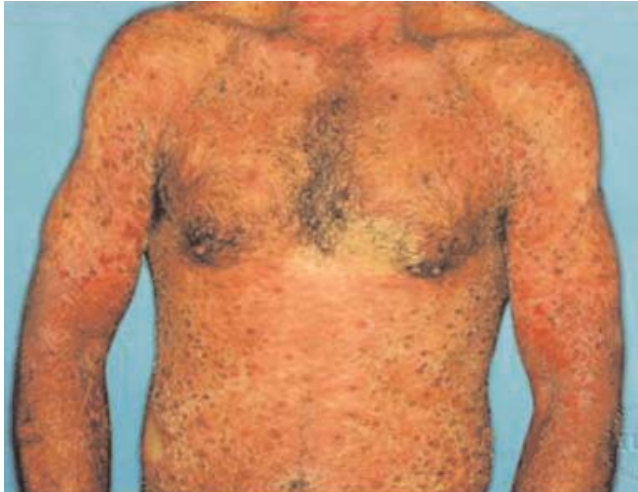

FIGURE 1: Erythematous papules and maculae on the chest. Ulcerous necrotic lesions, of 0,5 to 1 cm of diameter

condition was associated with a general malaise, high fever (40 degrees) and myalgia. Laboratorial exams presented hyponatremia, hypocalcemia and lymphopenia. FTAabs, VDRL, herpes 1 and 2 serology, Anti-HIV 1 and 2, were negative. The histopathological exam confirmed the diagnosis and revealed lymphohistiocytic inflammatory infiltrate, with intense aggression of epidermis, edema and vacuolar degeneration of keratinocytes, intense exocytosis, blistering, with evolution to ulcers and vascular congestion, with extravasation of erythrocytes (Figures 3 and 4), compatible with Mucha-Habermann disease. Prednisone (40 mg/day) was used with excellent therapeutic response. The corticosteroid

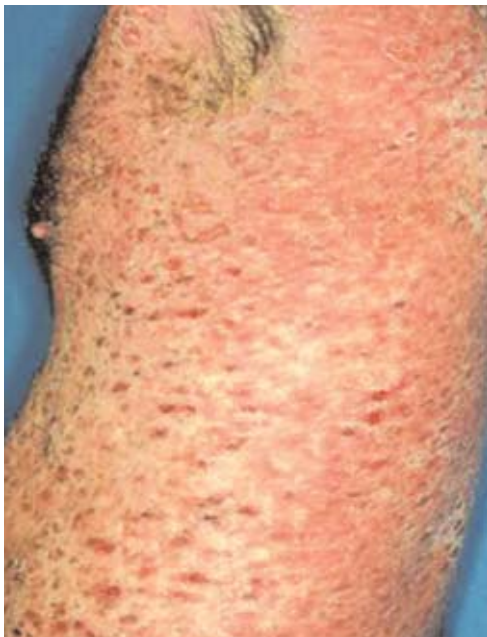

FIGURE 2: Macular and necrotic lesions on the chest

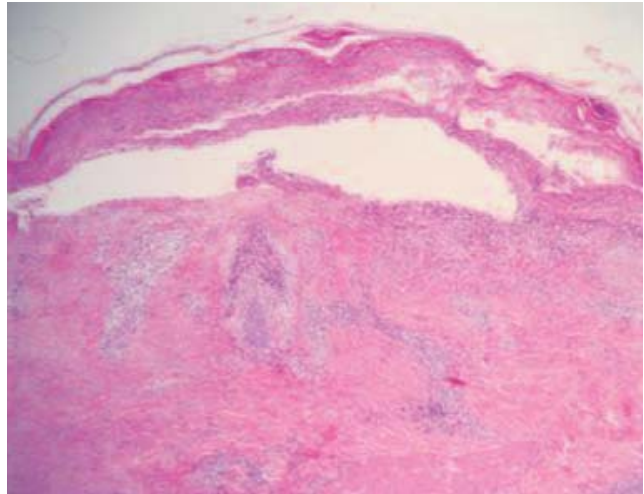


FIGURE 3: H.E. Chronic lymphohistiocytic infiltrate, with aggression to the epidermis, blistering, exocytosis and basal layer vacuolar degeneration

was then gradually reduced until its complete withdrawal and the patient has not presented so far lesion recurrence

#### DISCUSSION

It is up to V. Mucha the first publication, in 1916, in Germany, of a case of acute papular-squamous eruption named Parakeratosis Variiegata (Unna) or Pityriasis Lichenoides Chronica (Neisser-Juliusberg).<sup>2</sup> R.Habermann, in 1925, suggests a new name for it : Pityriasis Lichenoides et Varioliformis Acuta (PLEVA),<sup>2</sup> also known as Mucha-Habermann disease.

The Febrile Ulceronecrotic Mucha-Habermann (FUMHD) disease is a severe variant of *pityriasis lichenoides et varioliformis acuta* (PLEVA), which is

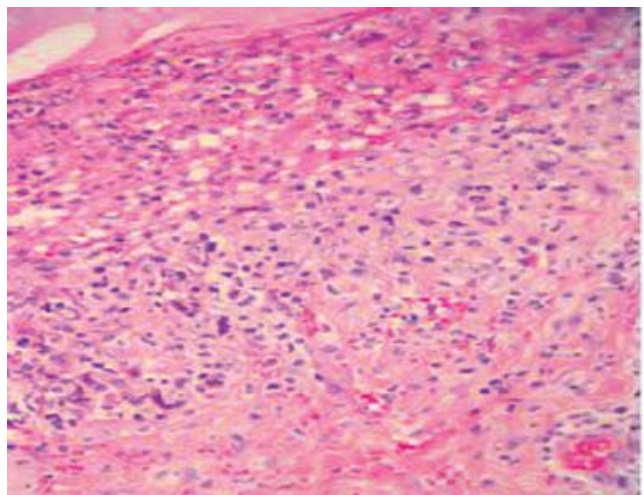


FIGURE 4: H.E. Intense aggression to the epidermis through inflammatory infiltrate, intense exocytosis and keratinocytes vacuolar degeneration

characterized by the sudden appearance of ulceronecrotic lesions, associated with high fever (40 degrees), myalgia, arthralgia, gastrointestinal and central nervous system symptoms, interstitial pneumonitis, lymphocytic myocarditis and even death.<sup>3,4</sup> In general, its development is limited to weeks or months, and occasionally it evolves into a chronic disease, with exacerbations and remissions.<sup>4</sup> It frequently affects children and young adults, differently from our case which refers to a 49 year-old patient. The prognosis for children is better than for adults, since in adults the condition is more severe and there is a malignant potential that can be related to the clonality of T cells.<sup>1,4,5</sup> In this study, the patient presented excellent clinical response to the therapeutics with systemic corticosteroid, contradicting the medical literature. The etiology of the disease remains uncertain as it is not known yet whether PLEVA is a reaction to hypersensitivity to some infectious agents (HIV, streptococcus, toxoplasma, viral agents),<sup>6</sup> a hypersensitivity vasculitis (immune-mediated) or if it is a genuine lymphoproliferative process that is part of the scope of skin lymphoproliferative disorder diseases of the T-cell.<sup>1,5,7</sup> Despite this, the transformation of T-cells in lymphoma is rare and the similarities with lymphomatoid papulosis are still being debated.

The diagnosis is clinical and histopathological. In the laboratory it is observed VHS, PCR and high leukocytes count. In some patients it can be found antibodies against streptolysin A and eosinophilia.<sup>7</sup> In the patient studied it was observed hyponatremia, hypocalcemia and lymphopenia apart from the results of serology for HIV, syphilis and herpes being negative. Histopathology showed

perivascular lymphocytic inflammatory infiltrates, on the superficial dermis, with epidermic exocytosis from remains of lymphocytes and parakeratotic squamiae with accumulation of inflammatory cells among the different layers.<sup>6</sup> Differential diagnoses can be made with lymphomatoid papulosis, syphilis, chickenpox, and erythema multiforme.<sup>6</sup>

Various treatments have been proposed. However, none of them was established as the number of reported cases is still small. Yang describes the use of high doses of oral corticosteroids initially to reduce the inflammatory component and followed by oral erythromycin for maintenance.<sup>1,6,7</sup> There is a report of a patient treated with pulsetherapy with methylprednisolone 500mg/day, three consecutive days of oral prednisone 40mg/day followed by maintenance therapy with methotrexate (7,5 mg/week).<sup>8</sup> Other works describe the use of isolated methotrexate, PUVA, acyclovir, azithromycin and 4,4 diaminodiphenyl sulfone.<sup>1,6,7,9</sup> The use of oral cyclosporine, with an initial dose of 2,5mg/kg/day and posteriorly 1,25mg/kg/day, also had good result in a 8-year-old patient with FUMHD.<sup>10</sup> A retrospective analysis of 20 cases demonstrated that 6 out of 15 patients had a favorable therapeutic response to prednisolone, in doses higher than 1 mg/kg/day.<sup>8</sup> In the case presented here, the patient was treated with 0,5 mg/kg/day and he remained without lesions, even after the withdrawal of systemic corticosteroid, and without maintenance therapy.

Although the case reported here had a favourable evolution, the FUMHD is a disease that can be fatal in adults and therefore it needs more studies as the best treatment is not still well established due to the small number of cases described. □

## REFERENCES

1. Sotiriou E, Patsatsi A, Tsova C, Lazaridou E, Sotiriadis D. Febrile Ulceronecrotic Mucha-Habermann Disease: A Case Report and Review of the Literature. *Acta Derm Venereol.* 2008; 88:350-5.
2. Sternick M, Talarico RA. Posição da Doença de Mucha-Habermann entre as vascularites. *An Bras Dermatol.* 1981;56:37-42.
3. Miyamoto T, Takayama N, Kitada S, Hagari Y, Mihara M. Febrile ulceronecrotic Mucha-Habermann disease: a case report and a review of the literature. *J Clin Pathol.* 2003;56:795-7.
4. Aytakin S, Balci G, Duzgun OY. Febrile ulceronecrotic Mucha-Habermann disease: A case report and a review of the literature. *Dermatol Online J.* 2005;11:31.
5. Dereure O, Levi E, Kadin ME. T-Cell clonality in pityriasis lichenoides et varioliformis acuta: a heteroduplex analysis of 20 cases. *Arch Dermatol.* 2000;136:1483-6.
6. Gómez MTB, Durán JCS, Estella SJ, Chaves YM, San Pablo AMT. Pityriasis liquenoide y varioliforme aguda (enfermedad de Mucha-Habermann). *An Pediatr (Barc).* 2007;66:87-106.
7. Ricci G, Patrizi A, Misciali D, Masi M. Pathological case of the month. *Arch Pediatr Adolesc Med.* 2001;155:195-6.
8. Ito N, Ohshima A, Hashizume H, Takigawa M, Tokura Y. Febrile ulceronecrotic Mucha-Habermann's disease managed with methylprednisolone semipulse and subsequent methotrexate therapies. *J Am Acad Dermatol.* 2003;49:1142-8.
9. Skinner RB, Levy AL. Rapid resolution of pityriasis lichenoides et varioliformis acuta with azithromycin. *J Am Acad Dermatol.* 2008;58:524-5.
10. Kim HS, Yu DS, Kim JW. A case of febrile ulceronecrotic Mucha-Habermann's disease successfully treated with oral cyclosporine. *J Eur Acad Dermatol Venereol.* 2007;21:272-3.

---

*MAILING ADDRESS / ENDEREÇO PARA CORRESPONDÊNCIA:*  
*Priscila Wolf Nassif*  
*Rua Piratininga, 159 apto 122 cep 87013-100*  
*Maringá-PR, Brazil*  
*Phone: 44 9922 1072 / 44 3262 1712*  
*Email: priwolf@gmail.com*

Como citar este artigo/How to cite this article: Wolf-Nassif P, Godoy DAS, Nakandakari S, Alves CJM, Soares CT. Febrile ulceronecrotic Mucha-Habermann disease in adult patient successfully treated with systemic corticosteroid. *An Bras Dermatol.* 2010;85(6):891-4.