

## Financial support

None declared.

## Authors' contributions

Viviane Maria Maiolini: Drafting and editing of the manuscript; intellectual participation in the propaedeutic and/or therapeutic conduct of the studied cases; critical review of the literature; approval of the final version of the manuscript; critical review of the manuscript.

Nathalie Andrade Sousa: Drafting and editing of the manuscript; intellectual participation in the propaedeutics and/or therapeutic conduct of the studied cases; critical review of the literature; approval of the final version of the manuscript; critical review of the manuscript.

Paula Figueiredo de Marsillac: Drafting and editing of the manuscript; intellectual participation in the propaedeutics and/or therapeutic conduct of the studied cases; critical review of the literature; approval of the final version of the manuscript; critical review of the manuscript.

Aline Lopes Bressan: Design and planning of the study; writing and editing of the manuscript; intellectual participation in the propaedeutics and/or therapeutic conduct of the studied cases; critical review of the literature; approval of the final version of the manuscript; critical review of the manuscript.

## Conflicts of interest

None declared.

## References

1. Bircher AJ. Psoriasis-like Dermatitis Developing in a Patient with Atopic Dermatitis Treated with Dupilumab. *Dermatitis*. 2019;30:376–8.
2. Tracey EH, Elston CE, Fease P, Piliang M, Michael M, Vij M. Erythrodermic presentation of psoriasis in a patient treated with dupilumab. *JAAD Case Rep*. 2018;4:708–10.
3. Aoki V, Lorenzini D, Orfali RL, Zaniboni MC, de Oliveira ZNP, Rivitti-Machado MC, et al. Consensus on the therapeutic management of atopic dermatitis - Brazilian Society of Dermatology. *An Bras Dermatol*. 2019;94 2 Supl 1:67–75.
4. Oua Z, Chena C, Chena A, Yanga Y, Zhou W. Adverse events of Dupilumab in adults with moderate-to-severe atopic dermatitis: A meta-analysis. *Int Immunopharmacol*. 2018;54:303–10.
5. George SMC, Taylor MR, Farrant PBJ. Psoriatic alopecia. *Clin Exp Dermatol*. 2015;40:717–21.

Viviane Maria Maiolini , Nathalie Andrade Sousa , Paula Figueiredo de Marsillac , Aline Lopes Bressan 

Service of Dermatology, Faculty of Medical Sciences, Hospital Universitário Pedro Ernesto, Universidade do Estado do Rio de Janeiro, Rio de Janeiro, RJ, Brazil

\* Corresponding author.

E-mail: [vivianemaiolini@gmail.com](mailto:vivianemaiolini@gmail.com) (V.M. Maiolini).

Received 26 January 2021; accepted 24 March 2021

Available online 14 July 2021

<https://doi.org/10.1016/j.abd.2021.03.005>

0365-0596/ © 2021 Sociedade Brasileira de Dermatologia.

Published by Elsevier España, S.L.U. This is an open access article under the CC BY license

(<https://creativecommons.org/licenses/by/4.0/>).

## Bacillus Calmette-Guérin vaccine-induced lupus vulgaris in a 3-year-old child<sup>☆,☆☆</sup>



Dear Editor,

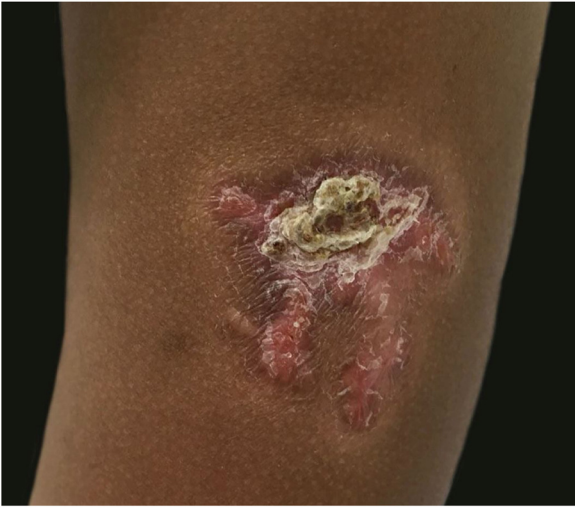A 3-year-old girl presented with an asymptomatic lesion on the left upper arm of 2 years' duration. The lesion started as a papule at the site of Bacillus Calmette-Guérin (BCG) vaccination scar at the age of 1 year and gradually enlarged to its present size. She had no constitutional symptoms and was otherwise well. There was no history of contact with an active case of Tuberculosis (TB). General and systemic examinations were normal. Cutaneous examination revealed an erythematous plaque measuring 5×4 cm with thick adherent scales and fingerlike extensions on the left deltoid region (Fig. 1). Clinical differential diagnoses considered were BCG

vaccine-induced lupus vulgaris, chromoblastomycosis, psoriasis, and discoid lupus erythematosus.

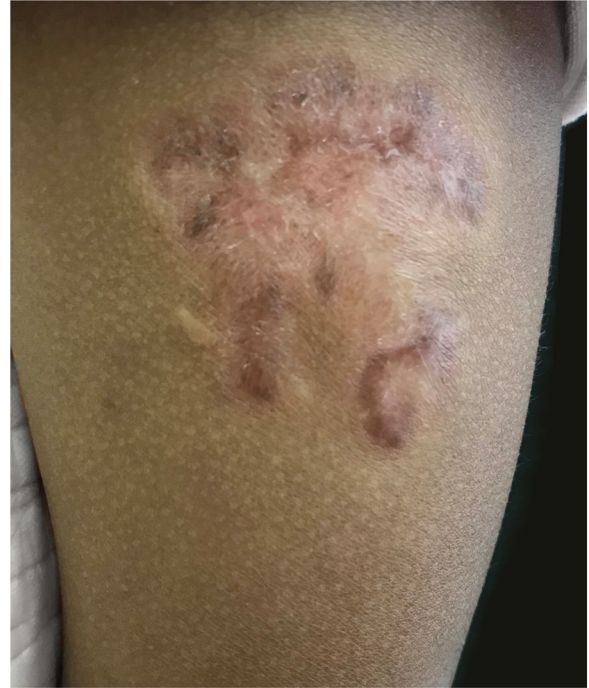Routine hematological investigations showed a raised erythrocyte sedimentation rate. Her chest X-Ray was normal. Serology for HIV was negative. A skin biopsy of the plaque revealed non-caseating epithelioid cell granulomas with a rim of lymphocytes in the upper and mid dermis (Fig. 2). Acid-fast bacilli and periodic acid-Schiff staining of biopsy specimen were negative. Cultures of the skin biopsy were also negative for mycobacteria and fungi. Mycobacterium (M) tuberculosis complex DNA detection via Polymerase Chain Reaction (PCR) of the biopsy specimen was negative. Interferon-gamma release assay using the Quantiferon TB gold test was also negative. Based on the site of lesion, clinical morphology, and presence of epithelioid cell granulomas in histopathology, the possibility of BCG vaccine-induced lupus vulgaris was considered and a trial of antitubercular therapy was commenced. *M. bovis* is inherently resistant to pyrazinamide and ethambutol is avoided in children due to its ophthalmologic side effects.<sup>1</sup> The child thus received a regimen consisting of rifampicin (6 mg/kg/day) and isoniazid (5 mg/kg/day) from the Pediatric Infectious Disease unit. The lesion healed completely after 2 months of therapy (Fig. 3). A final diagnosis of BCG vaccine-induced lupus vulgaris was thus made.

<sup>☆</sup> How to cite this article: Parmar NV, Al Falasi A, Almualla A. Bacillus Calmette-Guérin vaccine-induced lupus vulgaris in a 3-year-old child. *An Bras Dermatol*. 2021;96:636–8.

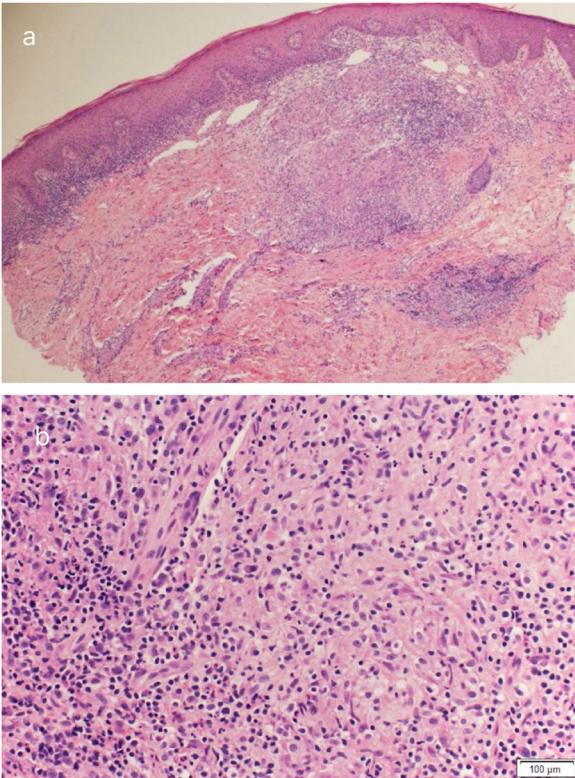
<sup>☆☆</sup> Study conducted at the Dermatology Centre, Dubai Health Authority, Dubai, United Arab Emirates.



**Figure 1** Well-demarcated erythematous scaly plaque with centrally adherent thick scales and finger-like extensions measuring 5×4 cm at site of BCG vaccine scar on left deltoid region.



**Figure 3** Scar at site of lesion post-treatment.



**Figure 2** (A), Granulomatous infiltration in upper and mid-dermis. (B), Non-caseating epithelioid cell granuloma with peripheral lymphocytic rim.

The BCG vaccine is composed of a live attenuated strain of *M. bovis*. It is routinely administered to all neonates in high endemic countries to prevent the more serious forms of tubercular infections such as meningoencephalitis and miliary tuberculosis in children.

Cutaneous complications of the BCG vaccine in the immunocompetent host include the common local reaction to the vaccine and uncommon reactions. The local reaction

occurs 2–6 weeks post-vaccination as a small papule that may discharge purulent material, enlarge to form a shallow ulcer which scars. The rare complications include BCG granuloma, injection site keloids, lupus vulgaris, scrofuloderma, tuberculids, fixed drug eruption, and BCG granulomas occurring during the course of Kawasaki disease.<sup>2</sup>

BCG vaccine-induced lupus vulgaris occurs in 5 per million vaccinations.<sup>3</sup> It is commoner after multiple vaccinations and usually manifests after 1 year of vaccination. Lupus vulgaris is a paucibacillary form of cutaneous tuberculosis that occurs either via hematogenous spread or direct inoculation. A skin biopsy is helpful in obtaining a histopathological diagnosis. Other confirmatory tests for tuberculosis may be inconclusive as in our patient. A high index of suspicion is required for the diagnosis and a trial of antitubercular drugs is warranted.

### Financial support

None declared.

### Authors' contributions

Nisha V Parmar: Conception and planning of the study; critical review of the literature; obtaining, analysis, and interpretation of the data; elaboration and writing of the manuscript; critical review of the manuscript. approval of the final version of the manuscript.

Amani ALFalasi: Approval of the final version of the manuscript; obtaining, analysis, and interpretation of the data; critical review of the manuscript.

Alia AlMualla: Approval of the final version of the manuscript; obtaining, analysis, and interpretation of the data; critical review of the manuscript.

## Conflicts of interest

None declared.

## References

1. Walker SL, Lozewicz S, Sood R, Mann TAN, Campalani E, Hubbard VG. Lupus vulgaris due to *Mycobacterium bovis* bacillus Calmette-Guérin (BCG) at the site of previous BCG vaccination. *Clin Exp Dermatol.* 2009;34:e213–5.
2. Bellet J, Prose N. Skin complications of bacillus Calmette-Guérin immunization. *Current Opin Infect Dis.* 2005;18:97–100.
3. Farsinejad K, Daneshpazhooh M, Sairafi H, Barzegar M, Mortazavizadeh M. Lupus vulgaris at the site of BCG vaccination: report of three cases. *Clin Exp Dermatol.* 2009;34:e167–9.

Nisha V. Parmar \*, Amani Al Falasi , Alia Almualla 

*Dermatology Centre, Dubai Health Authority, Dubai, United Arab Emirates*

\* Corresponding author.

E-mail: [parmarnish@gmail.com](mailto:parmarnish@gmail.com) (N.V. Parmar).

Received 4 July 2020; accepted 21 July 2020

Available online 14 July 2021

<https://doi.org/10.1016/j.abd.2020.07.022>

0365-0596/ © 2021 Sociedade Brasileira de Dermatologia.

Published by Elsevier España, S.L.U. This is an open access article under the CC BY license

(<https://creativecommons.org/licenses/by/4.0/>).

## Effects of dupilumab in type 1 neurofibromatosis coexisting with severe atopic dermatitis<sup>☆,☆☆</sup>



Dear Editor,

We report the case of a 30-year-old Caucasian woman with type 1 neurofibromatosis (NF1), who came to medical attention for the recent worsening of a concomitant severe form of atopic dermatitis (AD). The patient presented typical features of NF1: axillary and inguinal freckles, café-au-lait spots, multiple subcutaneous neurofibromas, Lisch nodules, spinal alterations with scoliosis. AD was characterized by a generalized pattern and predominant involvement of the face with eyelid eczema and ectropion (Fig. 1). Eczema area severity index (EASI) score was 30 and dermatology life quality index (DLQI) was 25, corresponding to a severe form of the disease. Due to the inefficacy of previous treatments with systemic steroids and cyclosporine in achieving clinical improvement of atopic dermatitis, the patient started therapy with dupilumab at a standard approved dosage of 600 mg subcutaneously followed by 300 mg every two weeks, according to current guidelines. Four weeks after the initiation of therapy, we observed improvement in the signs and symptoms of AD (EASI 4) (Fig. 2). As a collateral finding, we also observed a reduction in the size and swelling of the neurofibromas (Fig. 3). After 16 weeks, we assessed complete remission of AD and no progression of NF1, in terms of number and size of neurofibromas, with an overall improvement in the quality of life of the patient (DLQI 0). After 18 months of treatment, the cutaneous burden of NF1 remained stable.

In our patient, dupilumab proved to be effective both in the management of severe AD and in neurofibromas, achieving stabilization of the disease at one year. The possible effectiveness of the drug on NF1 may reside in the molecular pathology of neurofibromatosis. Fibroblasts and mast cells are key players in the promotion of tumor growth in the neurofibroma microenvironment, as well as in wound healing and scar formation.<sup>1,2</sup> As previously reported, the activation of IL-4 and IL-13 pathways in fibroblasts, mediated by JAK/STAT intracellular signaling, leads to excessive collagen production, which is responsible for neurofibroma development.<sup>3</sup> In regard to NF1, we hypothesize that anti-IL-4 receptor monoclonal antibody dupilumab may inhibit the growth of neurofibromas, interfering with IL-4 and IL-13 binding to type I and type II receptors expressed on mast cells and fibroblasts. This is consistent with the mechanism of action previously described in AD.<sup>4</sup> To date, pharmacological treatments for neurofibromas in NF1 are still lacking. Moreover, there is no previous reported evidence of the effect of dupilumab in the treatment of NF1. This is probably also due to the paucity of studies highlighting the association between the two disorders. Indeed, only one study reported the co-existence of concomitant AD in 18% of 227 NF1 patients, but these data are not confirmed by further evidence in the current literature.<sup>5</sup>

Our experience could be helpful in the management of NF1, underlining the beneficial anti-inflammatory effect of this biological drug on the neurocutaneous disease, but we are conscious that pathogenetic studies of cytokine interactions and immune signaling pathways as well as RCTs are needed in order to investigate the use of dupilumab in NF1 treatment.

<sup>☆</sup> How to cite this article: How to cite this article: Chello C, Sernicola A, Paolino G, Grieco T. Effects of dupilumab in type 1 neurofibromatosis coexisting with severe atopic dermatitis. *An Bras Dermatol.* 2021;96:638–40.

<sup>☆☆</sup> Study conducted at the Dermatology Unit, Sapienza University of Rome, Rome, Italy.