



Figure 2 Wood's light examination revealed fluorescence bright blue-white in malar and perioral right regions.

Financial support

None declared.

Authors' contributions

Maria Fernanda de Santana Avelar-Caggiano: Conception and planning of the study; elaboration and writing of the manuscript; obtaining, analysis, and interpretation of the data; critical review of the literature.

Caio César Silva de Castro: Approval of the final version of the manuscript; effective participation in research orientation; intellectual participation in the propaedeutic and/or therapeutic conduct of the studied cases; critical review of the manuscript.

Gerson Dellatorre: Approval of the final version of the manuscript; effective participation in research orientation; intellectual participation in the propaedeutic and/or therapeutic conduct of the studied cases; critical review of the manuscript.

Conflicts of interest

None declared.

References

1. VanGeel N, Mollet I, Brochez L, Dutré M, De Schepper S, Verhaeghe E, et al. New insights in segmental vitiligo: case report and review of theories. *Br J Dermatol.* 2011;166:240–6.
2. Rao PK, Bhat RM, Nandakishore B, Dandakeri S, Martis J, Kamath GH. Safety and efficacy of low-dose isotretinoin in the treatment of moderate to severe acne vulgaris. *Indian J Dermatol.* 2014;59:316.
3. Kokandi AA. Vitiligo appearing after oral isotretinoin therapy for acne. *Case Rep Dermatol Med.* 2018;2018:1–3.
4. Garner ML, McShane DB, Burkhart CN, Morrell DS. Isotretinoin and vitiligo: can chronic cheilitis cause koebnerization? *Pediatr Dermatol.* 2015;32:108–9.
5. Nugroho J, Schweiger B. Isotretinoin as a possible environmental trigger to autoimmunity in genetically susceptible patients. *Case Rep Pediatr.* 2017;2017:1–3.

Maria Fernanda de Santana Avelar-Caggiano ^{a,*},
Caio César Silva de Castro ^b, Gerson Dellatorre ^a

^a Service of Dermatology, Hospital Santa Casa de Misericórdia de Curitiba, Curitiba, PR, Brazil

^b Medical School, Pontifícia Universidade Católica do Paraná, Curitiba, PR, Brazil

* Corresponding author.

E-mail: mafe_avelar@yahoo.com.br (M.F. Avelar-Caggiano).

Received 1 April 2019; accepted 22 July 2019

Available online 20 March 2020

<https://doi.org/10.1016/j.abd.2019.07.014>

0365-0596/ © 2020 Sociedade Brasileira de Dermatologia.

Published by Elsevier España, S.L.U. This is an open access article under the CC BY license (<http://creativecommons.org/licenses/by/4.0/>).

Herpes zoster incognito: an immunohistochemical diagnosis^{☆☆☆}



Dear Editor,

A 60-year-old woman presented with a 1 week history of an erythematous and edematous plaque on her scalp. The lesion, 2.5 cm in diameter, was associated to mild pain (Fig. 1). Histopathological examination showed a massive inflammatory infiltrate in the dermis, especially surrounding sebaceous glands and responsible of oedema in the papil-

lary dermis with initial dermo-epidermal vesicle formation (Fig. 2A). In the suspect of a herpetic infection, immunohistochemistry was performed, revealing negativity for Herpes Simplex virus (HSV) and positivity for Varicella Zoster virus (VZV) (Fig. 2B). Our diagnosis was therefore herpes zoster incognito.

Herpes zoster (HZ), due to the reactivation of VZV, present in a latent state in sensory ganglia, can remain inactive for decades or also for the whole life. Essential condition is a previous contact, usually during infancy, with VZV. HZ is characterized by unilateral erythematous-vesicular rash and a localized pain. Nevertheless, especially at the onset of an eruption or in forms considered as abortive, when lesions are macules, papules, and plaques, clinical diagnosis may be challenging. Microscopical examination can be used to confirm infection by herpesviruses, but sometimes typical signs such as multinucleated epithelial cells or ghosts of them are not encountered in a specimen.

[☆] How to cite this article: Nazzaro G, Veraldi S. Herpes zoster incognito: an immunohistochemical diagnosis. *An Bras Dermatol.* 2020;95:401–2.

^{☆☆} Study conducted at the Department of Pathophysiology and Transplantation, Università degli Studi di Milano, Fondazione IRCCS Ca' Granda Ospedale Maggiore Policlinico, Milan, Italy.

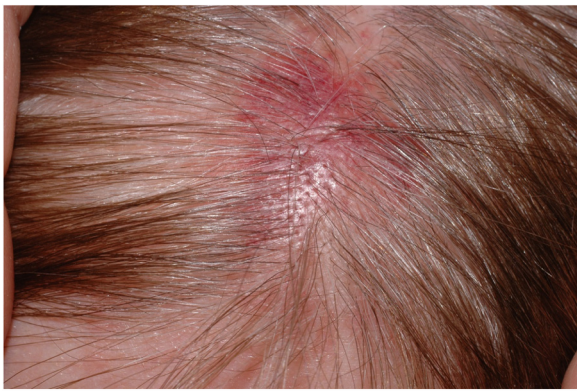


Figure 1 Erythematous plaque with recent onset at the top of a 60 year-old woman.

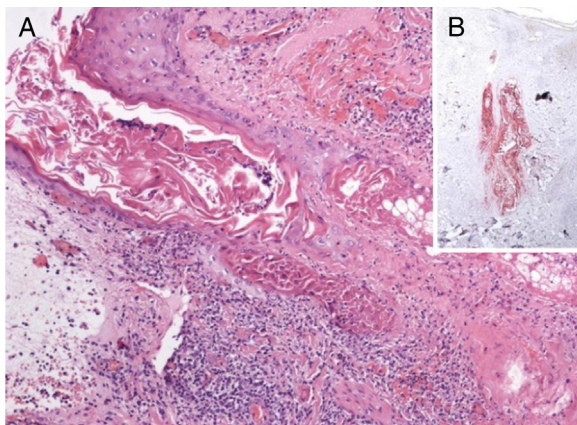


Figure 2 A, Inflammatory infiltrate surrounding follicular epithelium and sebaceous gland. Initial bullous detachment at the dermo-epidermal junction (Hematoxylin & eosin, $\times 40$). B, The primary involvement of the skin is on the sebaceous epithelium, as shown by immunohistochemistry specific for varicella zoster virus (Hematoxylin & eosin, $\times 40$).

The term “herpes incognito” (from Latin, meaning not recognizable) has therefore been introduced.¹

The virus is transported from dorsal root or trigeminal ganglia via myelinated nerves which terminate at the isthmus of hair follicles. Consequently, the primary involvement of the skin is on follicular and sebaceous epithelium,² as shown in the case presented. Spread of infection to the epidermis follows. This clue, that is pathognomonic of HZ and is not found in herpes simplex, can be easily confirmed by immunohistochemistry. This histological method, that can be used to distinguish the viral aetiology in tricky causes,³ demonstrates that HSV affects primarily the epidermis and the upper portions of follicles only occasionally but never sebaceous epithelium or nerves. In fact, VZV spreads preferentially from dermal nerves to folliculosebaceous units and thence to the epidermis. Nevertheless, the reason why recurrent HSV infection primarily targets the epidermis, in contrast to HZV, which is preferentially directed to folliculosebaceous units, is not fully understood.

In a study involving 75 patients with a clinical differential diagnosis of herpetic infections,⁴ HZ was misdiagnosed as HSV infection in 30% of the cases as the clinicians were

in difficult when vesicles were absent. From a histological point of view, herpetic folliculitis was detected in 28% of HZ, while it was not encountered in herpes simplex infections.

In conclusion, HZ may present with clinical variants, such as purpuric or hemorrhagic⁵ in patients in antiplatelet or anticoagulant therapy and, gangrenous, bullous or disseminated HZ in immunocompromised patients. We described a case of herpes incognito, an underreported clinical variant of HZ, representing its abortive form, with distinctive clinical and histological features.

Financial support

None declared.

Authors' contributions

Gianluca Nazzaro: Approval of the final version of the manuscript; elaboration and writing of the manuscript; obtaining, analysis, and interpretation of the data; effective participation in research orientation; critical review of the literature; critical review of the manuscript.

Stefano Veraldi: Approval of the final version of the manuscript; critical review of the literature.

Conflicts of interest

None declared.

References

1. Böer A, Herder N, Blodorn-Schlicht N, Falk T. Herpes Incognito most commonly is herpes zoster and its histopathologic pattern is distinctive. *Am J Dermatopathol.* 2006;28:181–6.
2. Walsh N, Boutillier R, Glasgow D, Shaffelbug M. Exclusive involvement of folliculosebaceous units by herpes – a reflection of early herpes zoster. *Am J Dermatopathol.* 2005;27:189–94.
3. Veraldi S, Fanoni D, Nazzaro G. Herpes zoster of the penis: an immunohistochemistry diagnosis. *J Cutan Pathol.* 2012;39:811–2.
4. Böer A, Herder N, Blödorn-Schlicht N, Steinkraus V, Falk TM. Refining criteria for diagnosis of cutaneous infections caused by herpes viruses through correlation of morphology with molecular pathology. *Indian J Dermatol Venereol Leprol.* 2006;72:270–5.
5. Veraldi S, Vaira F, Nazzaro G. Purpuric herpes zoster in patients in therapy with clopidogrel. *J Clin Virol.* 2015;69:122–4.

Gianluca Nazzaro *, Stefano Veraldi

Department of Pathophysiology and Transplantation, Università degli Studi di Milano, Fondazione IRCCS Ca' Granda Ospedale Maggiore Policlinico, Milan, Italy

* Corresponding author.

E-mail: gianluca.nazzaro@gmail.com (G. Nazzaro).

Received 11 March 2019; accepted 23 July 2019

Available online 19 March 2020

<https://doi.org/10.1016/j.abd.2019.07.011>

0365-0596/ © 2020 Sociedade Brasileira de Dermatologia.

Published by Elsevier España, S.L.U. This is an open access article under the CC BY license (<http://creativecommons.org/licenses/by/4.0/>).