

Case for diagnosis *

Caso para diagnóstico

Cristina Paula Salaro¹Georgi Tchernev²**CASE REPORT**

A 55-year-old Caucasian male patient presents with painful plaques on the left leg, which had been present for 6 months, and recent inguinal swelling. He presented cardiopathy (atrial fibrillation), nephropathy (decompensated chronic renal failure) and insulin-dependent diabetes mellitus with polyneuropathy. He was treated with intravenous ciprofloxacin and local care when admitted to the Clinic of Internal Medicine under the hypothesis of erysipelas. No response was observed.

Referred to the Department of Dermatology, infiltrated plaques and erythematous-violaceous nodules associated with edema of the left leg were observed (Figure 1). Palpable bilateral inguinal lymphadenopathy. A CBC revealed mild lymphopenia, with

a population of B and T lymphocytes slightly decreased and T/NK lymphocytes slightly increased. Bone marrow aspiration did not reveal neoplastic lymphoid cells and immunophenotyping showed no monoclonal B or T cells. Histopathology of skin lesions revealed dense infiltrate of neoplastic lymphoid cells (Figures 2 and 3). Immunohistochemistry was positive for CD 20, CD 79 a and Ki-67 in 80% of the cells. Imaging examinations (x-ray and tomography) revealed an increase in bilateral inguinal, axillary and mediastinal lymph nodes; lymphadenopathy was considered nonspecific. In the Department of Oncology, chemotherapy with cyclophosphamide, adriamycin and vincristine was initiated. After two cycles, there was partial remission of the lesions.

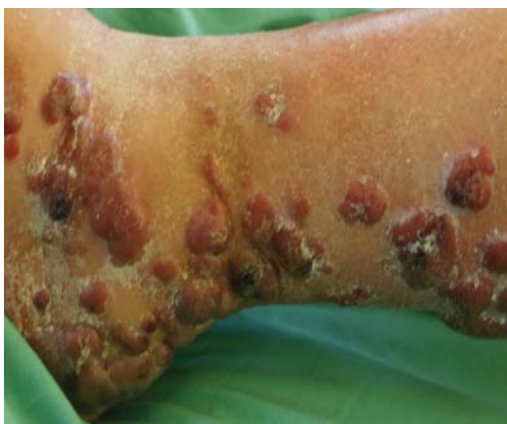

FIGURE 1: Infiltrated purple erythematous nodules and plaques grouped along the back side of the right leg, heel and plantar surface of the right foot

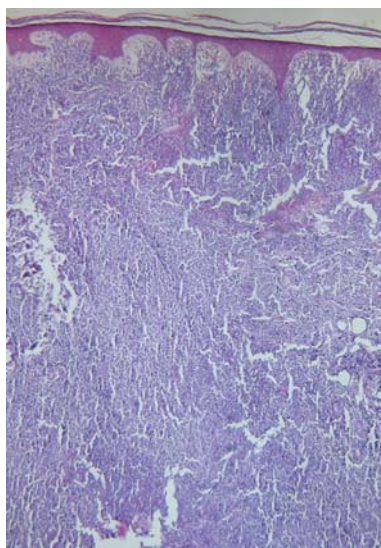


FIGURE 2: Macroscopic aspect. Dense monomorphic lymphocytic infiltrate, from the dermis to the subcutaneous tissue; presence of Grenz zone

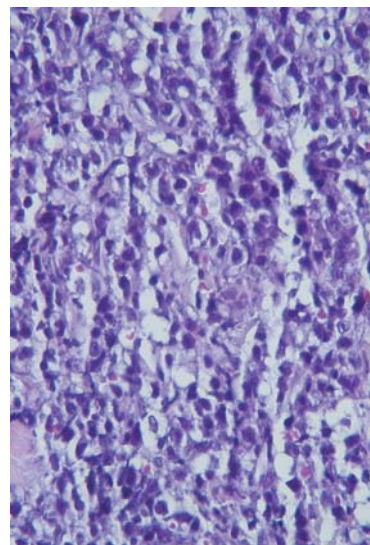


FIGURE 3: Microscopic aspect. Dense infiltrate of large cells constituted by centroblasts, immunoblasts and large centrocytes. Mitosis can be observed

Received on 19.09.2010

Approved by the Editorial Board and accepted for publication on 26.10.2010.

* Work conducted at the Department of Dermatology and Immunology, Municipal Hospital Dessau - Dessau, Germany

Conflict of interest: None / *Suporte Financeiro: Nenbum*

Financial funding: None / *Conflito de Interesses: Nenbum*

¹ Dermatology degree from the University of Brasilia, Harvard University Fellowship. Private clinic: Dermatologic - Brasilia (DF), Brazil.

² Professor at the Department of Dermatology and Venereology, Trakian Medical University of Stara Zagora, Medical University of Sofia - Sofia, Bulgaria.

DISCUSSION

Considering the clinical presentation, confirmed by histopathology and immunohistochemical examination of the skin lesions, we are facing a case of primary cutaneous B-cell lymphoma - leg type. Unlike T lymphomas, the origin of a B-cell lymphoma in the skin is almost always subject to doubt: is it a primary cutaneous process or lymphomatous infiltration of the skin from undiagnosed node or visceral neoplasm? In this case, the presence of inguinal, axillary and mediastinal lymphadenopathy raises this question.

Regarding the classification of lymphomas, subject of much discussion, the recommended one is that adopted in the WHO-EORTC (World Health Organization-European Organization for Research and Treatment of Cancer) consensus, which covers clinical, histological, immunohistochemical and molecular aspects.² This consensus was published in the WHO Blue Book in 2005 and subdivides the primary cutaneous B-cell lymphomas into: primary cutaneous follicle center lymphoma/ primary cutaneous marginal zone lymphoma/ primary cutaneous diffuse large B-cell lymphoma - leg type/ primary cutaneous diffuse large B-cell lymphoma - others/ primary cutaneous intravascular large B-cell lymphoma. In this case, it is large B-cell lymphoma, leg type. Based on the definition of "primary cutaneous", there should be no extra-

cutaneous clinical manifestations for 6 months after primary diagnosis in the skin.³

B-cell lymphomas account for 20-25% of the primary cutaneous lymphomas. According to the EORTC, there is a slight prevalence in males, with a median age of 59 years at diagnosis. Clinically, they present as papules or nodules of monomorphic appearance. As for the specific subtype of primary large cells - leg type, it usually affects elderly women. A histopathological examination may show reactive lymphoid follicles resembling germinal centers, thus complicating the differential diagnosis of pseudolymphoma. Immunohistochemistry is essential to the diagnosis and positive CD 20, CD 79 and Ki 67 markers in 80% of the analyzed cells support the B-cell lineage. In the differentiation of T lymphocytes, CD 3 and CD 45RO markers would be positive.

As for the prognosis, survival ranges from 36% to 100% in 5 years. The involvement of both lower limbs or the presence of multiple lesions confer worse future prospect. The treatment of choice is chemotherapy, with frequent relapses in the case of multiple initial lesions. When there is a single lesion, radiotherapy can be considered. Systemic use of anti-CD20 antibody (Rituximab[®]) alone or in combination with chemotherapy appears to improve survival of patients.⁶ □

Abstract: A fifty-five year old Caucasian male presented with infiltrated plaques and nodules on the left leg. The lesions had been present for 6 months. He presented associated cardiopathy, nephropathy and endocrinopathy. Histopathological and immunohistochemical examinations confirmed the diagnosis of cutaneous diffuse B cell lymphoma. CD 20, CD 79a and Ki-67 were positive. Chemotherapy with cyclophosphamide, adriamycin and vincristine promoted partial remission.

Keywords: Immunohistochemistry; Leg; Lymphoma, Primary Cutaneous Anaplastic Large Cell; Perna

Resumo: Paciente do sexo masculino de 55 anos com placas e nódulos infiltrados exuberantes em membro inferior esquerdo há seis meses. Cardiopatia, nefropatia e endocrinopatia associadas. O exame histopatológico, acrescido da imunohistoquímica, confirma linfoma cutâneo difuso de células B. Marcadores CD-20, CD-79a e Ki-67 foram positivos. A quimioterapia com ciclofosfamida, adriamicina e vincristina promoveu remissão parcial.

Palavras-chave: Imunohistoquímica; Linfoma anaplásico cutâneo primário de células grandes; Perna (Organismo); Pernas

REFERENCES:

1. Sampaio SAP, Rivitti EA. Dermatologia. 2. ed. São Paulo: Artes Médicas, 2001. p. 900.
2. Shaikh AJ, Masood N, Ahsan A, Memon W. Primary cutaneous B cell lymphoma-leg type (NEW EORTC--WHO classification), with nasal sinuses involvement. Pak Med Assoc. 2008;58:274-6.
3. Willemze R, Kerl H, Sterry W, Berti E, Cerroni L, Chimenti S, et al. EORTC classification for primary cutaneous lymphomas: a proposal from the Cutaneous Lymphoma Study Group of the European Organization for Research and Treatment of Cancer. Blood. 1997;90:354-71.
4. Burg G, Kerl H, Schmoekel C. Differentiation between malignant B-cell lymphomas and pseudolymphomas of the skin. J Dermatol Oncol. 1984;10:271-5.
5. Abbas AK, Lichtman AH, Pober JS. Lymphocyte maturation and expression of antigen receptor genes. Philadelphia: W. B. Saunders; 2000. p.125-60.
6. Moricz CZM, Sanches Júnior JA. Processos linfoproliferativos da pele. Parte 1. Linfomas cutâneos de células B. An Bras Dermatol. 2005;80:461-71.

MAILING ADDRESS / ENDEREÇO PARA CORRESPONDÊNCIA:

Cristina Paula Salaro
 SGAS 607 – Ed. Metrôpolis – Sala 128
 70200-670 Brasília - DF, Brazil
 E-mail: dermatologic@hotmail.com

How to cite this article/Como citar este artigo: Salaro CP, Tchernev G. Case for diagnosis. Cutaneous diffuse B-cell lymphoma. An Bras Dermatol. 2011;86(4):815-824.