



CASE REPORT

Cutaneous smooth muscle tumors associated with Epstein-Barr virus in an adult patient with HIV^{☆,☆☆}



Estefania Galeano-Piedrahita ^{ID}*, Ana Maria Maya Rico ^{ID},
Ana Cristina Ruiz Suárez ^{ID}, Andrea Laverde Walter ^{ID}

Dermatology Service, CES University, Medellín, Antioquia, Colombia

Received 2 March 2020; accepted 21 June 2020
Available online 4 February 2021

KEYWORDS

Epstein-Barr virus infections;
HIV;
Skin manifestations;
Smooth muscle tumor

Abstract Epstein Barr virus-associated smooth muscle tumors are an uncommon neoplasm that occurs in immunosuppressed patients of any age. Usually, it presents as multifocal tumors mainly in the spinal cord, epidural region, gastrointestinal tract and liver, upper respiratory tract and skin, the latest with few cases reported in the literature and related with human immunodeficiency virus infection and acquired immune deficiency syndrome. The authors present the first case of a Colombian adult patient with human immunodeficiency virus infection and multifocal Epstein Barr virus-associated smooth muscle tumors in the skin and epidural region, confirmed by histopathology, immunohistochemistry and in situ hybridization studies.

© 2021 Sociedade Brasileira de Dermatologia. Published by Elsevier España, S.L.U. This is an open access article under the CC BY license (<http://creativecommons.org/licenses/by/4.0/>).

Introduction

Epstein-Barr virus (EBV)-associated smooth muscle tumors are a rare neoplasm associated with immunosuppression.¹

Their relationship with EBV has been studied extensively for more than 20 years and they have been documented in both pediatric and adult patients, with a slight female predominance.^{2,3} Skin manifestations are uncommon and have been related to patients with human immunodeficiency virus (HIV) infection.⁴ The following report describes a confirmed case of a patient with HIV and presence of multifocal cutaneous and epidural smooth muscle neoplasms.

Case report

40-year-old male patient with a diagnosis of HIV infection since 2006 in low-adherence antiretroviral therapy, who presents a two-year history of the appearance of four

[☆] How to cite this article: Galeano-Piedrahita E, Rico AMM, Suárez ACR, Walter AL. Cutaneous smooth muscle tumors associated with Epstein Barr virus in an adult patient with HIV. *An Bras Dermatol.* 2021;96:184–7.

^{☆☆} Study conducted at the CES University, Medellín, Antioquia, Colombia.

* Corresponding author.
E-mail: estefaniadermatologia@gmail.com (E. Galeano-Piedrahita).

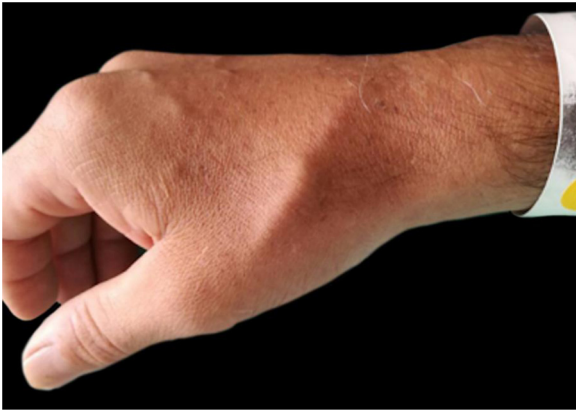

Figure 1 Linear subcutaneous nodule on the dorsum of the right hand.

painful, slow-growing lesions in the limbs and abdomen, associated with low back pain. The physical examination showed well defined subcutaneous nodules, mobile, of a rubbery consistency and very painful, located in the left forearm (1×1.5 cm), abdomen (0.5×0.5 cm), left thigh (1×0.5 cm), and one of larger size and linear shape on the dorsum of the right hand (2×1 cm) (Fig. 1). Within the relevant laboratory, 2,200 leukocytes, 920 lymphocytes, with CD4 of 6 cells/mcL and a viral load of 36,600 copies are reported. In the magnetic resonance imaging (MRI) of the contrasted spine, an extensive epidural infiltration with foraminal involvement of T4-T5, T7, T11, and T12 with compression and displacement of the spinal cord is evident

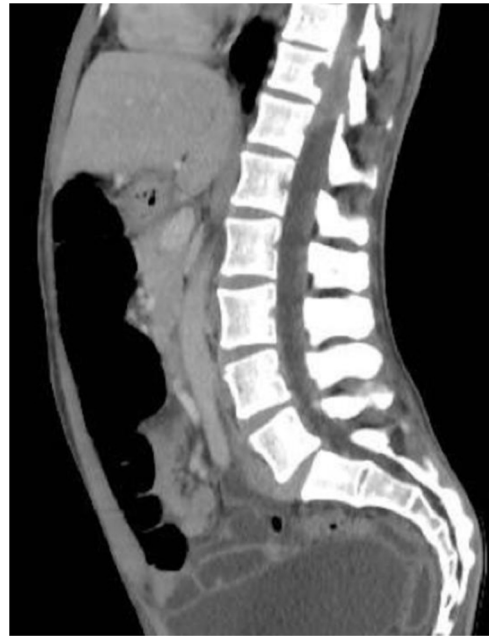

Figure 2 Nuclear magnetic resonance of the spine with epidural infiltration and foraminal involvement of T11 and T12, with compression and displacement of the spinal cord.

(Fig. 2). A biopsy of one of the skin lesions (Fig. 3) and of the epidural mass (Fig. 4) were taken with findings similar to histology, finding a positive fusocellular neoplasm for

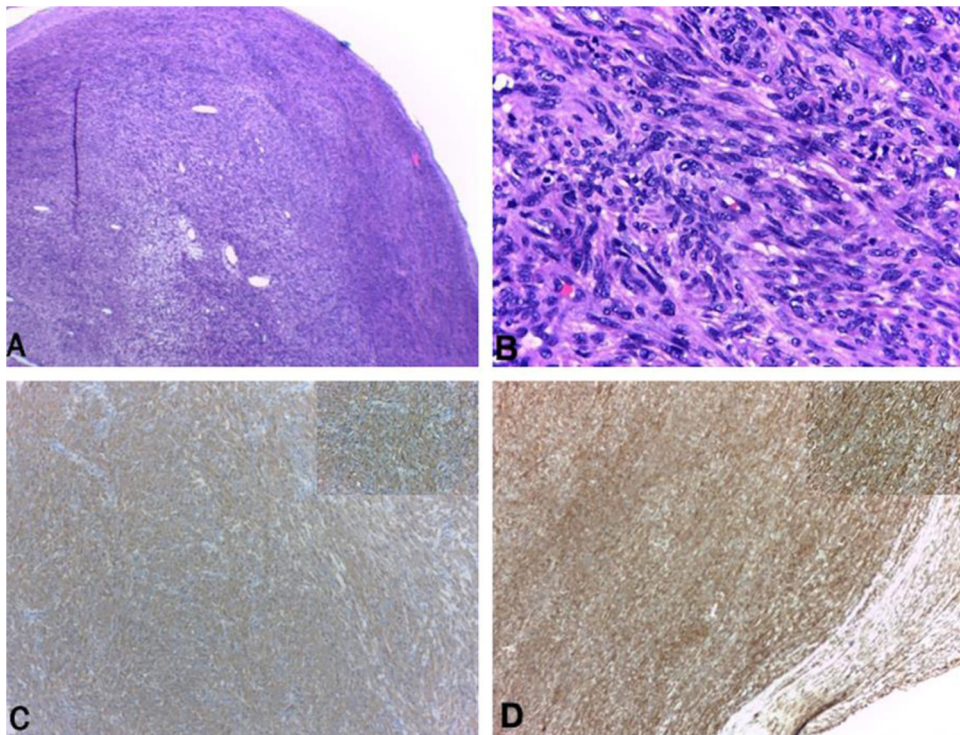


Figure 3 Subcutaneous nodule. (A and B), well circumscribed nodular formation formed by spindle cell bundles with minimal atypia and few mitotic figures (Hematoxylin & eosin $\times 100$ and $\times 400$, respectively). (C and D), SMA and H-caldesmon positive immunohistochemistry, respectively.

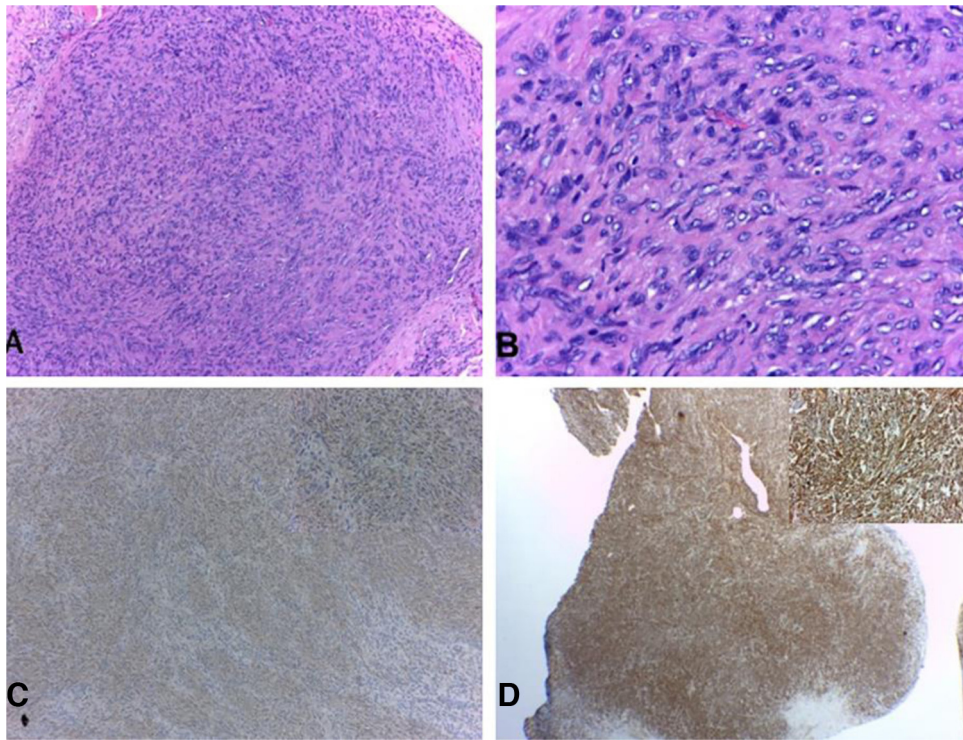


Figure 4 Epidural lesion. (A and B), confused lesion by spindle cell bundles with low atypia (Hematoxylin & eosin $\times 100$ and $\times 400$, respectively). (C and D), SMA and H-caldesmon positive immunohistochemistry, respectively.

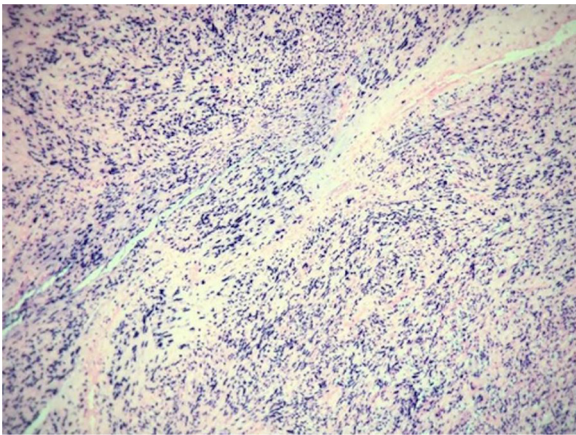


Figure 5 *In situ* hybridization study for detection of Epstein-Barr virus.

H-caldesmon and smooth muscle actin (SMA) a diagnosis of smooth muscle tumor. Subsequently, an *in situ* hybridization study was performed for the detection of the Epstein-Barr virus encoding region (EBER), which was positive (Fig. 5).

Discussion

The relationship between smooth muscle tumors and immunosuppression was first documented in 1970 by Pritzker et al., and it was only in 1995 that their link to EBV was identified.^{2,5} This association has been established in post-transplanted patients, with primary immunodeficiencies and HIV, mainly in those with CD4 less than 200

cells/ μL .⁶ The majority present multifocal compromise, as in the case of the current patient, with a predominance in the spinal cord, epidural space, gastrointestinal tract and liver, upper respiratory tract, and skin, the latter organ having few cases reported in the literature and none in Colombia.^{1,3,4}

Although its pathogenesis is poorly understood, it has been suggested that EBV infects smooth muscle cells directly by adhering to CD21 facilitating the replication of these cells.² Other theories are based on the overexpression of the proto-oncogene MYC and the activation of the Akt/mTOR pathway triggered by the LMP2A protein, which promotes cell proliferation and tumor formation.^{7,8}

The diagnosis is made based on physical examination, radiology, and findings in the histological and immunohistochemical study; it is confirmed with *in situ* hybridization study for the detection of the Epstein-Barr virus, as was done in the representative case.⁹ The presence of these lesions in the central nervous system has been associated with a worse prognosis; regarding treatment, there are some case reports of reversal of the neoplasms with the improvement of immunosuppression, surgical resection for isolated lesions have been published, and the use of radiotherapy and chemotherapy such as sirolimus.³ However, most reports are in patients without HIV infection and the results have not been completely satisfactory.^{1,10}

Financial support

None declared.

Authors' contributions

Estefania Galeano-Piedrahita: Approval of the final version of the manuscript; study conception and planning; preparation and writing of the manuscript; data collection, analysis, and interpretation; effective participation in research orientation; intellectual participation in propaedeutic and/or therapeutic conduct of studied cases; critical review of the literature; critical review of the manuscript.

Ana Maria Maya Rico: Approval of the final version of the manuscript; study conception and planning; preparation and writing of the manuscript; data collection, analysis, and interpretation; effective participation in research orientation; intellectual participation in propaedeutic and/or therapeutic conduct of studied cases; critical review of the literature; critical review of the manuscript.

Ana Cristina Ruiz Suárez: Approval of the final version of the manuscript; study conception and planning; preparation and writing of the manuscript; data collection, analysis, and interpretation; effective participation in research orientation; intellectual participation in propaedeutic and/or therapeutic conduct of studied cases; critical review of the literature; critical review of the manuscript.

Andrea Laverde Walter: Approval of the final version of the manuscript; study conception and planning; preparation and writing of the manuscript; data collection, analysis, and interpretation; effective participation in research orientation; intellectual participation in propaedeutic and/or therapeutic conduct of studied cases; critical review of the literature; critical review of the manuscript.

Conflicts of interest

None declared.

References

1. Dekate J, Chetty R. Epstein-Barr virus-associated smooth muscle tumor. *Arch Pathol Lab Med.* 2016;140:718–22.
2. McClain KL, Leach CT, Jenson HB, Joshi VV, Pollock BH, Parmley RT, et al. Association of Epstein-Barr virus with leiomyosarcomas in young people with AIDS. *N Engl J Med.* 1995;332:12–8.
3. Issarachaikul R, Shuangshoti S, Suankratay C. Epstein-Barr virus-associated smooth muscle tumors in AIDS patients: a largest case (series). *Intern Med.* 2014;53:2391–6.
4. Purgina B, Rao UNM, Miettinen M, Pantanowitz L. AIDS-related EBV-associated smooth muscle tumors: a review of 64 published cases. *Patholog Res Int.* 2011;2011:561548.
5. Pritzker KP, Huang SN, Marshall KG. Malignant tumours following immunosuppressive therapy. *Can Med Assoc J.* 1970;103:1362–5.
6. Suankratay C, Shuangshoti S, Mutirangura A, Prasanthai V, Lerdlum S, Shuangshoti S, et al. Epstein-Barr virus infection-associated smooth-muscle tumors in patients with AIDS. *Clin Infect Dis.* 2005;40:1521–8.
7. Jenson HB, Montalvo EA, McClain KL, Ench Y, Heard P, Christy BA, et al. Characterization of natural Epstein-Barr virus infection and replication in smooth muscle cells from a leiomyosarcoma. *J Med Virol.* 1999;57:36–46.
8. Moody CA, Scott RS, Amirghahari N, Nathan C-A, Young LS, Dawson CW, et al. Modulation of the cell growth regulator mTOR by Epstein-Barr virus-encoded LMP2A. *J Virol.* 2005;79:5499–506.
9. Delecluse H-J, Feederle R, O'Sullivan B, Taniere P. Epstein Barr virus-associated tumours: an update for the attention of the working pathologist. *J Clin Pathol.* 2006;60:1358–64.
10. Toh HC, Teo M, Ong KW, Lee V, Chan E, Lee AS, et al. Use of sirolimus for Epstein-Barr virus-positive smooth-muscle tumour. *Lancet Oncol.* 2006;7:955–7.