

An unusual case of extragenital primary syphilis*



Dear Editor,

A twenty-eight year old man with no relevante personal history, sought a Dermatology consultation due to the appearance of an asymptomatic lesion on the right hand. The clinical history revealed the appearance of a pinkish papule, two months before, with progressive growth and subsequent ulceration, with no history of local trauma or similar lesions in the past.

The objective examination identified a painless ulcer, measuring 5 × 5 mm, on the dorsal side of the third finger of the right hand, with a bright red base and raised pinkish infiltrated borders (Fig. 1). No local adenopathies were identified and the remaining clinical examination showed no alterations.

Histopathology of a punch biopsy on the lesion border revealed a dense perivascular and interstitial lymphoplasmacytic infiltrate; immunohistochemical evaluation with anti-treponemal antibody staining showed massive epidermal, adnexal and vascular spirochete infiltration (Fig. 2). Laboratory assessment disclosed a positive FTA-ABS test and a VDRL title of 1/64. Serologies for the remaining sexually transmitted infections (HIV, hepatitis B and hepatitis C) were negative.

A diagnosis of primary extragenital syphilis was established and the patient was medicated with intramuscular benzathine penicillin G (2.4 million IU), in a single dose, with complete resolution of the lesion in the following weeks.

Discussion

Syphilis is an infection caused by the spirochete *Treponema pallidum* subsp. *pallidum*. The main method of transmission involves skin or mucous membrane contact with an infectious lesion, usually through sexual contact. The remaining cases correspond mostly to vertical transmission of the disease.¹

Primary syphilis manifests through one or more asymptomatic ulcers at the site of inoculation, with characteristics similar to those described in the clinical case presented here, usually accompanied by local adenopathies. The lesion appears after a mean incubation period of three weeks (10–90 days), and the most common site for its development is the anogenital region.² In the absence of treatment, healing occurs after a few weeks and about one-third of the patients develop manifestations of secondary syphilis later on.²

Extragenital primary syphilis is a rare event, corresponding to 2%–7% of reported cases,³ with the oral cavity being the most frequently affected area.^{2,4} The natural history, treatment, and prognosis of primary lesions do not depend on their location.

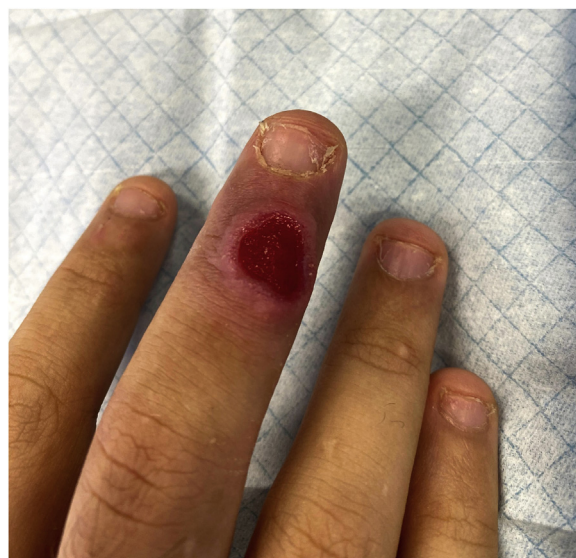

Figure 1 Ulcer on the third finger of the right hand.

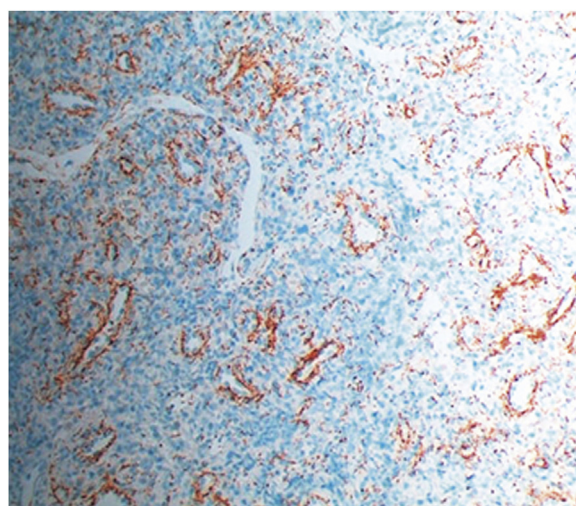


Figure 2 Evaluation by immunohistochemistry with anti-treponemal antiserum in the skin sample (×200).

The clinical differential diagnosis of extragenital lesions is extensive and should be guided by the clinical history. Cutaneous mycobacteriosis, herpetic infections, cutaneous leishmaniasis, and squamous cell carcinoma are conditions that must be taken in consideration.

The diagnosis is often made through a combination of clinical history, physical examination, and treponemal and non-treponemal serological tests. In this case, a skin biopsy was performed due to the atypical location of the lesion to exclude other etiologies. Direct darkfield examination and polymerase chain reaction (PCR) assessment are other diagnostic methods used sometimes.²

This clinical case illustrates a rare presentation of primary syphilis and demonstrates the importance of this differential diagnosis in lesions with the aforementioned characteristics, regardless of their location.

* Study conducted at the Service of Dermatovenereology, Hospital de Santo António dos Capuchos, Centro Hospitalar Universitário de Lisboa Central, Lisbon, Portugal.

Financial support

None declared.

Authors' contributions

Miguel Santos Coelho: Data survey, data analysis and interpretation; drafting and editing of the manuscript; collection, analysis, and interpretation of data; intellectual participation in the propaedeutic and/or therapeutic conduct of the studied cases; critical review of the literature; approval of the final version of the manuscript.

Joana Alves Barbosa: Data survey, data analysis and interpretation; drafting and editing of the manuscript; collection, analysis, and interpretation of data; intellectual participation in the propaedeutic and/or therapeutic conduct of the studied cases; critical review of the literature; approval of the final version of the manuscript.

Margarida Moura Valejo Coelho: Critical review of the literature; approval of the final version of the manuscript.

Alexandre João: Data survey, data analysis and interpretation; collection, analysis, and interpretation of data; intellectual participation in the propaedeutic and/or therapeutic conduct of the studied cases; approval of the final version of the manuscript.

Conflicts of interest

None declared.

References

1. Forrestel AK, Kovarik CL, Katz KA. Sexually acquired syphilis: historical aspects, microbiology, epidemiology, and clinical manifestations. *J Am Acad Dermatol.* 2020;82:1–14.
2. Janier M, Unemo M, Dupin N, Tiplica GS, Potočník M, Patel R. 2020 European guideline on the management of syphilis. *J Eur Acad of Dermatol Venereol.* 2020;35:574–88.
3. Eccleston K, Collins L, Higgins SP. Primary syphilis. *Int J STD AIDS.* 2008;19:145–51.
4. Drago F, Ciccarese G, Cogorno L, Tomasini CF, Cozzani EC, Riva SF, et al. Primary syphilis of the oropharynx: an unusual location of a chancre. *Int J STD AIDS.* 2014;26:679–81.

Miguel Santos-Coelho *, Joana Alves Barbosa , Margarida Moura Valejo Coelho , Alexandre João 

Service of Dermatovenereology, Hospital de Santo António dos Capuchos, Centro Hospitalar Universitário de Lisboa Central, Lisbon, Portugal

* Corresponding author.

E-mail: mscoelho.derma@gmail.com (M. Santos-Coelho).

Received 6 August 2022; accepted 6 September 2022

Available online 6 December 2023

<https://doi.org/10.1016/j.abd.2022.09.018>

0365-0596/ © 2023 Sociedade Brasileira de Dermatologia.

Published by Elsevier España, S.L.U. This is an open access article under the CC BY license (<http://creativecommons.org/licenses/by/4.0/>).

Hypertrophic scar mimicking peristomal pyoderma gangrenosum[☆]



Dear Editor,

Peristomal Pyoderma Gangrenosum (PPG) is a subtype of pyoderma gangrenosum, arising around the stoma after surgical placement of an ileostomy or colostomy in patients with inflammatory bowel diseases.¹ Because there are a number of skin disorders involving the peristomal or parastomal areas, PPG may be overdiagnosed.² We herein describe an unusual case presenting with hyperkeratotic lesions around the stoma in a patient after colorectal cancer surgery.

A 78-year-old male after colorectal cancer surgery was referred to us, complaining of hypertrophic lesions surrounding the stoma. He received a colostomy 6-months previously, and peristomal skin lesions gradually worsened in these 2-months. He suffered from exudate from the lesions and pain associated with skin infections. Physical examination showed relatively well-circumscribed vegetating and kera-

totic lesions around the lower left abdominal stoma (Fig. 1). No abnormalities were found in the blood test.

Histological features showed irregular hypertrophy of the epidermis, with dilated blood vessels in the papillary dermis and edematous upper dermis (Fig. 2A). Neutrophil infiltration and histological malignancy were not observed. Immunohistochemistry showed dense staining for vimentin in the mesenchymal cells in the dermis (Fig. 2B). CD31 staining showed a number of vessels, and CD31-positive vascular endothelial cells were observed throughout the dermis (Fig. 2C). α -Smooth Muscle Actin (SMA)-positive myofibroblasts were proliferated (Fig. 3A), which were partially positive for p16 (Fig. 3B). A diagnosis of hypertrophic scar was made, and the patient received reoperation of the stoma including the surrounding skin lesions.

Peristomal pyoderma gangrenosum is a subtype of pyoderma gangrenosum, arising around the stoma in patients with inflammatory bowel diseases, and is observed in around 1% of patients with stoma.¹ By contrast, it is also suggested that PPG is overdiagnosed from its clinical features.² Currently, there are no standard diagnostic criteria, and there are several conditions that should be differentiated from PPG. Those conditions include irritant and contact dermatitis, infection, overgranulation, pseudo verrucous lesion, and squamous cell carcinoma.³ In addition, other reports showed two cases of peristomal ulcerative conditions, which were eventually reclassified to be caused by irritant dermatitis;⁴

[☆] Study conducted at the Department of Dermatology, Fukushima Medical University, Hikarigaoka, Fukushima, Japan.