

Authors' contributions

Camilo Arias-Rodriguez: Study concept and design; data collection, analysis and interpretation; writing of the manuscript; critical review of the literature; final approval of the final version of the manuscript.

Juan Guillermo Hoyos-Gaviria and Ana Maria Muñoz-Monsalve: Study concept and design; effective participation in the research guidance; critical review of important intellectual content; final approval of the final version of the manuscript.

Alejandro Hernandez-Martinez: Study concept and design; data analysis and interpretation; writing of the manuscript; critical review of the literature; final approval of the final version of the manuscript.





Conflicts of interest

None declared.

References

1. Errichetti E, Stinco G. Pityriasis lichenoides. In: Micali G, Lacarubba F, Stinco G, Argenziano G, Neri I, editors. Atlas of pediatric dermatoscopy. Berlin: Springer; 2018. p. 1–2.
2. Clarey DD, Lauer SR, Trowbridge RM. Clinical, dermatoscopic, and histological findings in a diagnosis of pityriasis lichenoides. *Cureus*. 2020;12:e8725.

3. Ankad BS, Beergouder SL. Pityriasis lichenoides et varioliformis acuta in skin of color: new observations by dermoscopy. *Dermatol Pract Concept*. 2017;7:27–34.
4. Lacarubba F, Micali G. Dermoscopy of pityriasis lichenoides et varioliformis acuta. *Arch Dermatol*. 2010;146:1322.
5. Bhut A, Shah A, Nair PA. Dermatoscopic findings of pityriasis lichenoides et varioliformis acuta. *Indian J Paediatr Dermatol*. 2020;21:249–50.

Camilo Arias-Rodriguez  ^a,
Juan Guillermo Hoyos-Gaviria  ^b,
Ana Maria Muñoz-Monsalve  ^c,
Alejandro Hernandez-Martinez  ^{d,*}

^a Department of Dermatology, Universidad Pontificia Bolivariana, Medellin, Colombia

^b Department of Dermatology, Specialized Diagnostic Clinic VID, Medellin, Colombia

^c Department of Dermatology, Aurora Specialized Center for Skin Cancer, Medellin, Colombia

^d Faculty of Medicine, Universidad Pontificia Bolivariana, Medellín, Colombia

* Corresponding author.

E-mail: alejo.hdz@hotmail.com (A. Hernandez-Martinez).

Received 16 March 2022; accepted 22 April 2022

Available online 1 September 2023

<https://doi.org/10.1016/j.abd.2022.04.017>

0365-0596/ © 2023 Sociedade Brasileira de Dermatologia.

Published by Elsevier España, S.L.U. This is an open access article under the CC BY license (<http://creativecommons.org/licenses/by/4.0/>).

Extensive Nicolau syndrome following intramuscular diclofenac sodium injection*



Dear Editor,

Nicolau syndrome (NS), or embolia cutis medicamentosa, is vascular occlusion with necrosis of the skin and underlying tissues, related to the use of medications such as beta-lactam antimicrobials, non-steroidal anti-inflammatory drugs (NSAIDs) and, more recently, hyaluronic acid fillers.

A 66-year-old male patient reported erythema and ecchymosis on the left lower limb, 24 hours after an intramuscular injection (left gluteus) of diclofenac sodium for abdominal pain. There was rapid progression to tense blisters over the entire limb, with severe pain and edema.

Four days later, the patient came to the emergency room with rectilinear purpuric areas all over the left lower limb, tense blisters with serosanguineous content, and ulcerated areas (Fig. 1A).

The hypothesis of NS due to intramuscular sodium diclofenac injection was considered. Laboratory investiga-

tion for systemic vasculitis with antinuclear antibody (ANA), anti-DNA, extractable nuclear antigen (ENA), cryoglobulins and complement was negative.

The lesions worsened (Fig. 1B), and the patient was transferred to the Intensive Care Unit and received parenteral antibiotic therapy (vancomycin and meropenem). After clinical stabilization, surgical debridement sessions were performed (Fig. 2) with subsequent grafting (Fig. 3). After three months and four surgical approaches for debridement and grafting, the patient was discharged in good general condition.

NS was first described in 1924 after an intragluteal injection of bismuth salts for the treatment of syphilis. It occurs after the intramuscular injection of insoluble substances, occurring more frequently with benzathine penicillin and NSAIDs (such as diclofenac).¹ Diclofenac-induced cases are more common in females, whereas penicillin-induced cases are more common in children.²

Theories about its etiopathogenesis involve a combination of factors: stimulation of sympathetic innervation with vasospasm and ischemia; blockade of prostaglandin synthesis by NSAIDs, arterial embolic occlusion by inadvertent intravascular injection; perivascular inflammation due to cytotoxic drug reaction; mechanical injury caused by lipophilic drugs penetrating the vessels.^{2,3}

The clinical picture consists of an erythematous macule with rapid evolution to a livedoid violaceous patch. The

* Study conducted at the Department of Dermatology, Universidade Federal de São Paulo, São Paulo, SP, Brazil.

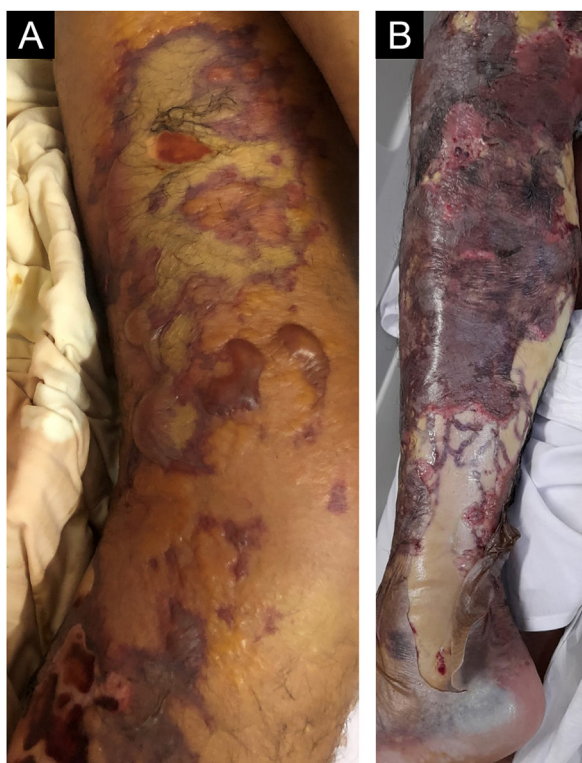

Figure 1 (A) Violaceous, rectilinear lesions with areas of skin detachment on the thigh and leg. Areas of necrosis with an erythematous halo are also observed. (B) Progression of the necrosis areas seven days after symptom onset

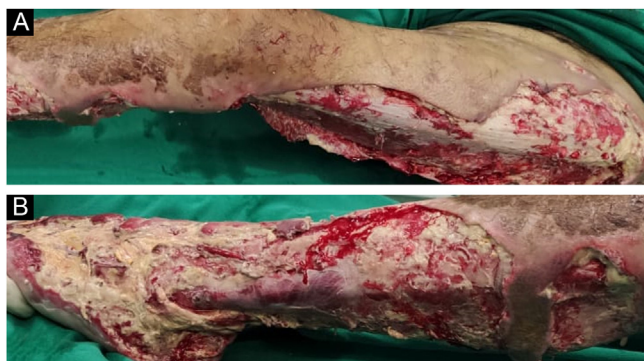

Figure 2 After 30 days, in the postoperative period of the first surgical debridement on the left thigh (A) and left leg (B)

onset is usually sudden in relation to the injection but can be delayed, often without injury to the injected site.⁴ The prognosis is unpredictable, with reports of recovery and atrophic scarring at the affected site but also compartment syndrome, hyperkalemia, renal failure, paralysis of the affected limb, and death.^{3,5} The diagnosis is clinical, highly suggestive when the lesion starts at the injection site, with distal progression over the injected limb. Histopathology is non-specific and may reveal fatty tissue necrosis and inflammation.⁵

There is no specific treatment, and analgesia, treatment of secondary infection, and surgical debridement are employed.¹ The correct intramuscular injection technique can reduce the risk of the condition.⁴ The Z-track injection

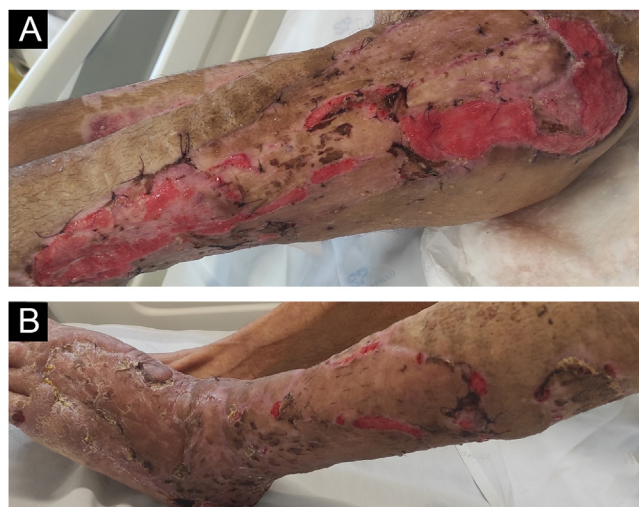

Figure 3 Three months after the onset of the condition, the patient shows good aesthetic and functional recovery in the (A) right thigh and hip and (B) right leg and dorsum of the right foot after multiple skin grafts

method is recommended, with traction of the skin and subcutaneous tissue prior to needle insertion, ensuring blockage of the needle path after the injection.¹

Although rare, NS can be extensive and severe. Physicians must be aware of the condition, as well as aware of the correct injection technique, and avoid unnecessary intramuscular prescriptions.

Financial support

None declared.

Authors' contributions

Rafael Oliveira Amorim: Drafting and editing of the manuscript and critical review of important intellectual content; study design together with the co-authors; critical review of the literature; approval of the final version of the manuscript.

Alana Luísa Calixto Carlos da Silva: Drafting and editing of the manuscript and critical review of important intellectual content; study design together with the co-authors; approval of the final version of the manuscript.

Camila Arai Seque: Drafting and editing of the manuscript and critical review of important intellectual content; study design together with the co-authors; approval of the final version of the manuscript.





Adriana Maria Porro: Drafting and editing of the manuscript and critical review of important intellectual content; study design together with the co-authors; approval of the final version of the manuscript.

Conflicts of interest

None declared.

References

- Lardelli PF, Jermini LMM, Milani GP, Peeters GGAM, Ramelli GP, Zraggen L, et al. Nicolau syndrome caused by non-steroidal anti-inflammatory drugs: Systematic literature review. *Int J Clin Pract.* 2020;74:e13567.
- Aktas H, Yılmaz OE, Ertugrul G, Terzi E. Intramuscular diclofenac is a cause of Nicolau syndrome in obese women: An observational study of consecutive ten patients. *Dermatol Ther.* 2020;33:e13392.
- Shelley B, Prasad P, Manjunath M, Chakraborti S. Hyperacute paraplegia and neurovascular (immuno vasculotoxic) catastrophe of nicolau syndrome: Primum non nocere. *Ann Indian Acad Neurol.* 2019;22:104.
- Silva AMM, Ton A, Loureiro TF, Agrizzi BL. Late development of Nicolau syndrome - Case report. *An Bras Dermatol.* 2011;86:157–9.
- Marcus F, Claude EV, Josephine M, Teyang A. An exceptional cause of acute limb ischemia: Nicolau syndrome-single-center experience with 4 cases. *Ann Vasc Surg.* 2019;58:383.

Rafael Oliveira Amorim *,
Alana Luísa Calixto Carlos da Silva ,
Camila Arai Seque , Adriana Maria Porro 

Department of Dermatology, Universidade Federal de São Paulo, São Paulo, SP, Brazil

* Corresponding author.

E-mail: amorimdermatologia@gmail.com (R.O. Amorim).

Received 24 March 2022; accepted 3 June 2022

Available online 22 September 2023

<https://doi.org/10.1016/j.abd.2022.06.010>

0365-0596/ © 2023 Sociedade Brasileira de Dermatologia.

Published by Elsevier España, S.L.U. This is an open access article under the CC BY license (<http://creativecommons.org/licenses/by/4.0/>).

Lipschutz's vulvar ulcer in an adolescent after Pfizer COVID-19 vaccine[☆]



Dear Editor,

Lipschütz's acute vulvar ulceration is a non-sexually acquired condition, which is characterized by a sudden onset of a few necrotic and painful genital ulcers. Self-resolution without scarring and relapses is the usual course.¹ The underlying pathogenesis of vulvar aphthous ulcers is unclear. Numerous case reports have described aphthous ulcers as a dysregulated immune response associated with a variety of infections including Cytomegalovirus (CMV), influenza, mumps virus, salmonella, mycoplasma and most notably Epstein Barr Virus (EBV).²

Over 334,000,000 doses of the Moderna, Pfizer and Johnson & Johnson vaccines have been administered since December 2020. Side effects are common and have been widely reported. Most of the systemic side effects after receiving the Pfizer COVID-19 vaccine as headache, fatigue, chills, diarrhea, fever and myalgias are well-known.³ However, skin manifestations are not as well studied.⁴ In this brief report, the authors present the case of a patient presenting with vulvar aphthous ulcer following Pfizer COVID-19 vaccination.

A 13-year-old girl, with no relevant personal history, started with fever, myalgias, and intense pain in her genitals 48 hours after having been vaccinated with the second dose of the COVID-19 vaccine (Pfizer).

After being explored, fibrinous kissing ulcers were observed on the vulva (Fig. 1).

The patient denied initiation of sexual intercourse and had had the menarche a year ago with regular menstruations that did not coincide with the ulcers.

Exudated cultures and PCRs for herpes viruses 1 and 2, treponema, and mycoplasma of the vulva were negative. Serological tests including HIV, Epstein Barr virus and antinuclear antibodies were also negative. The patient also

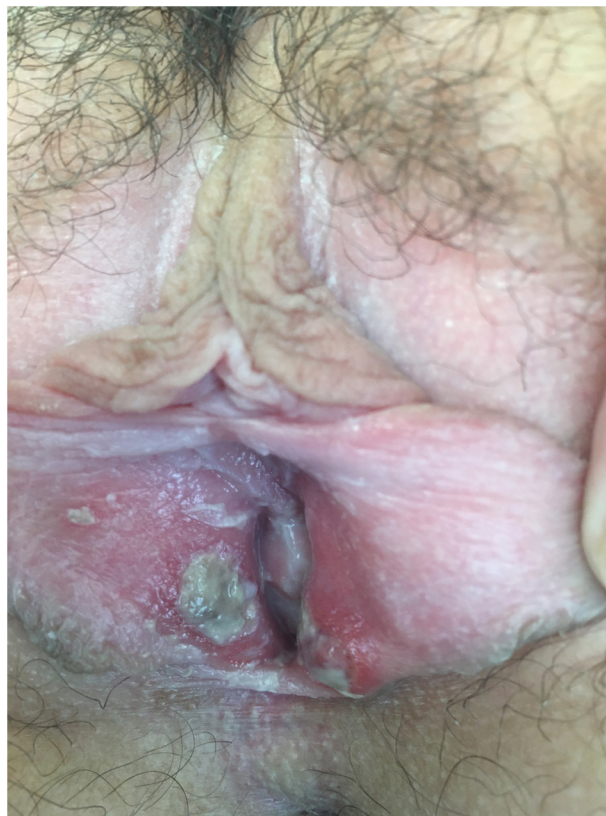

Figure 1 Fibrinous kissing ulcers on the vulva.

[☆] Study conducted at the Department of Dermatology, Hospital Universitario Virgen de Valme, Sevilla, Spain.