

Childhood Pustular Psoriasis – A Case Report*

Psoríase Pustulosa da Infância – Relato de Caso

Yuri Nogueira Chaves¹
Priscila F. Landulfo Jorge³
Maria de Fátima Paim de Oliveira⁵

Dulceane Natyara Cardoso²
Ivonise Follador⁴

Abstract: Generalized pustulous psoriasis is a rare type of psoriasis first described in 1910 by Von Zumbusch. This disease tends to have a more benign development in children when compared to its development in adults. However, in its serious form it may represent a risk to the patient's life. Maybe, due to being such a rare disease no therapeutic option has so far consistently proved to be both effective and safe. Isolated reports suggest that retinoid is the best choice of drug in these cases. However, it is difficult to manage this drug in early infancy. The present report describes a serious case of this rare disease in an infant with a satisfactory response and good tolerance to the use of dapsona.

Keywords: Child; Dapsona; Psoriasis; Therapeutics

Resumo: A psoríase pustulosa generalizada é tipo raro de psoríase descrita pela primeira vez, em 1910, por Von Zumbusch. A psoríase pustulosa generalizada na criança tende a ter um curso mais benigno que no adulto, entretanto, em sua forma grave, pode por em risco a vida do paciente. Talvez, pela raridade da doença, nenhuma opção terapêutica se mostrou consistentemente eficaz e segura até o momento. Relatos isolados sugerem ser o retinoide a droga de escolha nesses casos, porém trata-se de fármaco que, na primeira infância, traz mais dificuldades no manejo. Relata-se exemplo dessa rara doença em lactente, quadro extenso e grave, com resposta satisfatória ao uso de dapsona, com boa tolerabilidade.

Palavras-chave: Criança; Dapsona; Psoríase; Terapêutica

INTRODUCTION

Generalized pustulous psoriasis (GPP) is a rare type of psoriasis first described in 1910 by Von Zumbusch and it is considered the most severe type of this illness.¹ Baker and Ryan² classified this type of psoriasis in four forms: von zumbusch, annular, exanthematous and localized (except for acral and palmo-plantar). None of these types are mutually exclusive. This generalized form of psoriasis is characterized by the development of subcorneal sterile pustules super-

imposed on erythematous basis¹. There are less than 200 cases of the von zumbusch form, in children³, described in medical literature. The report of this case is due not only to its rarity but also to its therapeutic challenge.

CASE REPORT

Male patient, aged 1 year and 8 months old, whose mother stated that since he was 2 months old

Received on 12.08.2008.

Approved by the Advisory Board and accepted for publication on 01.12.08.

* Work carried out in the Dermatological Service of the Professor Edgar Santos University Hospital Complex - The Federal University of Bahia - Department of Dermatology of the Federal University of Bahia (UFBA) - Salvador (BA), Brazil.

Conflict of interest: None / *Conflito de interesse: Nenhum*

Financial funding: None / *Suporte financeiro: Nenhum*

¹ Resident of the Dermatology Service of the Professor Edgar Santos University Hospital Complex – The Federal University of Bahia (UFBA) – Salvador (BA), Brazil.

² Undergraduate student of the Faculty of Medicine of the Federal University of Bahia- (UFBA) – Salvador (BA), Brazil.

³ Undergraduate student of the Faculty of Medicine of the Federal University of Bahia- (UFBA) – Salvador (BA), Brazil.

⁴ PhD degree in Dermatology from the Federal University of Bahia (UFBA) and preceptress of the Dermatological Service of the Professor Edgar Santos University Hospital Complex – The Federal University of Bahia (UFBA) - Salvador (BA), Brazil.

⁵ Master degree in Dermatology from the Federal University of Bahia (UFBA) and preceptress of the Dermatological Service of the Federal University of Bahia. Department of Dermatology of the Federal University of Bahia (UFBA) - Salvador (BA), Brazil.

he had presented pruritic punctated papules and pustules spread on his body, including genitalia, sparing mucous. The pustules tended to flow forming an area of pus on erythematous basis¹. The patient also presented fever and adynamia. The use of systemic antibiotics and corticosteroids would bring partial and temporary improvement on the condition but always followed by new episodes of recrudescence. It was also reported that the patient's father presented similar condition in childhood with spontaneous remission. Dermatologic exam showed erythematous plaques, desquamative, with generalized pustules and areas with melicerous crosts, with little area of integument spared. In some areas the erythematous plaques were bordered by pustules giving a circinate aspect to the lesions (Figures 1 and 2).

Among the relevant laboratoria exams were leukocytosis of 22.300 (Reference Value -RV: 5 to 10 thousand); anemia with hemoglobin of 10,8% (RV: > 12,5 to 17,5) and hematocrit of 31% (RV: 40 to 54%); platelets of 670 mil /mm³ (RV: 150 to 450 mil/mm³); erythrocyte sedimentation rate of 41 mm in the first hour (RV: 3 to 20) and C-reactive protein of 6 mg/L (RV: <6).

Histopathologic exam showed subcorneal vesicle keeping fibrino-leukocytic exudate in the light and epidermis showing acanthosis, with discreet hyperkeratosis and small areas of parakeratosis. There was mononuclear infiltrate with groups of neutrophils in the dermis. (Figures 3 and 4). This result was compatible with the clinical suspicion of pustulous psoriasis.

The patient was medicated with 5 mg dapsone

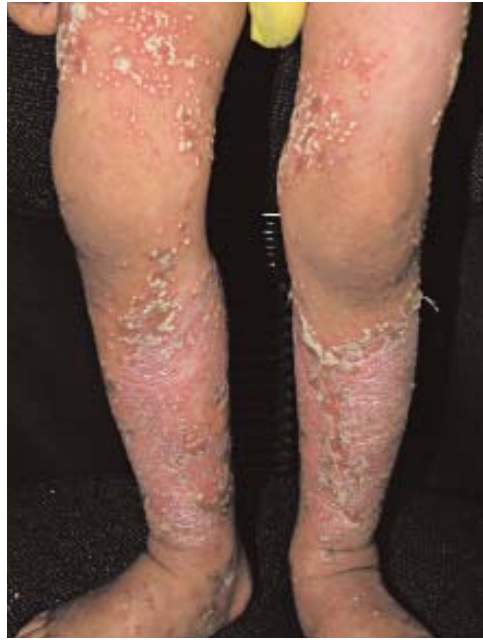

FIGURE 2: Desquamative plaques with numerous pustules superimposed on the lower limbs. (HE; 100X)

every 12 hours and 10 ml of ferrous sulfate daily. The condition evolved in three months with weight loss following the suspension of topic corticosteroid, resolution of fever and improvement in adynamia. There was partial regression of the previously mentioned lesions although new lesions appeared. The patient presented pustules with erythematous basis on the back, abdomen and thorax (Figures 5 and 6). Dapsone was kept and it was planned to introduce cyclosporin in case there was not a satisfactory response to the treatment.

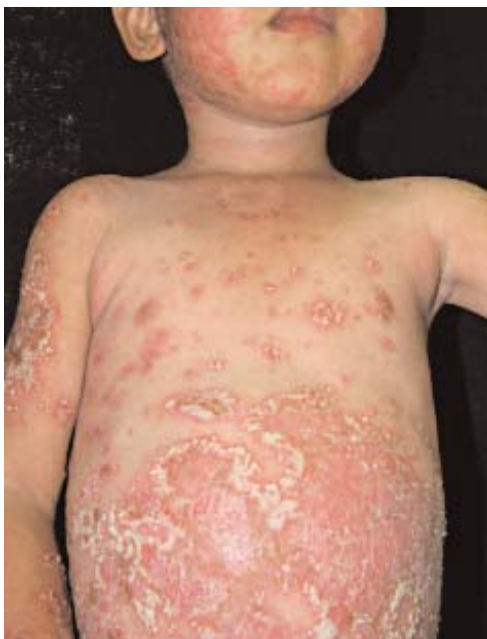

FIGURE 1: Erythematous plaques, desquamative, bordered by great number of pustules on the trunk

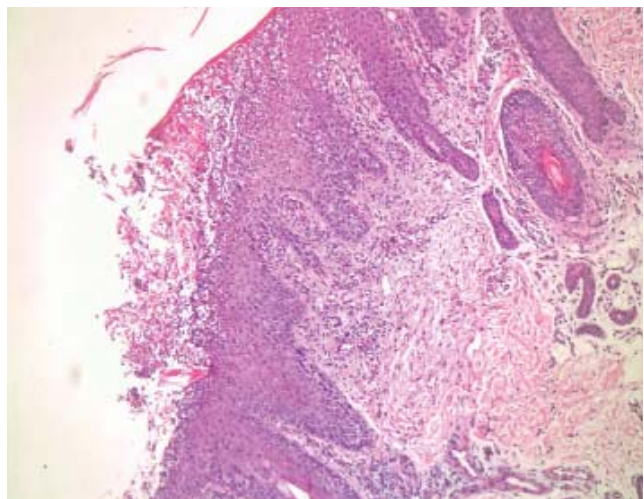


FIGURE 3: Subcorneal vesicle keeping fibrino-leukocytic exudate to be observed

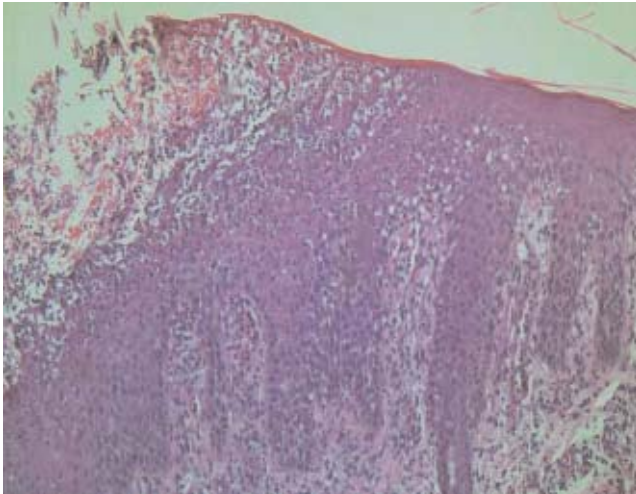


FIGURE 4: Acanthosis, hyperkeratosis and areas of parakeratosis, dermal mononuclear infiltrate with groups of neutrophils (HE; 200X)

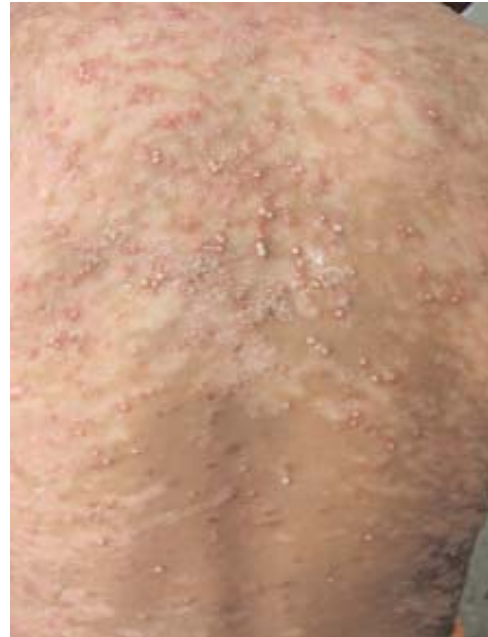

FIGURE 6: Residual hypochromic lesions with scattered pustules

DISCUSSION

Generalized pustulous psoriasis (GPP) is rare in children. It can occur in infancy, at any age, but it is more common in the first year of life.⁴ Different from psoriasis in adult GPP, in children, it has a higher prevalence in the male sex in a proportion of 3:2.⁵ Epidemiological and immunogenetic data have shown hereditary predisposition for psoriasis. Participation of HLA genes has been studied being greater the co-relation found with the HLA-Cw6.⁶

As for this report the patient presented family history of similar lesions, which reinforces the important role of heredity in psoriasis.⁴ Possible differential diagnoses include staphylococcal scalded skin syndrome, Reter's syndrome, generalized candidiasis, atopic dermatitis, seborrheic dermatitis, pustular mil-

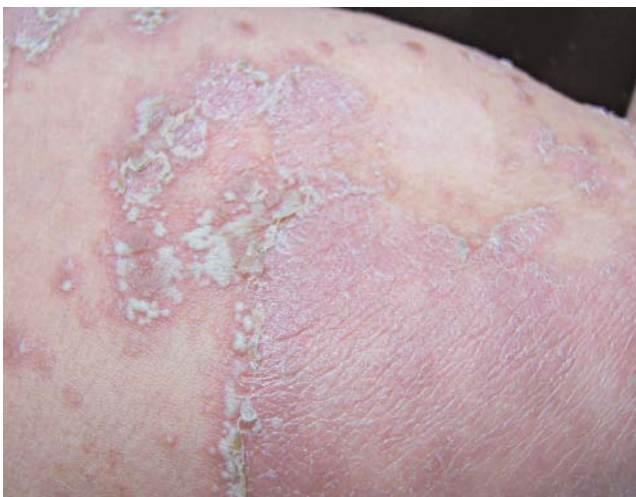

FIGURE 5: Erythematous plaques still with bordered pustules, after 3 months of treatment

aria and acute generalized exanthematous pustulosis.^{3,7} Clinical data presented associated with typical PPG histopathology confirmed the diagnosis. The von zumbusch type is an acute form that presents itself by sudden eruption of sterile papules on erythematous basis accompanied by severe systemic symptoms such as fever and pain and, sometimes, endangering the patient's life.⁸ In the reported case the patient presented fever and adynamia as signs of gravity pointing to the immediate need to initiate systemic therapy.

Perhaps due to the rarity of the disease a safe and consistently effective treatment for the disease has not been identified yet. The therapeutic options already published include systemic retinoids, cyclosporine A, PUVA, UVBnB, methotrexate and dapsone, apart from topic treatments.⁹⁻¹³ Another recent option are the so called biologic such as infliximab and etanercept still incipiently used in children with GPP.¹⁴ As for the case reported here the option was dapsone as it is a relatively safe drug and also due to the large experience of the service with this drug used in many other illnesses. Response to this treatment was partial following the first trimester of treatment. It was programmed the use of cyclosporine for the next consultation in case there was not effective control of the disease. GPP in children tends to have a more benign development than it has in adult patients. However, the disease in its more severe form can endanger the patient's life.³ Immediate introduction of systemic therapeutics is needed. In this study it was reported the experience of the use of dapsone that can be considered a moderately effective drug for the treatment of such illness. □

REFERENCES

1. Khan SA, Peterkin GA, Mitchell PC. Juvenile generalized pustular psoriasis. A report of five cases and a review of the literature. *Arch Dermatol.* 1972;105:67-72.
2. Baker H, Ryan TJ. Generalized pustular psoriasis. A clinical and epidemiological study of 104 cases. *Br J Dermatol.* 1968;80:771-93.
3. Cassandra M, Conte E, Cortez B. Childhood pustular psoriasis elicited by the streptococcal antigen: a case report and review of the literature. *Pediatr Dermatol.* 2003;20:506-10
4. Beylot C, Puissant A, Bioulac P, Saurat JH, Pringuet R, Doutre MS. Particular clinical features of psoriasis in infants and children. *Acta Derm Venereol.* 1979;87:95-7.
5. Karamfilov T, Wollina U. Juvenile generalized pustular psoriasis. *Acta Derm Venereol.* 1998;78:220.
6. Elder JT, Nair RP, Guo SW, Henseler T, Christopher E, Voorhees JJ. The genetics of psoriasis. *Arch Dermatol.* 1994;130:216-24.
7. Zelickson BD, Muller SA. Generalized pustular psoriasis in childhood. Report of thirteen cases. *J Am Acad Dermatol.* 1991;24:186-94.
8. Pouessel G, Ythier H, Carpentier O, Vachée A, Etienne J, Catteau B. Childhood pustular psoriasis associated with panton-valentine leukocidin-producing *Staphylococcus aureus*. *Pediatr Dermatol.* 2007;24:401-4.
9. Baker H. Generalized pustular psoriasis. In: Roenigk HH Jr, Maibach HI, eds. *Psoriasis*. New York: Marcel Dekker; 1991. p.35-45.
10. Yu HJ, Park JW, Park JM, Hwang DK, Park YW. A case of childhood generalized pustular psoriasis treated with dapson. *J Dermatol.* 2001;28:316-9.
11. Dogra S, Kumaran MS, Handa S, Kanwar AJ. Methotrexate for generalized pustular psoriasis in a 2-year-old child. *Pediatr Dermatol.* 2005;22:85-6.
12. Ergin S, Ersoy-Evans S, Sahin S, Ozkaya O. Acitretin is a safe treatment option for infantile pustular psoriasis. *J Dermatolog Treat.* 2008;19:341-3.
13. Al-Shobaili H, Al-Khenaizan S. Childhood generalized pustular psoriasis: successful treatment with isotretinoin. *Pediatr Dermatol.* 2007;24:563-4.
14. Pereira TM, Vieira AP, Fernandes JC, Antunes H, Basto AS. Anti-TNF-alpha therapy in childhood pustular psoriasis. *Dermatology.* 2006;213:350-2.

MAILING ADDRESS / ENDEREÇO PARA CORRESPONDÊNCIA:

*Maria de Fátima Santos Paim de Oliveira
Rua Reitor Macedo Costa 113 apartamento 1401-A,
41815 150 Itaigara, Salvador – BA, Brazil
e-mail: mfatimapaim@gmail.com*

How to cite this article/*Como citar este artigo*: Chaves YN, Cardoso DN, Landulfo Jorge PF, Follador I, de Oliveira M de FP. Childhood Pustular Psoriasis – A Case Report. *An Bras Dermatol.* 2010;85(6):899-902.